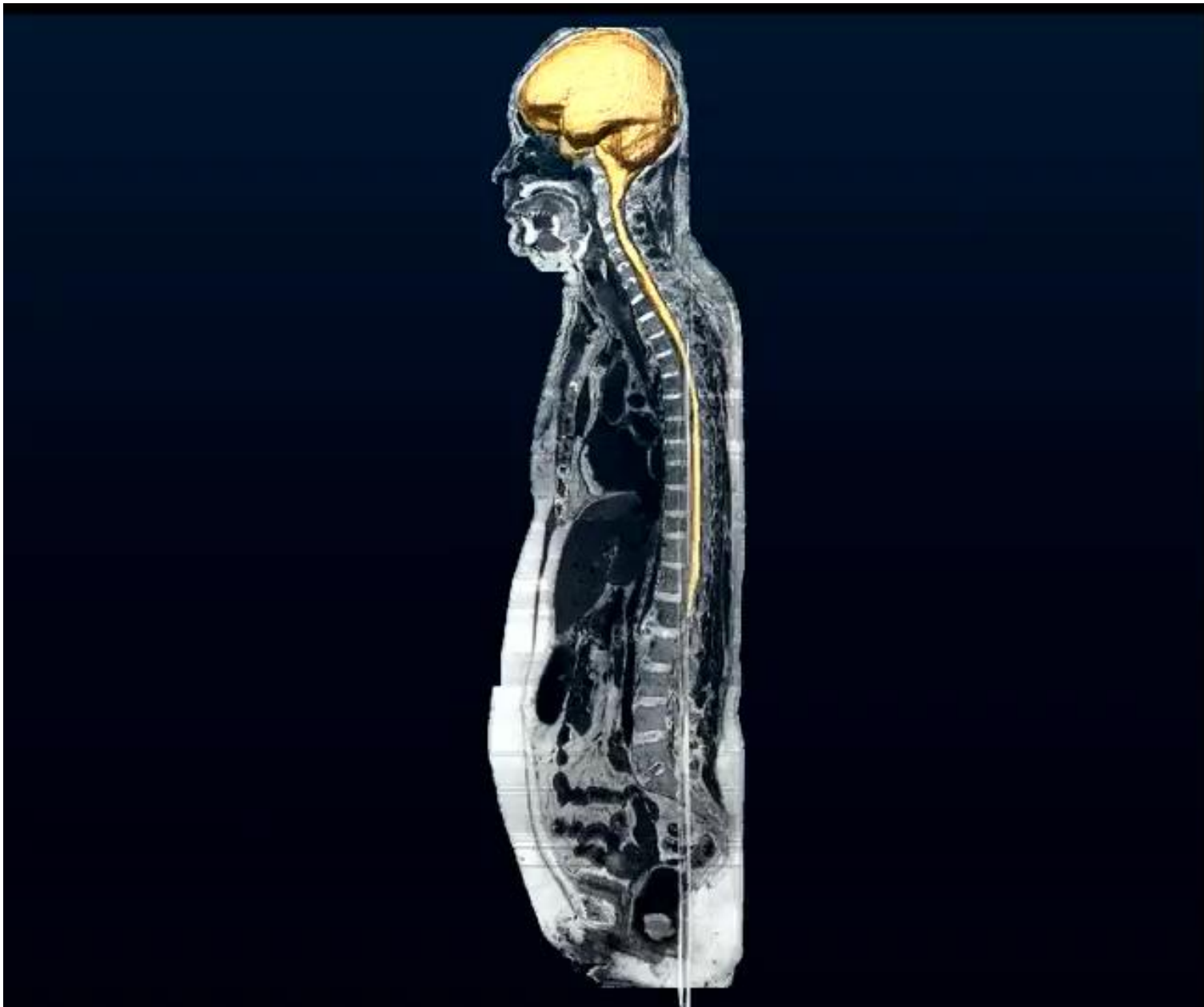



---

# Basic Neuroanatomy In Clinical Practice

*Dr. dr. Rahadian Indarto Susilo, Sp.BS (K)*



# Sesi 1

# Review singkat (banget) NEUROANATOMI

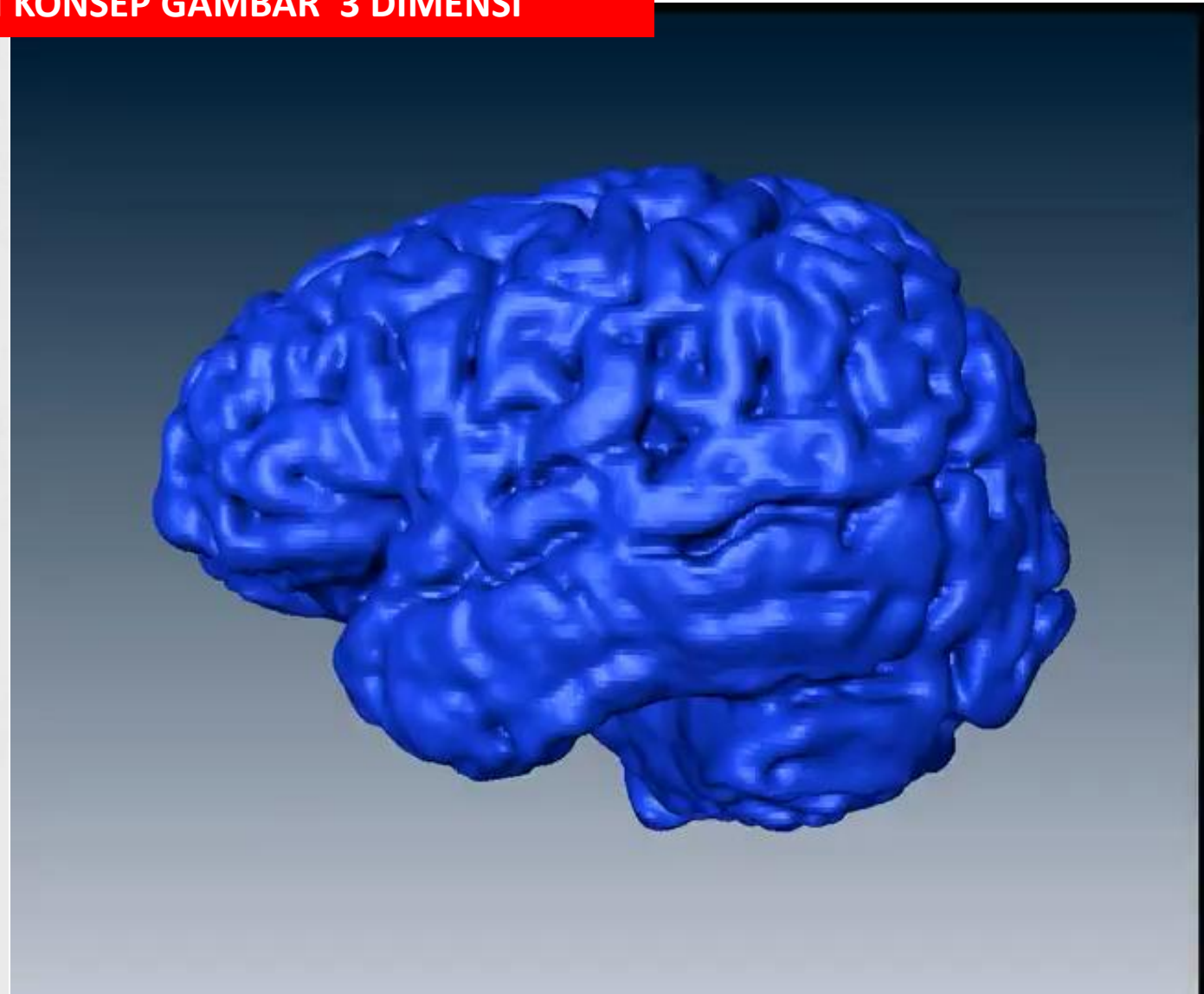
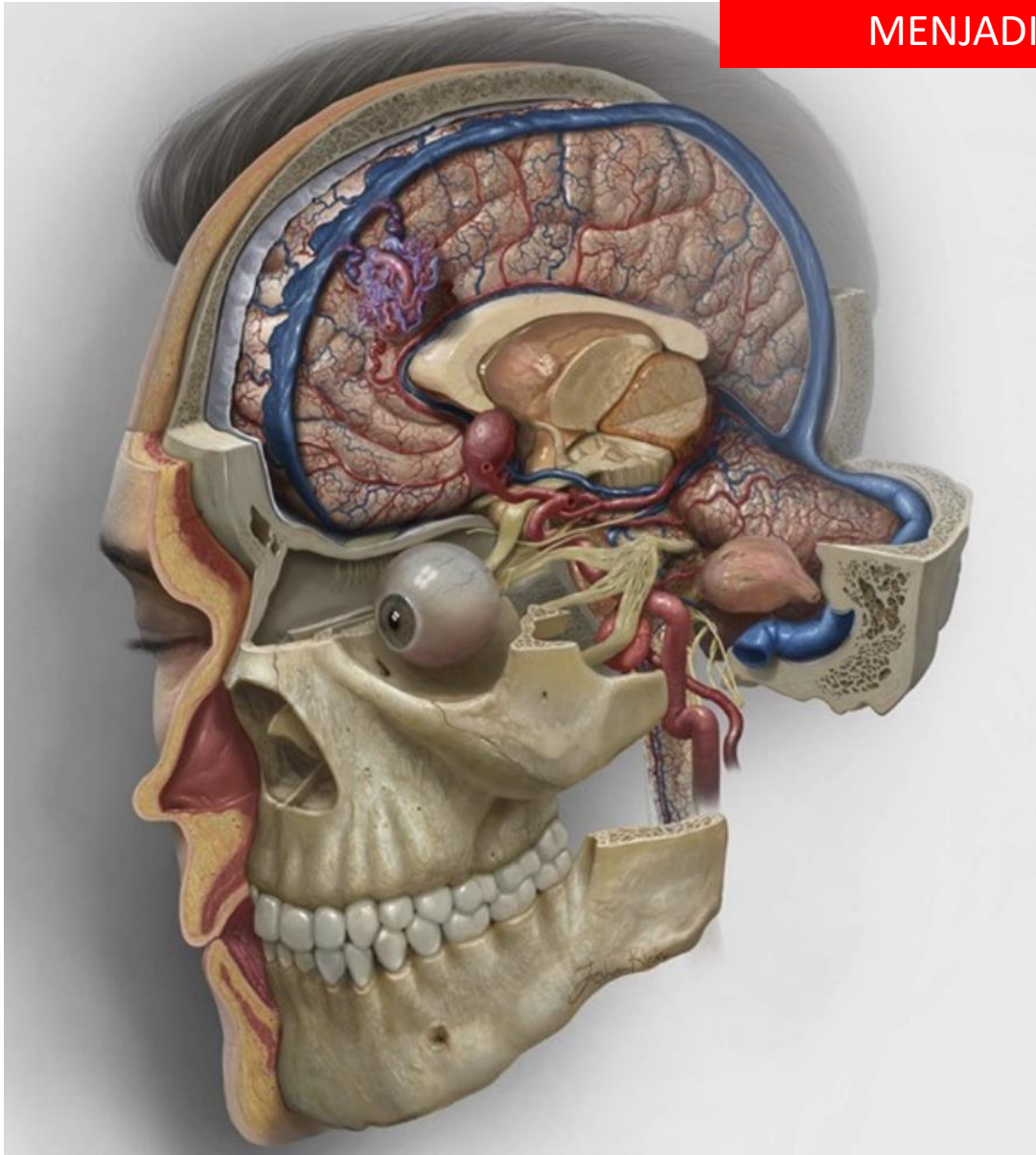
Sesi 1

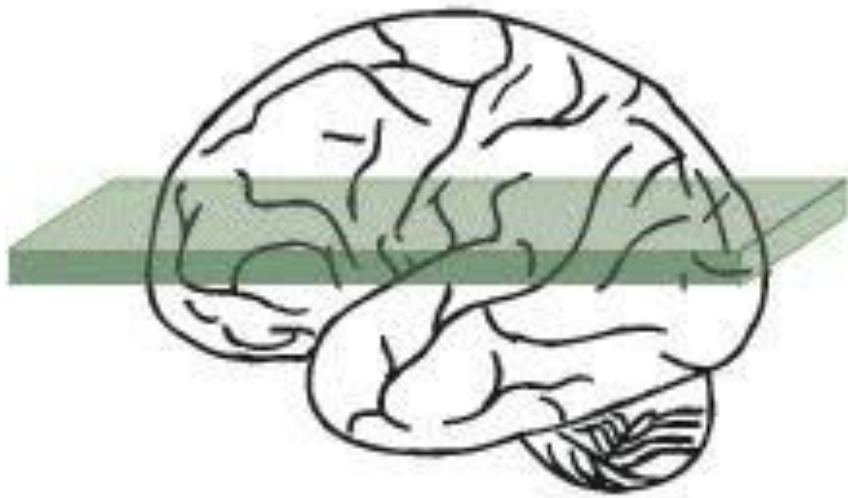# Outline

1. Konsep 3D dalam memahami Neuroanatomi
2. Embriology
3. Supratentorial
4. Infratentorial
5. Sistem Arteri dan Vena
6. Aliran CSF dan Sistem Ventrikel

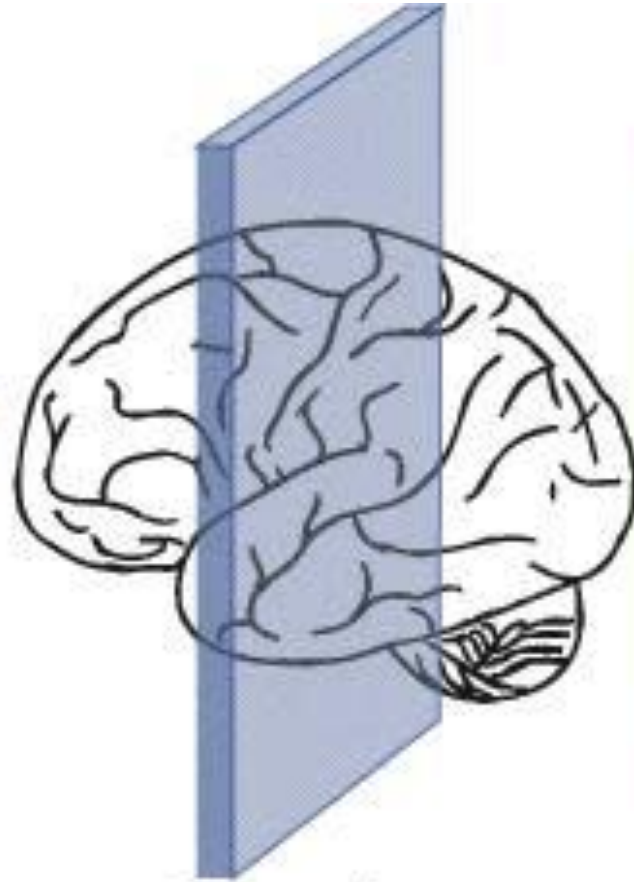
# 1. Konsep 3D dalam memahami Neuroanatomi

MENGAPLIKASIKAN PENGETAHUAN NEUROANATOMI  
MENJADI KONSEP GAMBAR 3 DIMENSI

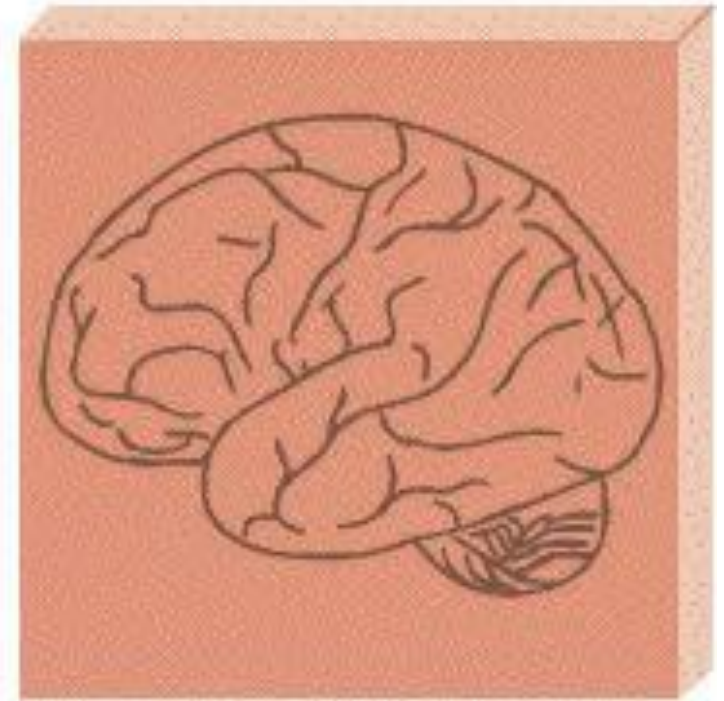



Axial



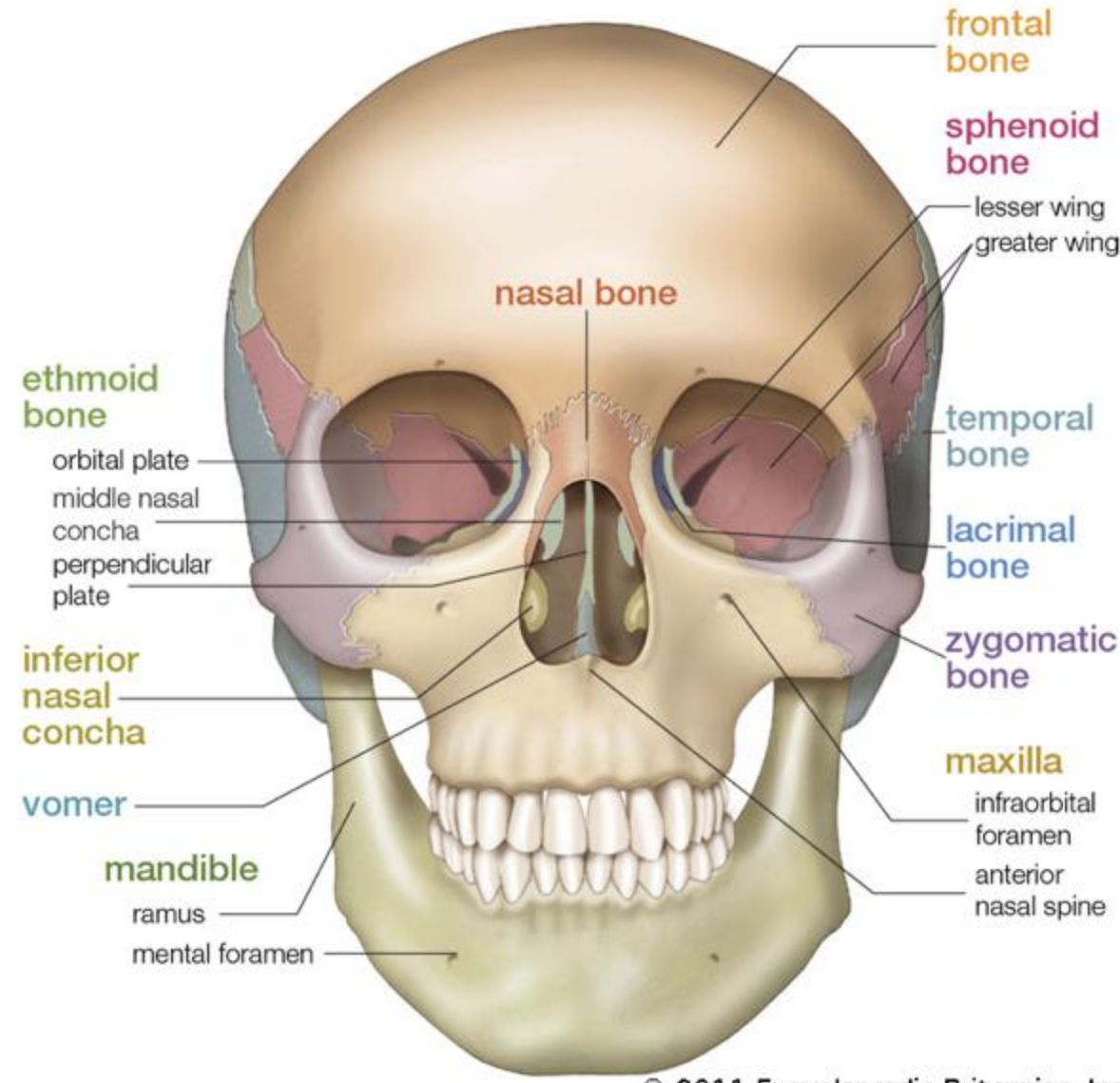
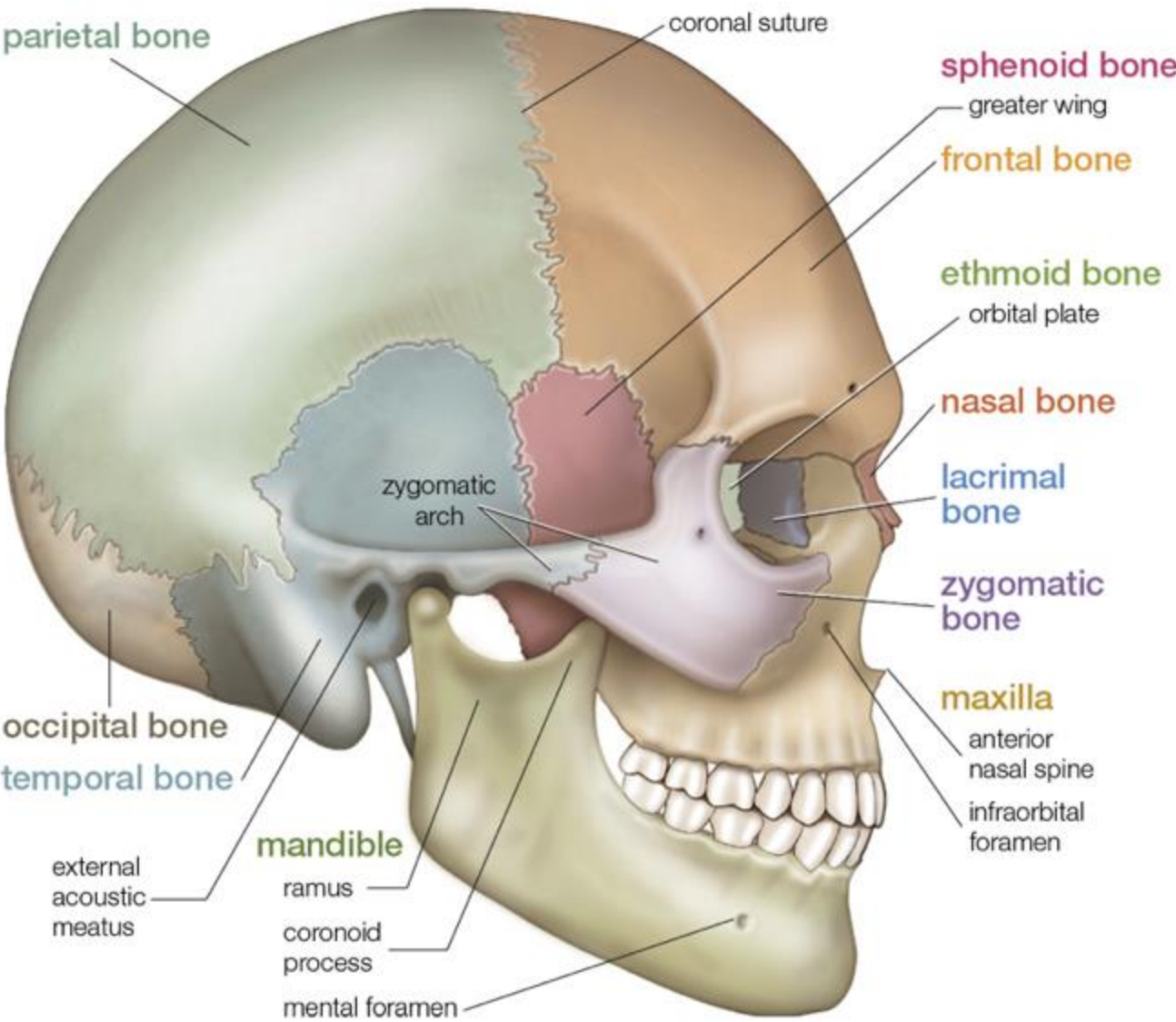
Coronal



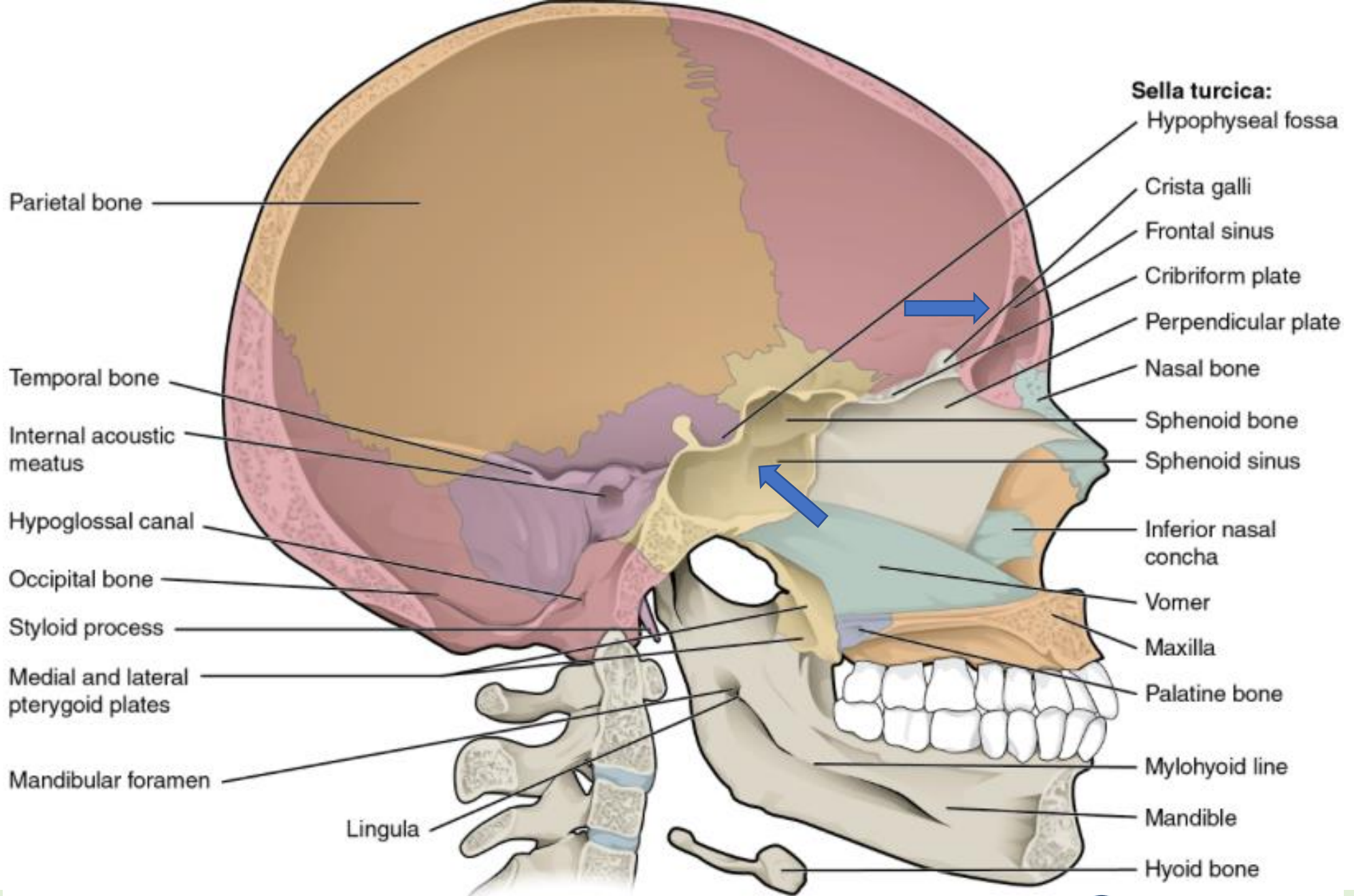
Sagittal

Lateral view

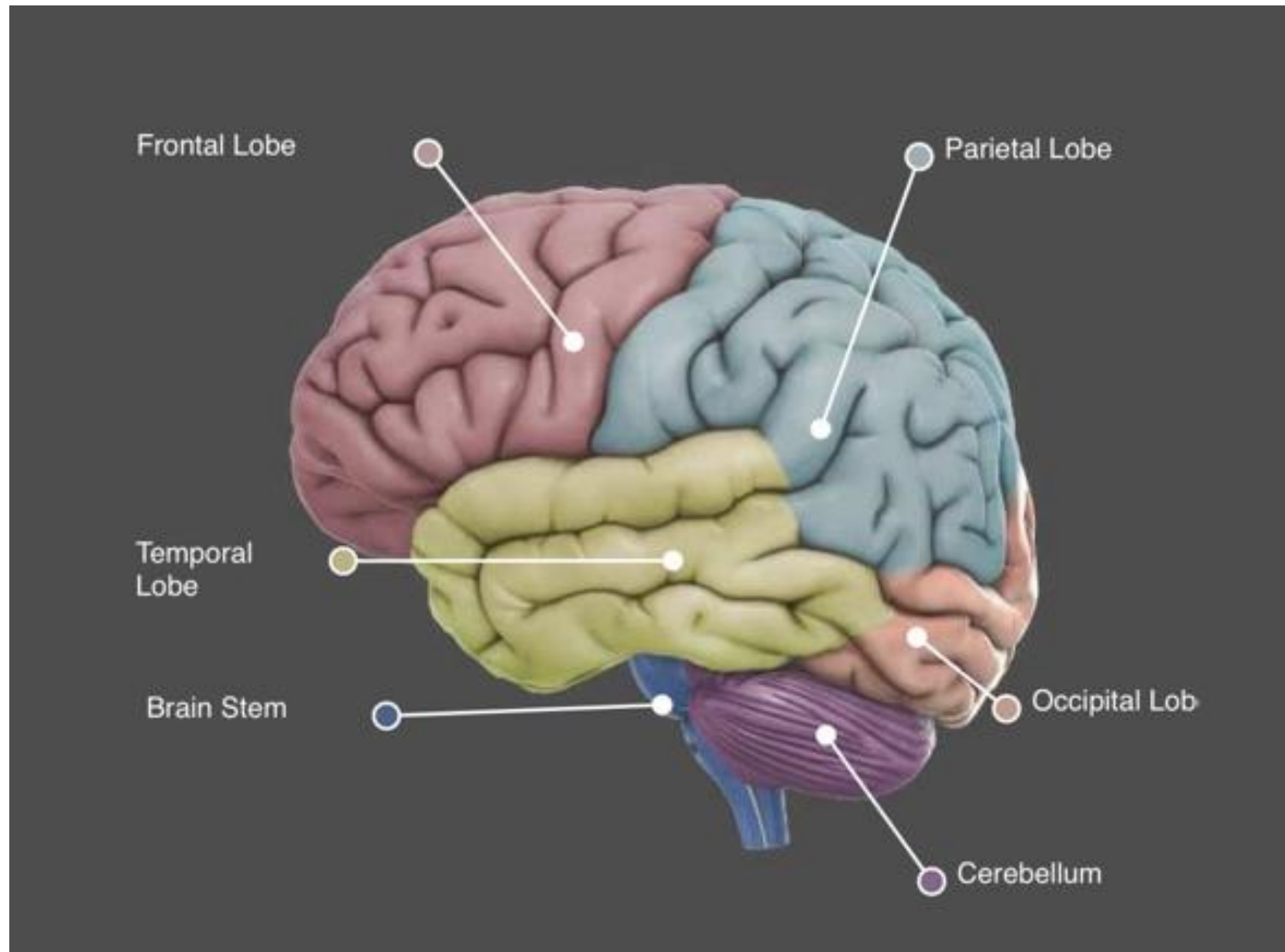
Frontal view



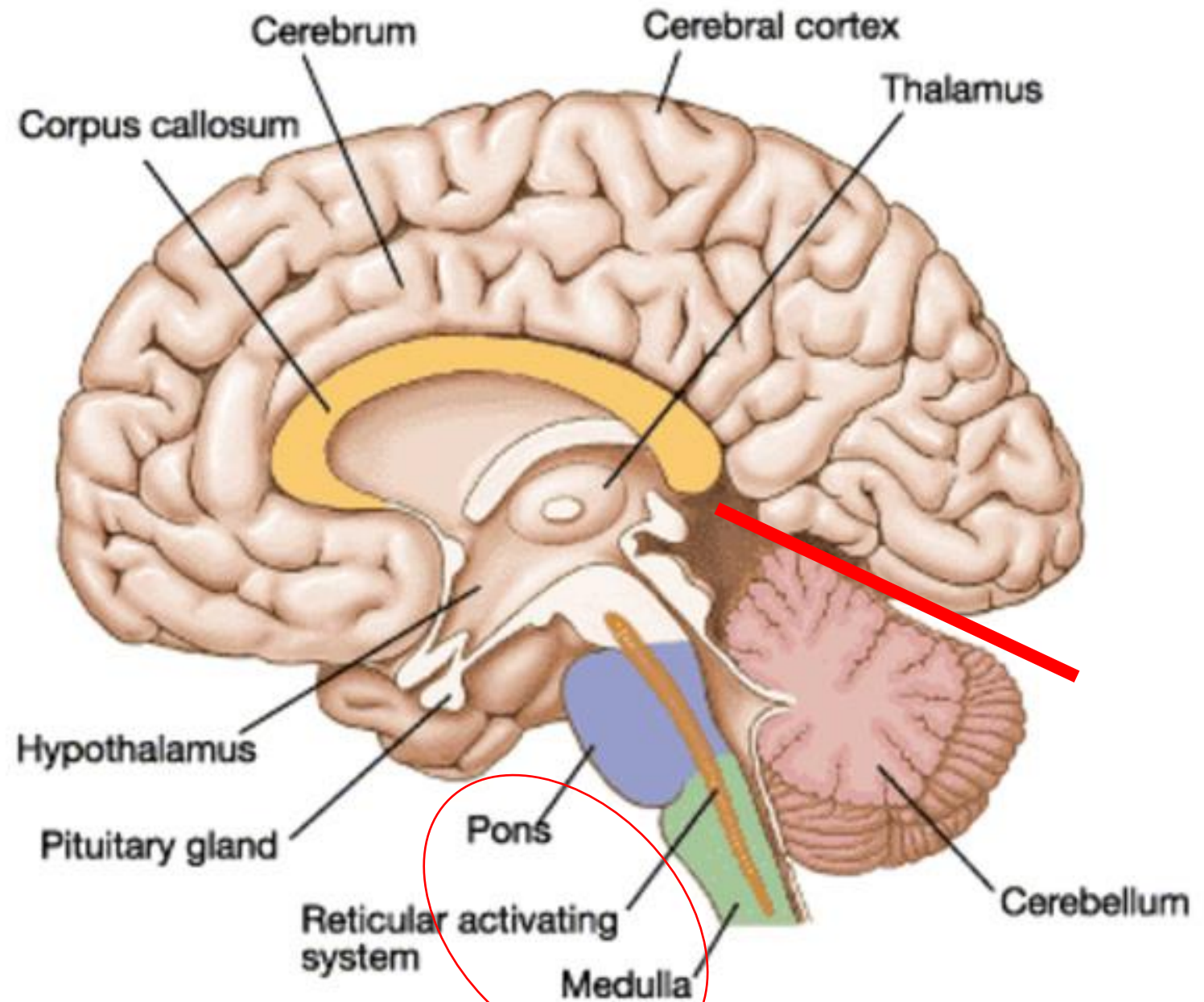
© 2011 Encyclopædia Britannica, Inc.



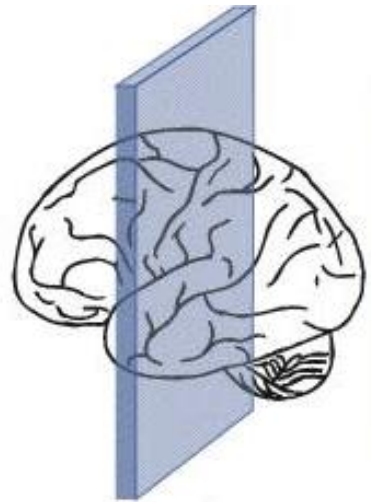
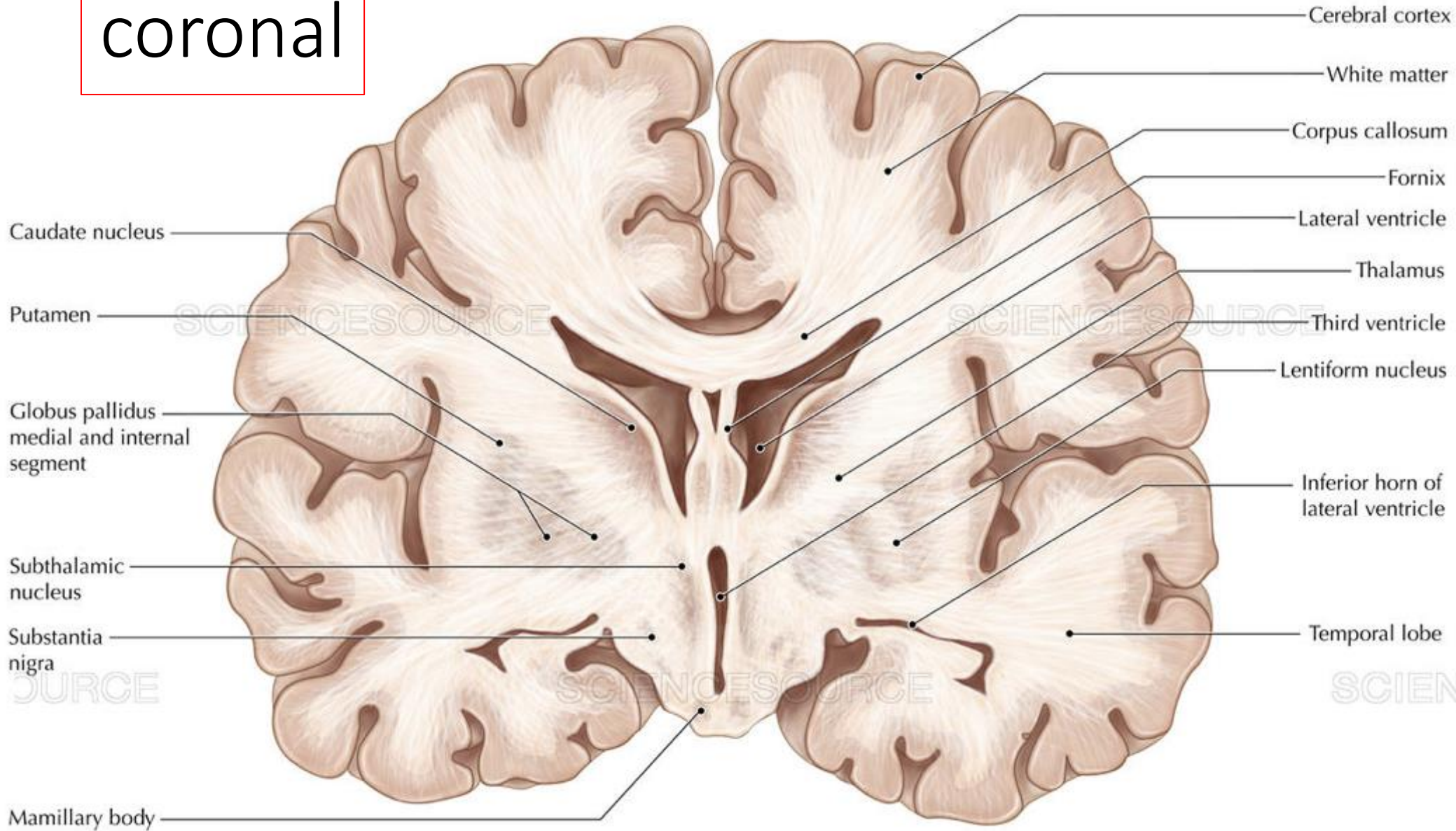
# sisi Lateral



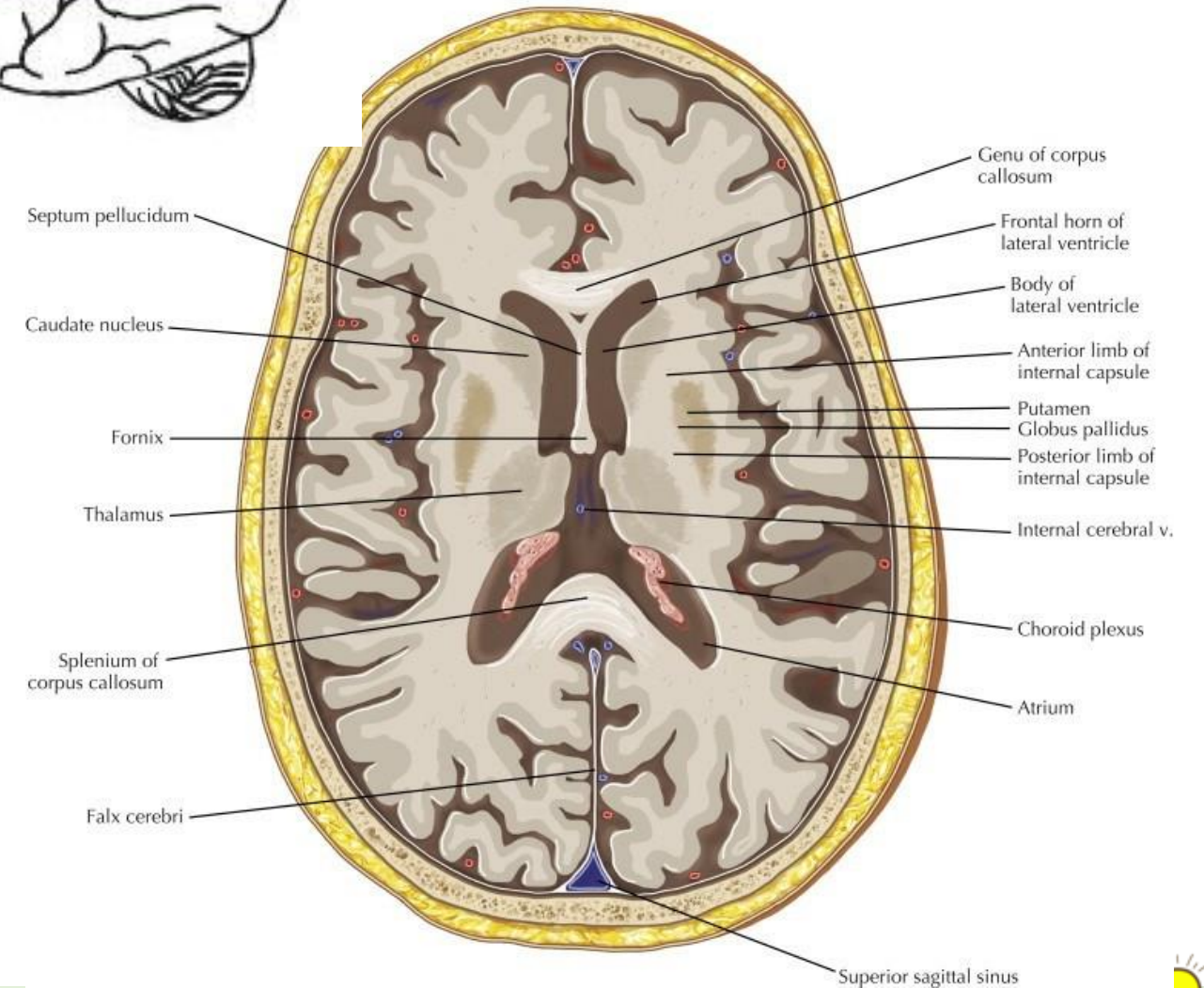
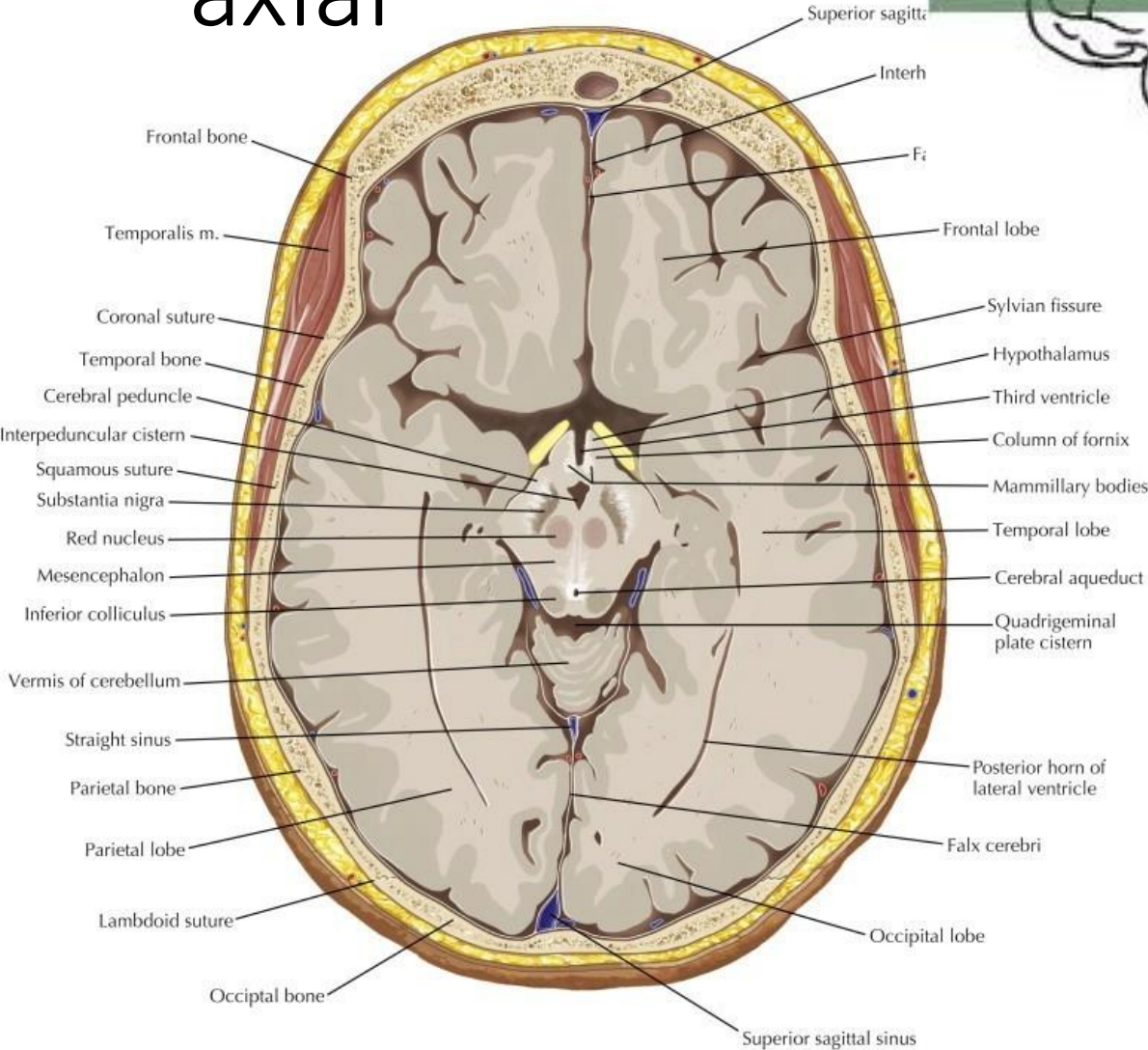
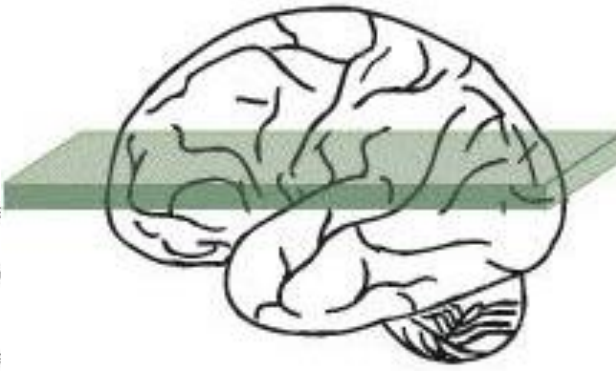sisi  
medial



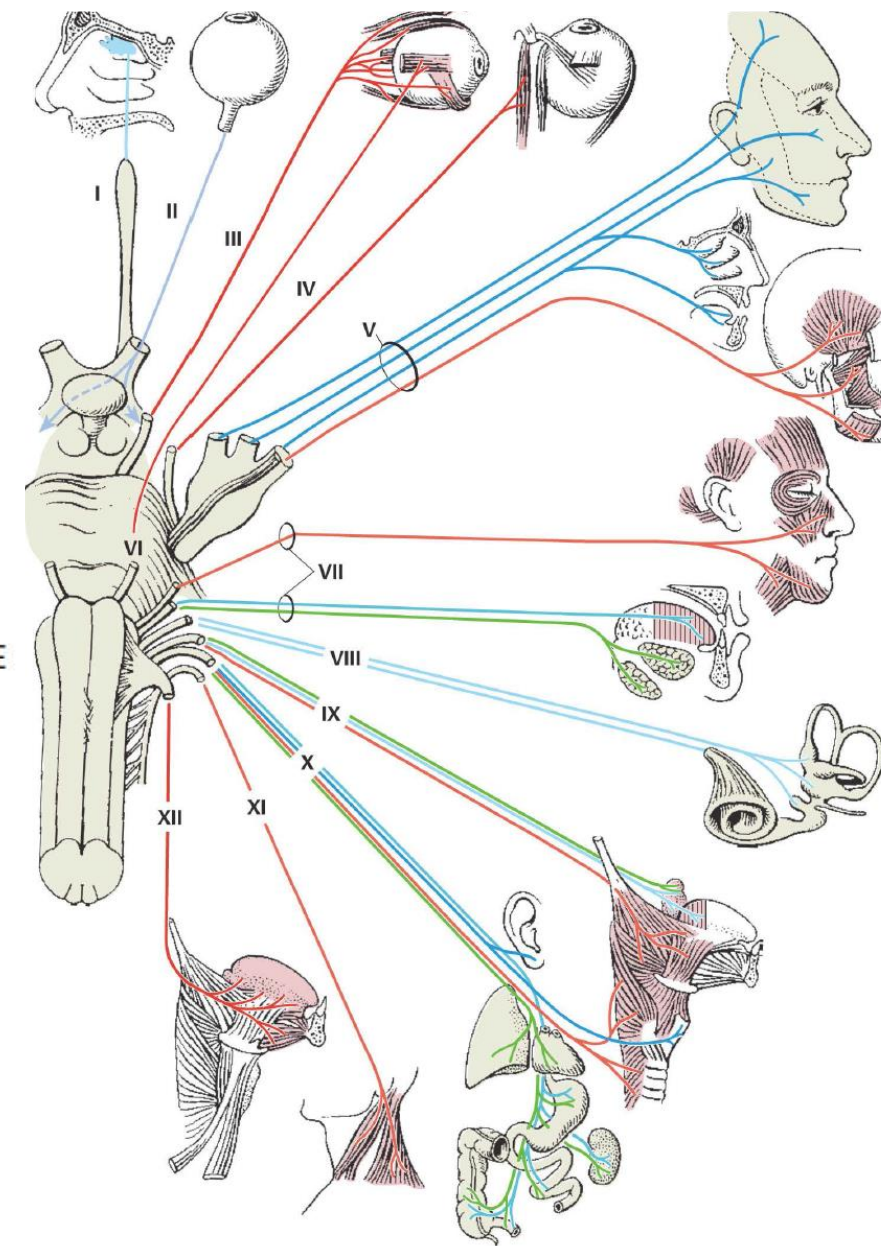
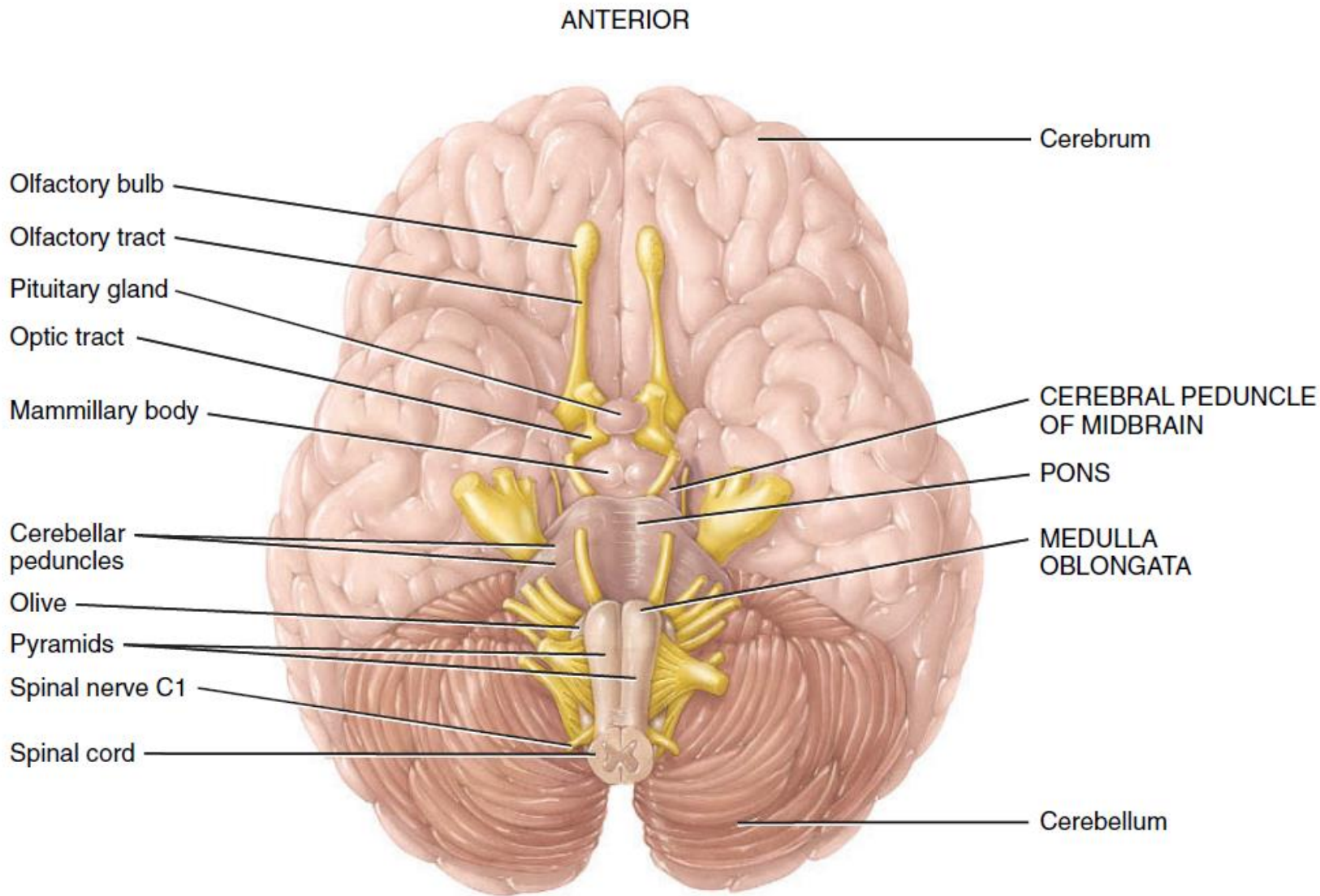
# coronal



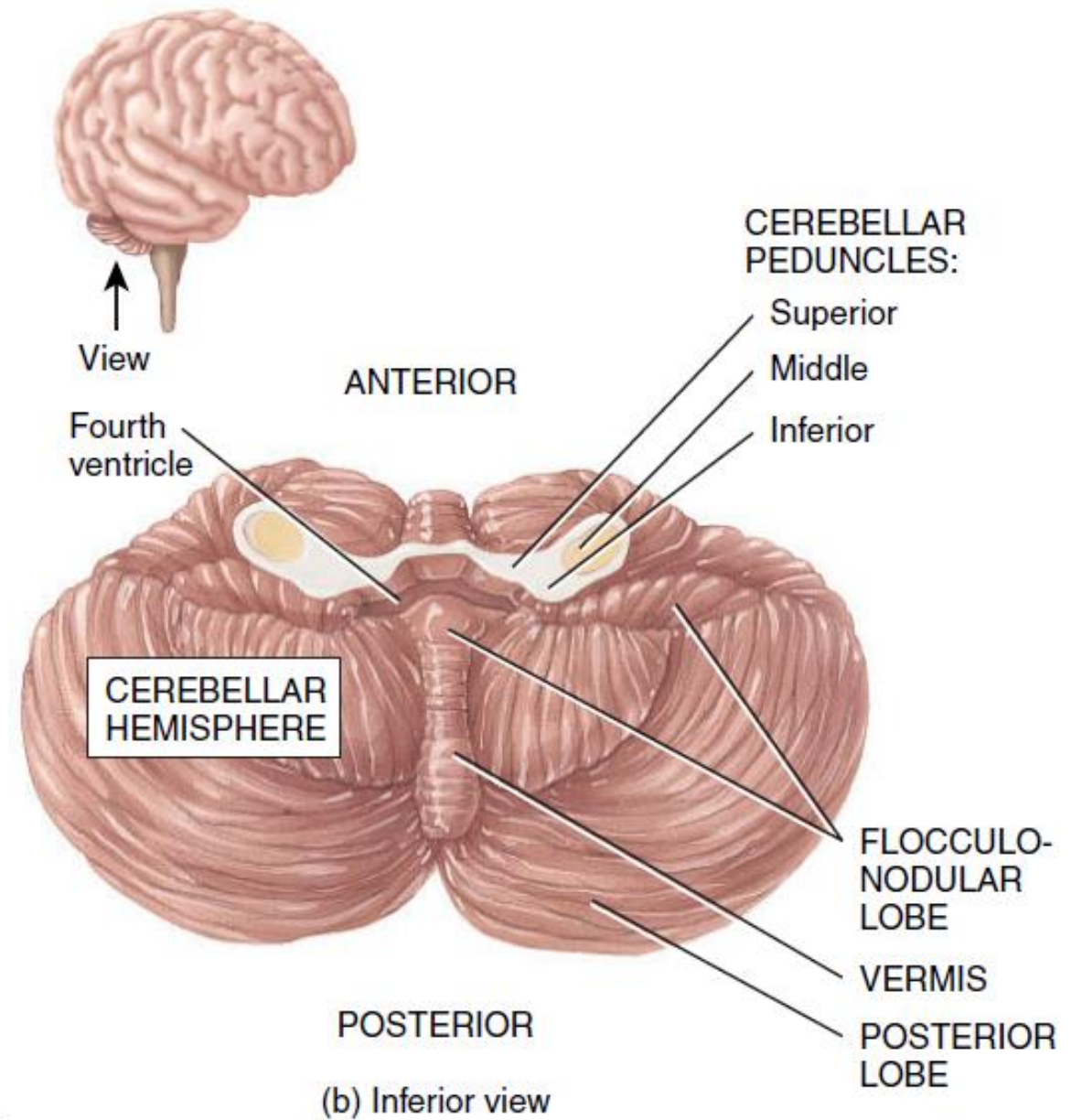
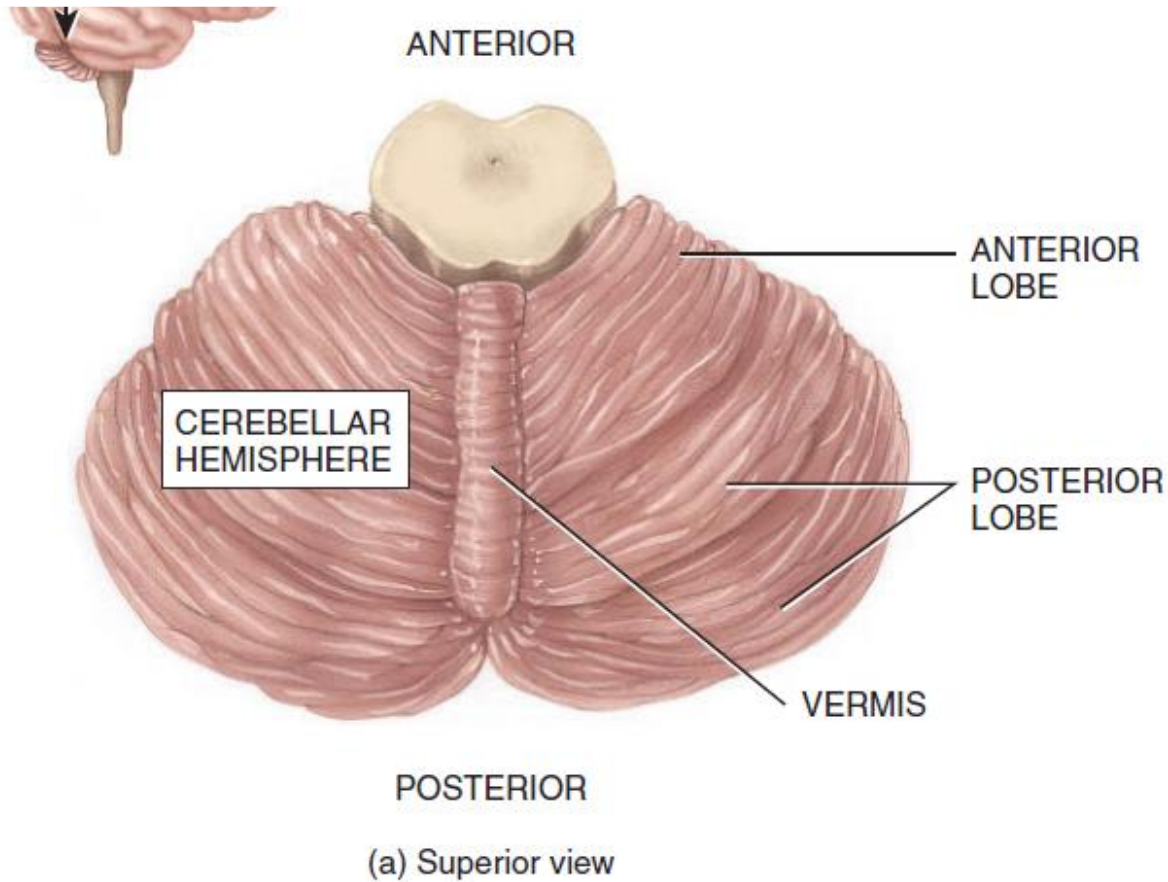
# axial



# Brainstem dan Nervus Kranialis



# Cerebellum



## 2. Embriologi

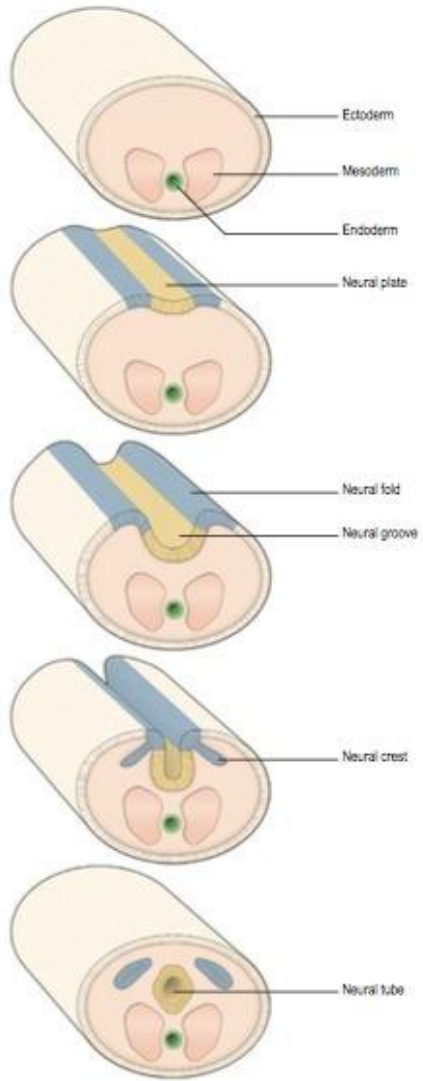
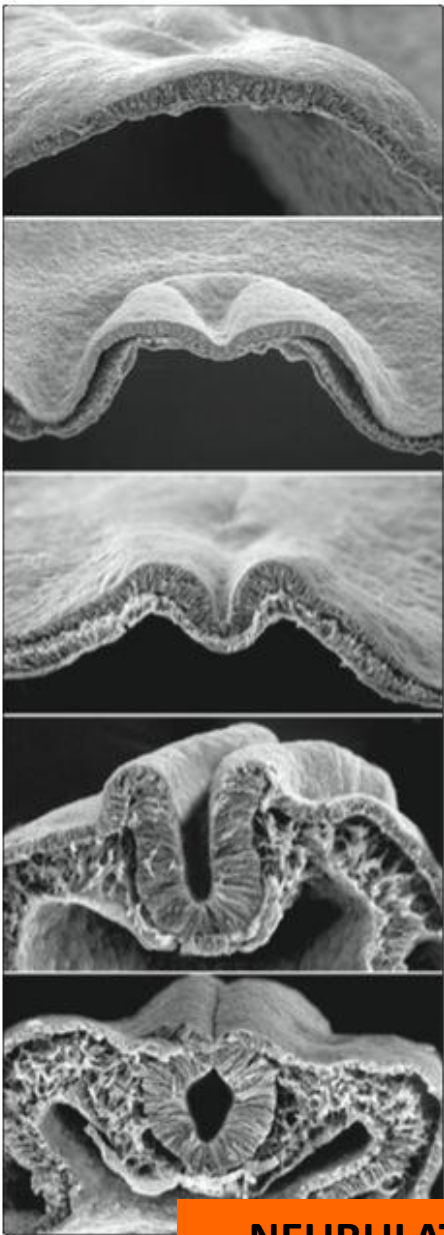
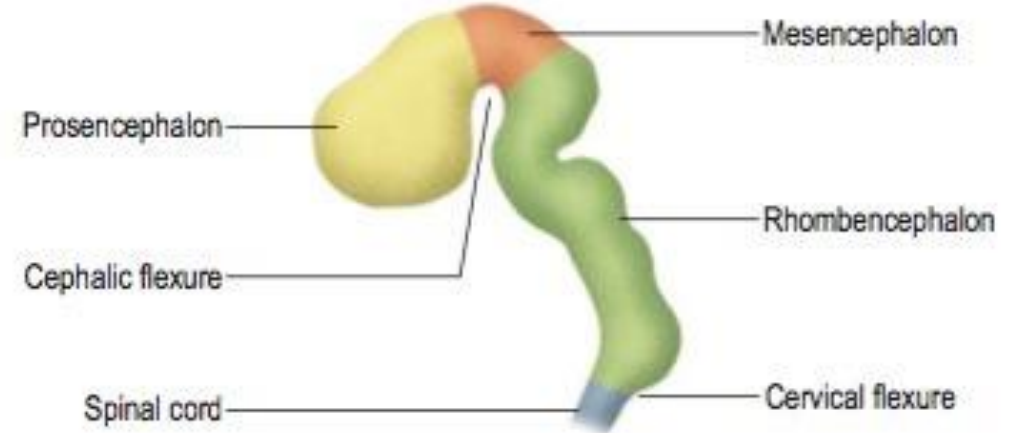


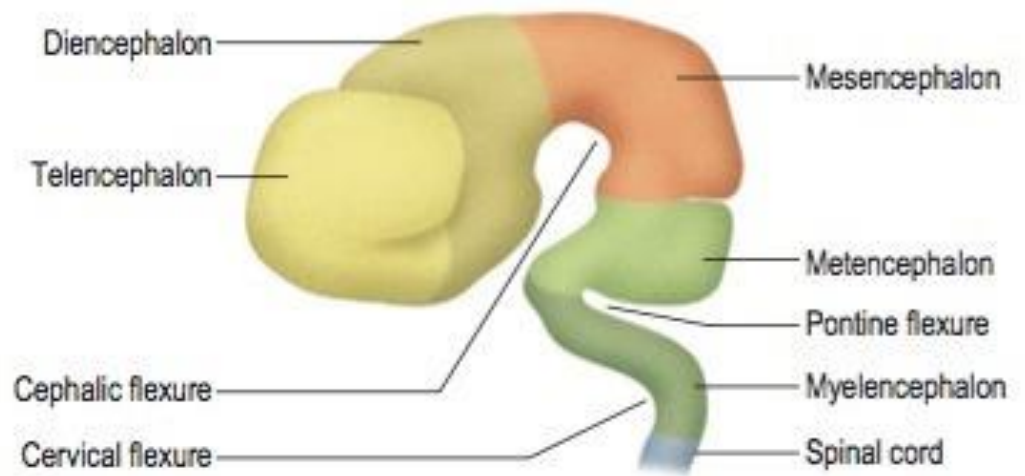
Figure 1.9 Schematic representation of the formation of the neural tube from the embryonic ectoderm.

Early week 2

Mid week 4



4-5 weeks



7-8 weeks

**NEURULATION**

# BRAIN VESICLE FORMATION

## + VESICLES "cephalon"

✓ The neural tube differentiates into brain vesicles ("-cephalon").

## ✓ BRAIN VESICLES

4 Weeks Primary      5 Weeks Secondary

3

5

Prosen- → Telen-  
          → Dien-

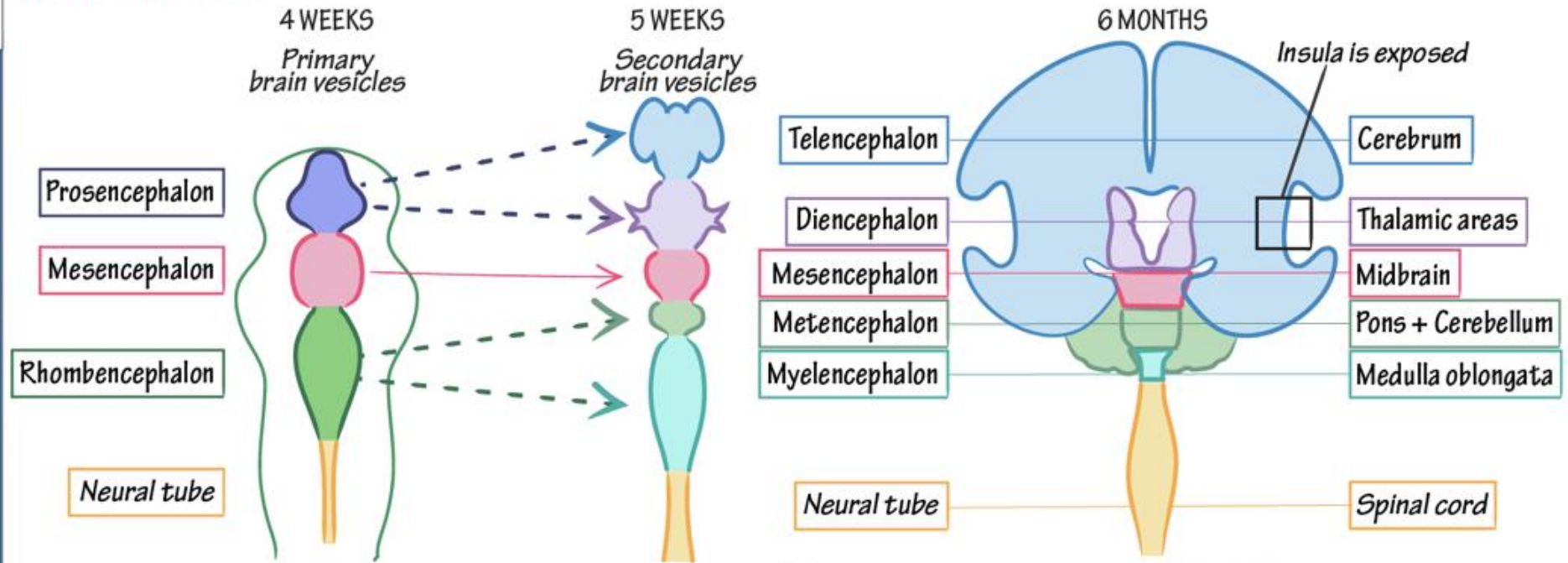
Mesen- → Mesen-

Rhomben- → Meten-  
              → Myelen-

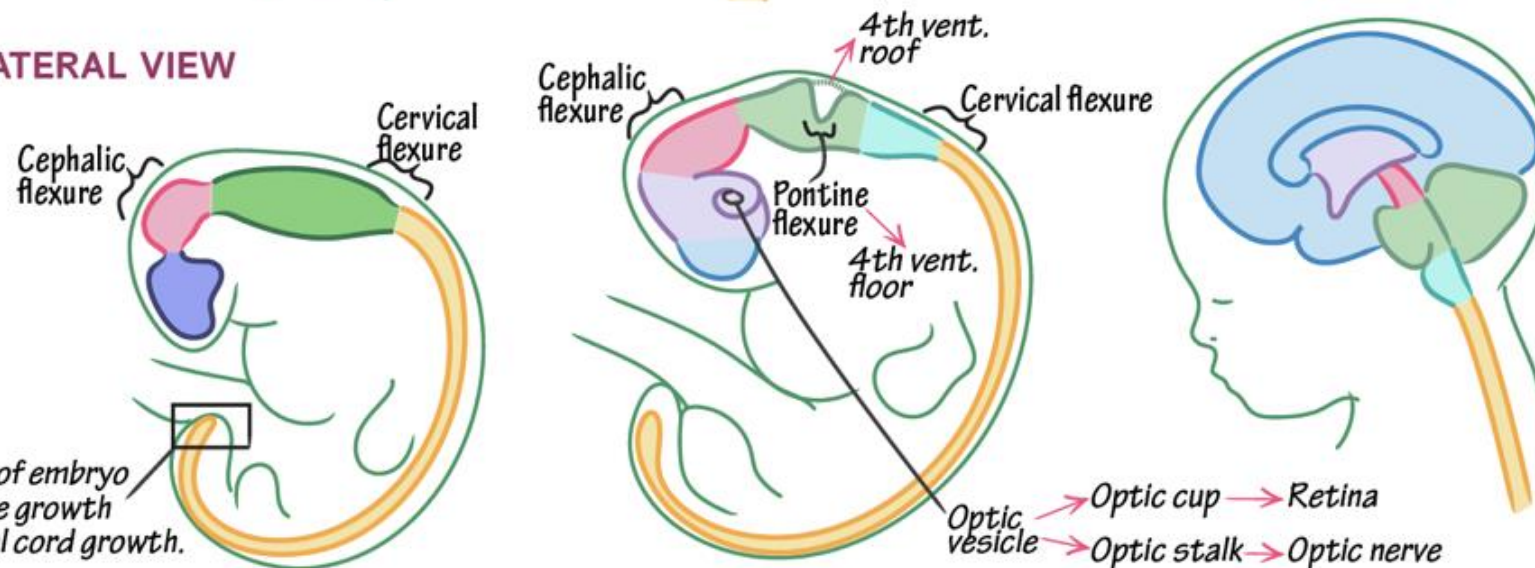
## ✓ FLEXURES (3)

- ✓ Cephalic
- ✓ Pontine
- ✓ Cervical

## CORONAL VIEW

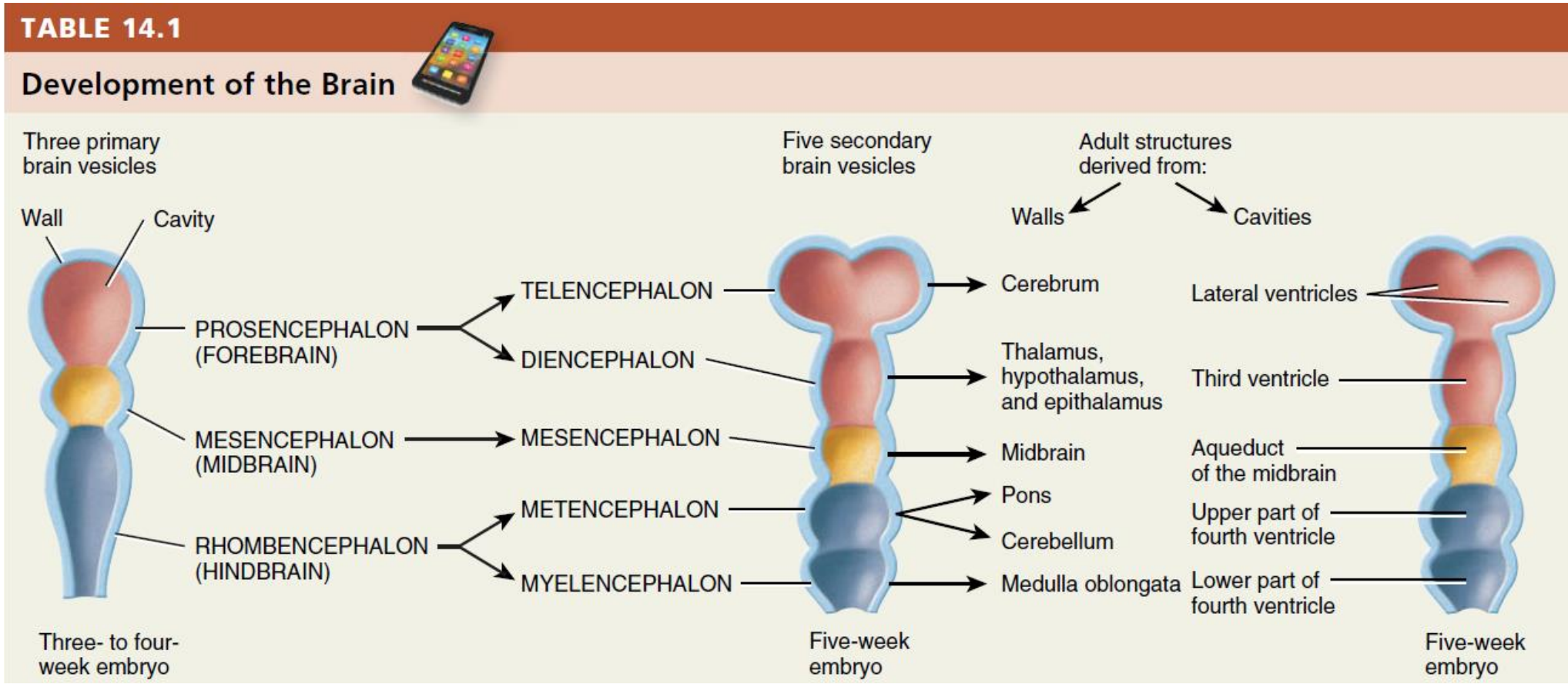


## LATERAL VIEW



Neural tube runs length of embryo until month 3 when spine growth starts to outpace spinal cord growth.

# Neuroembriologi Dasar Otak



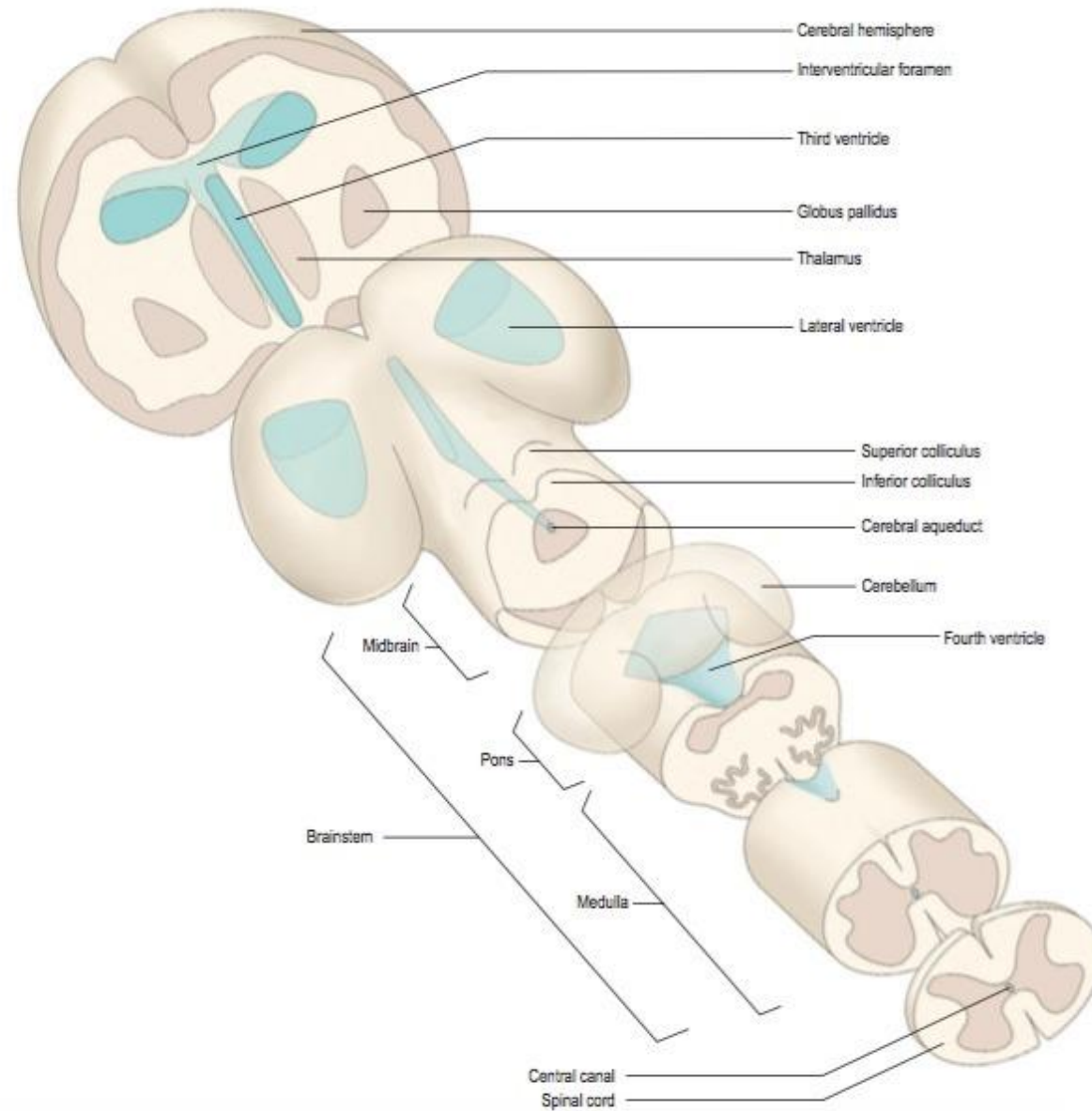
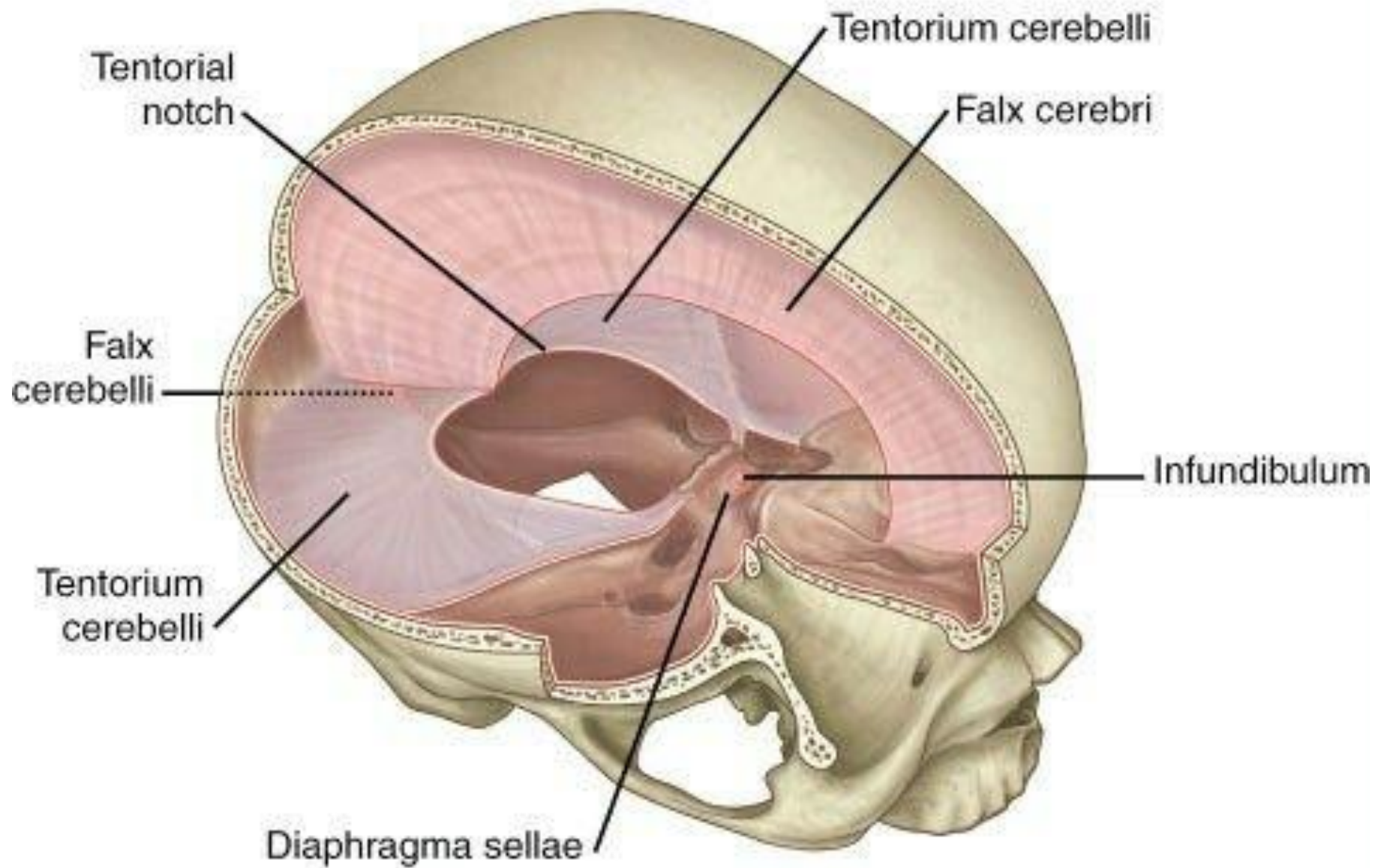
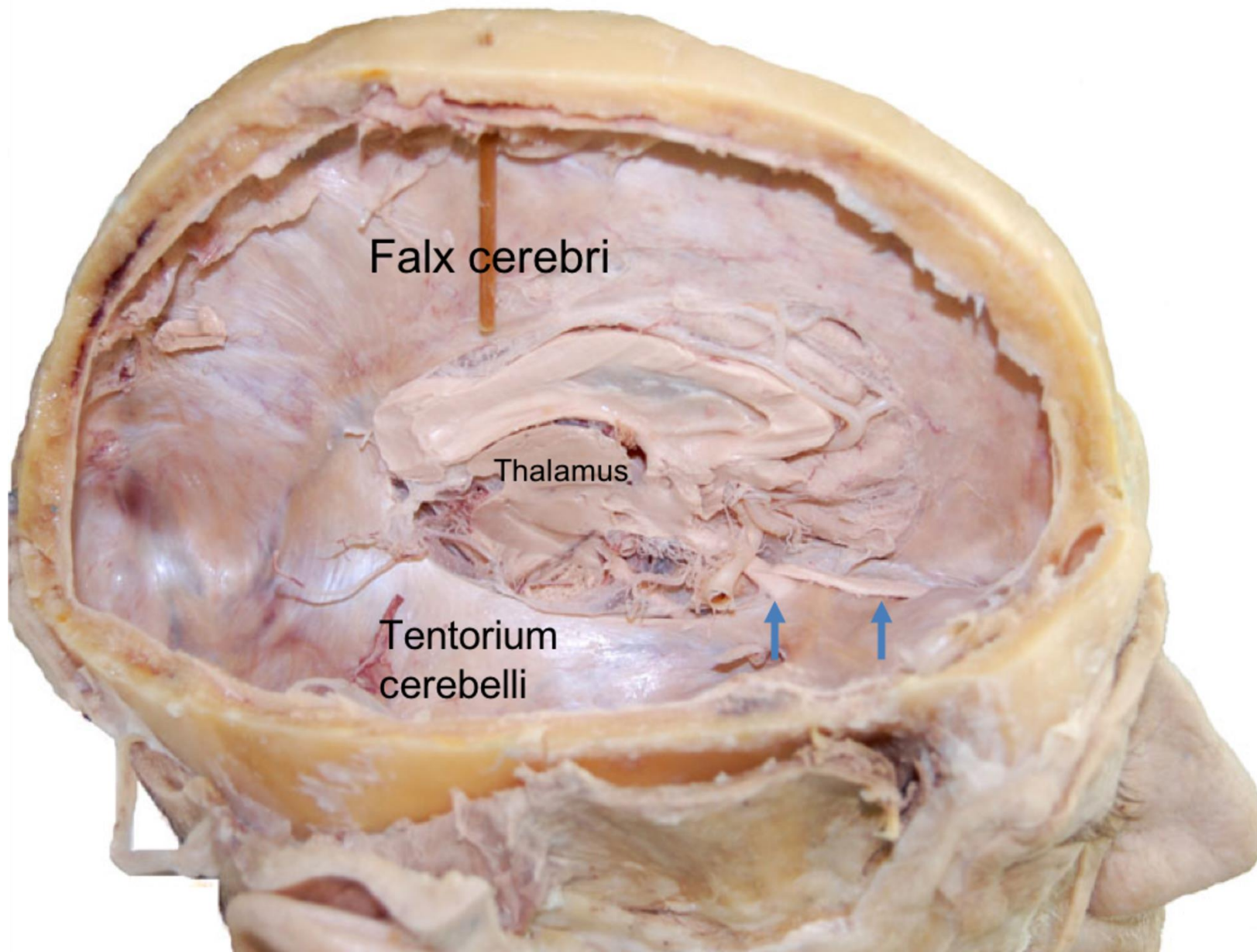


Figure 1.13 Schematic representation of the major subdivisions and landmarks of the brain.

# 3. Supratentorial & Infratentorial



**Tentorium cerebelli**  
*The tentorium cerebelli - an infolding of the dura mater - forms a tent-like sheet which separates the cerebrum (brain) from the cerebellum. The tentorium is anchored by the petrous bones.*



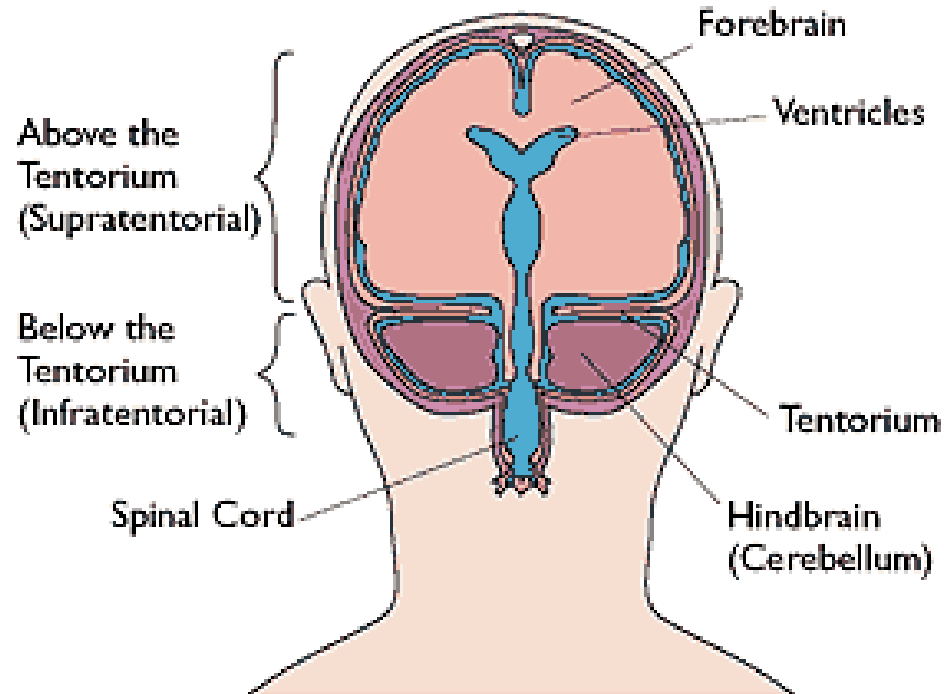
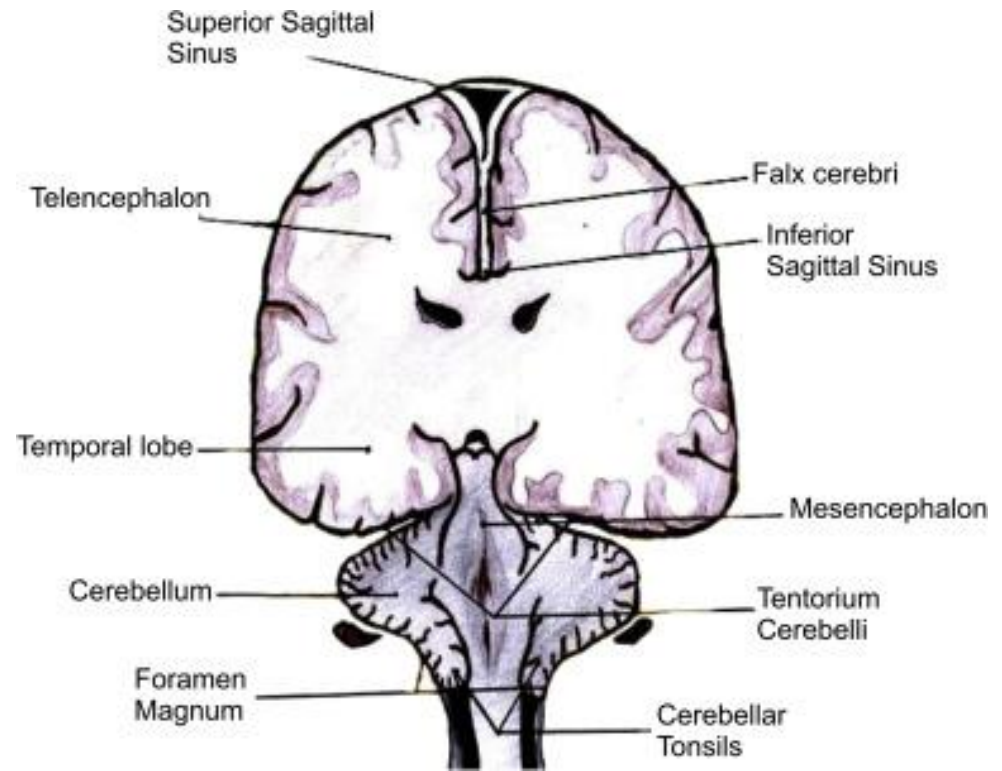
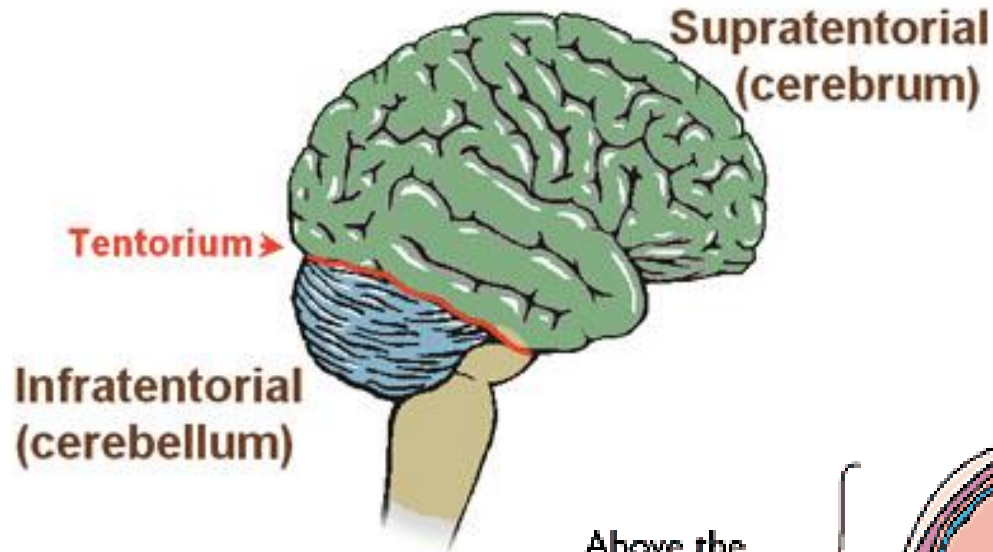
### **Tentorium cerebelli**

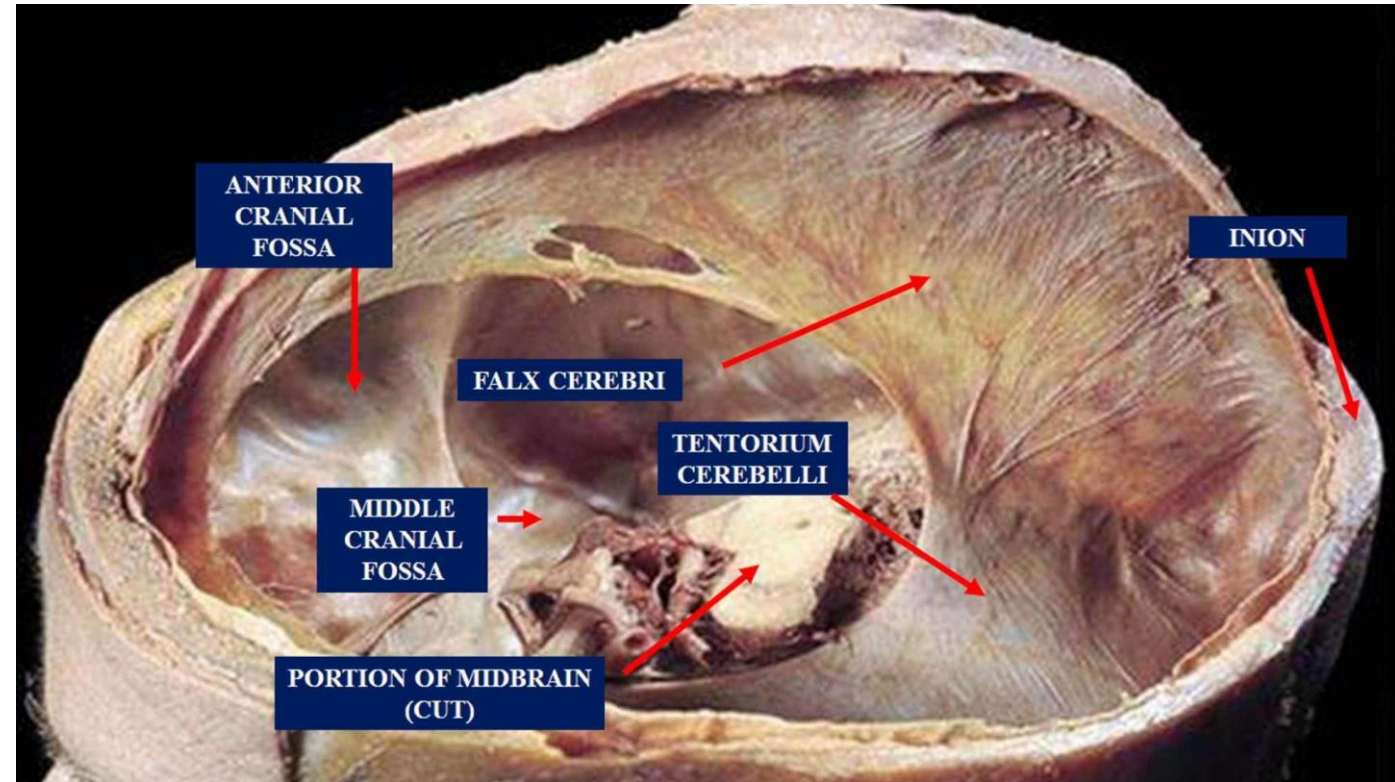
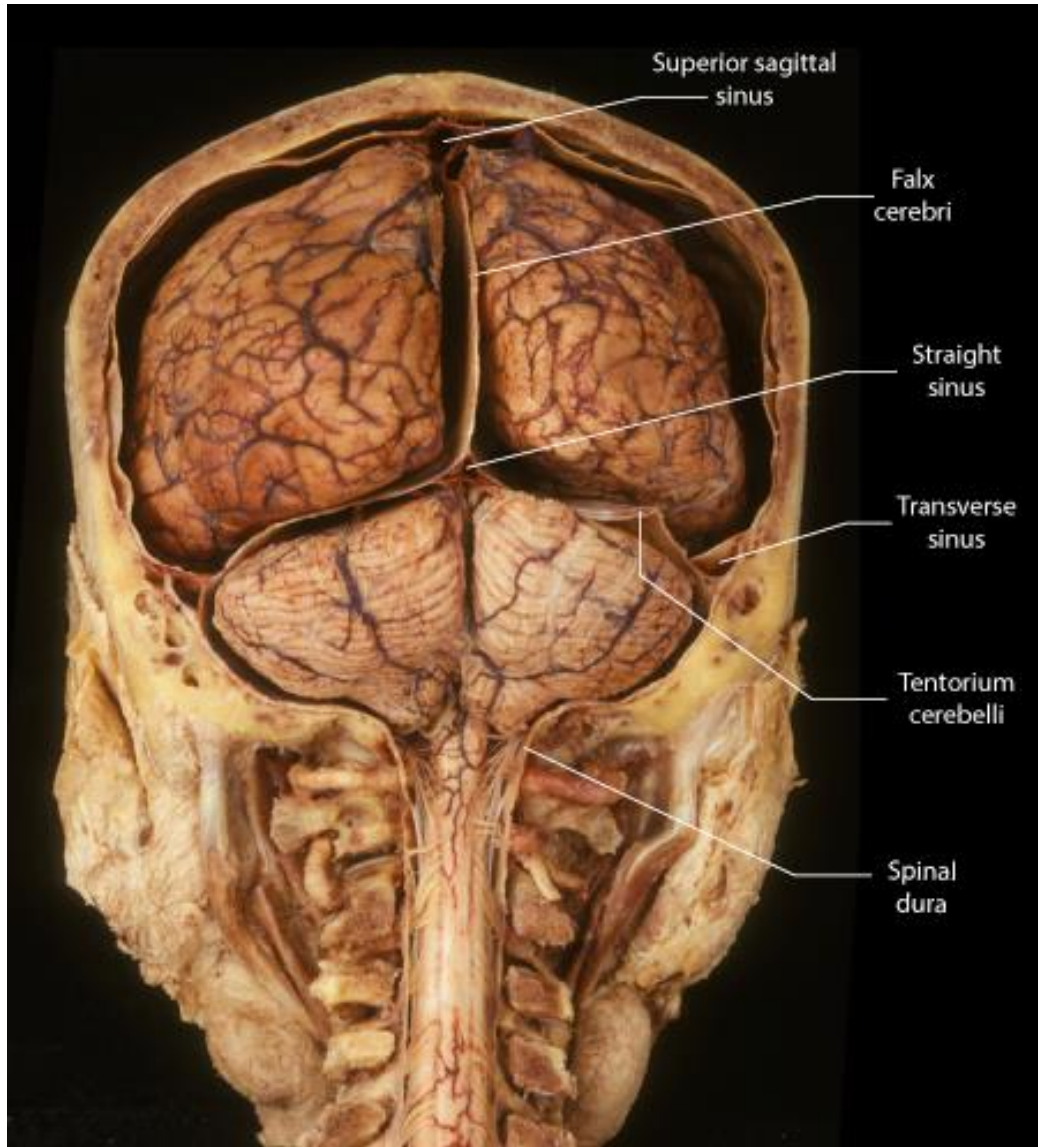
***On axial slice CT images of the brain the tentorium is faintly visible passing over the cerebellum***

### **Tentorium cerebelli - clinical significance**

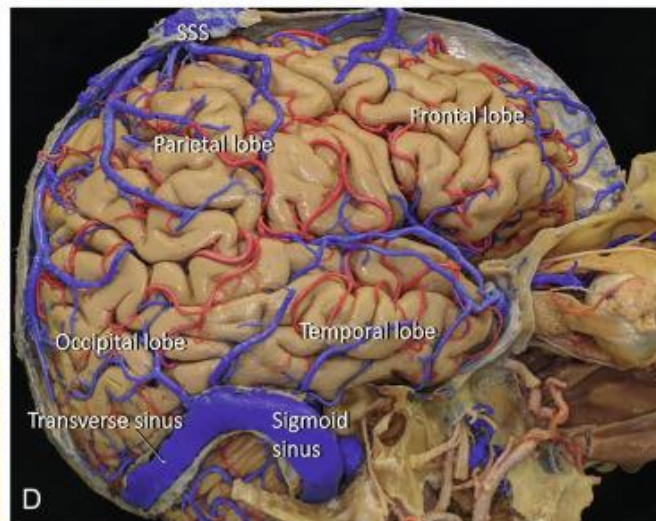
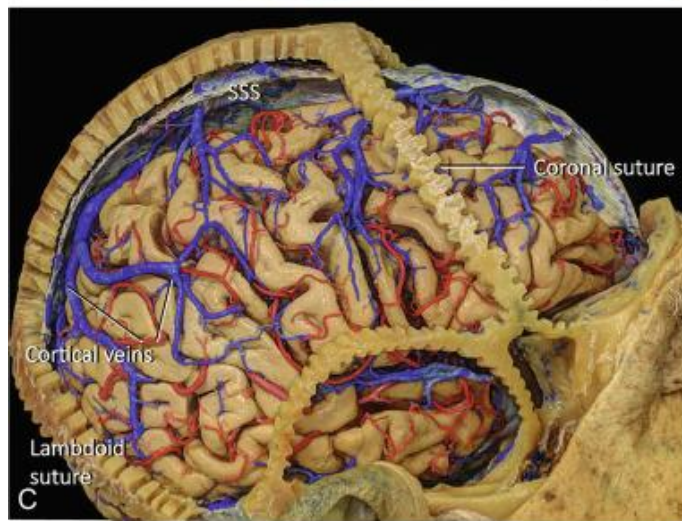
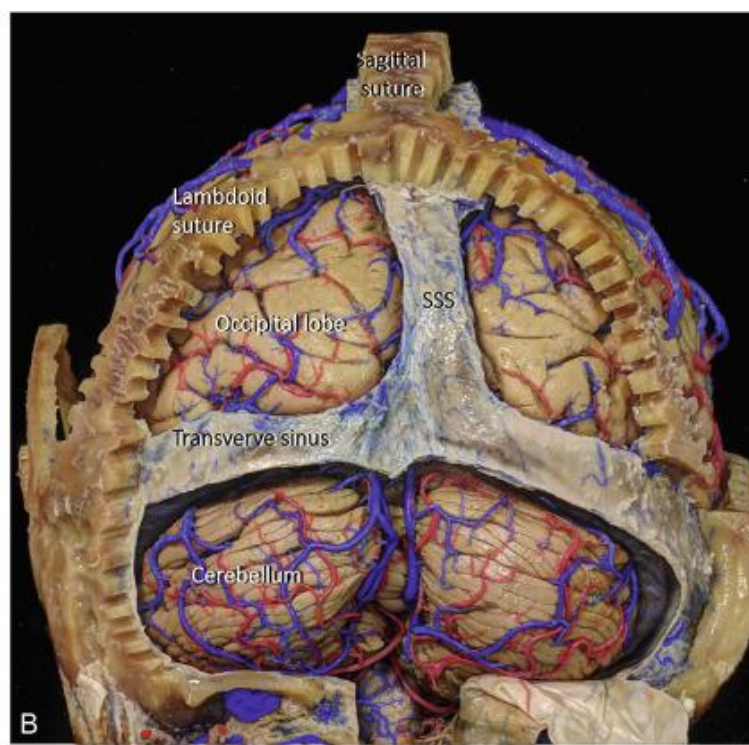
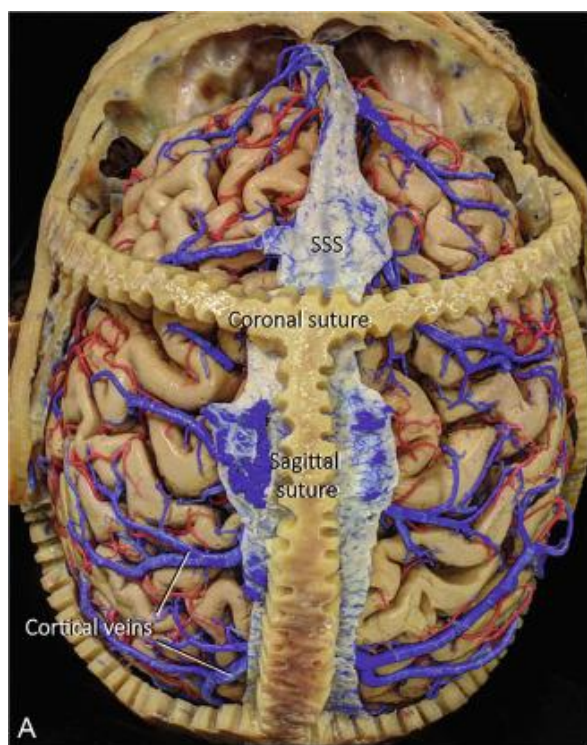
***In the context of subarachnoid hemorrhage or subdural hematoma the tent may become more dense due to layering of blood.***

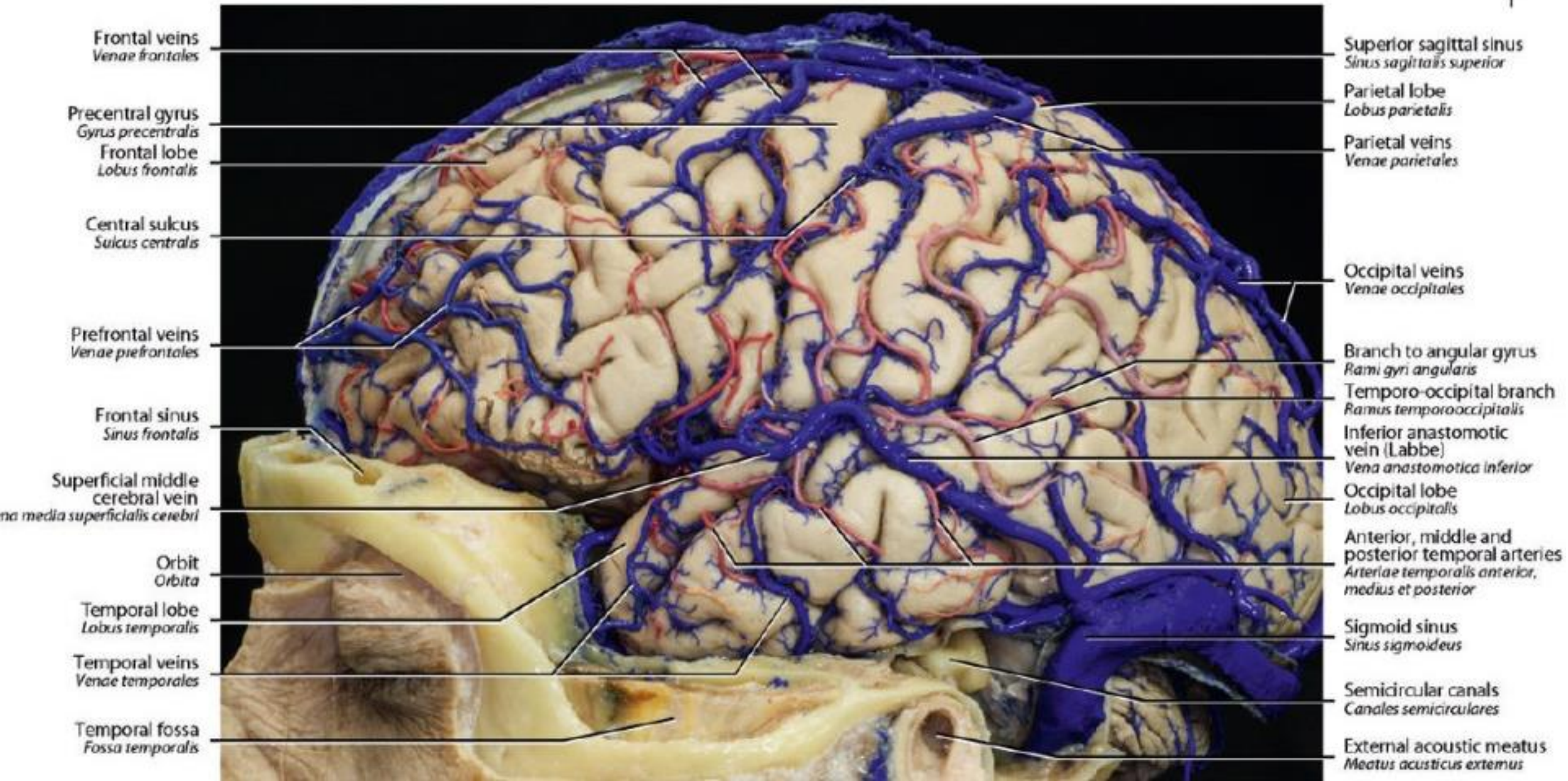
# The Tentorium Cerebelli



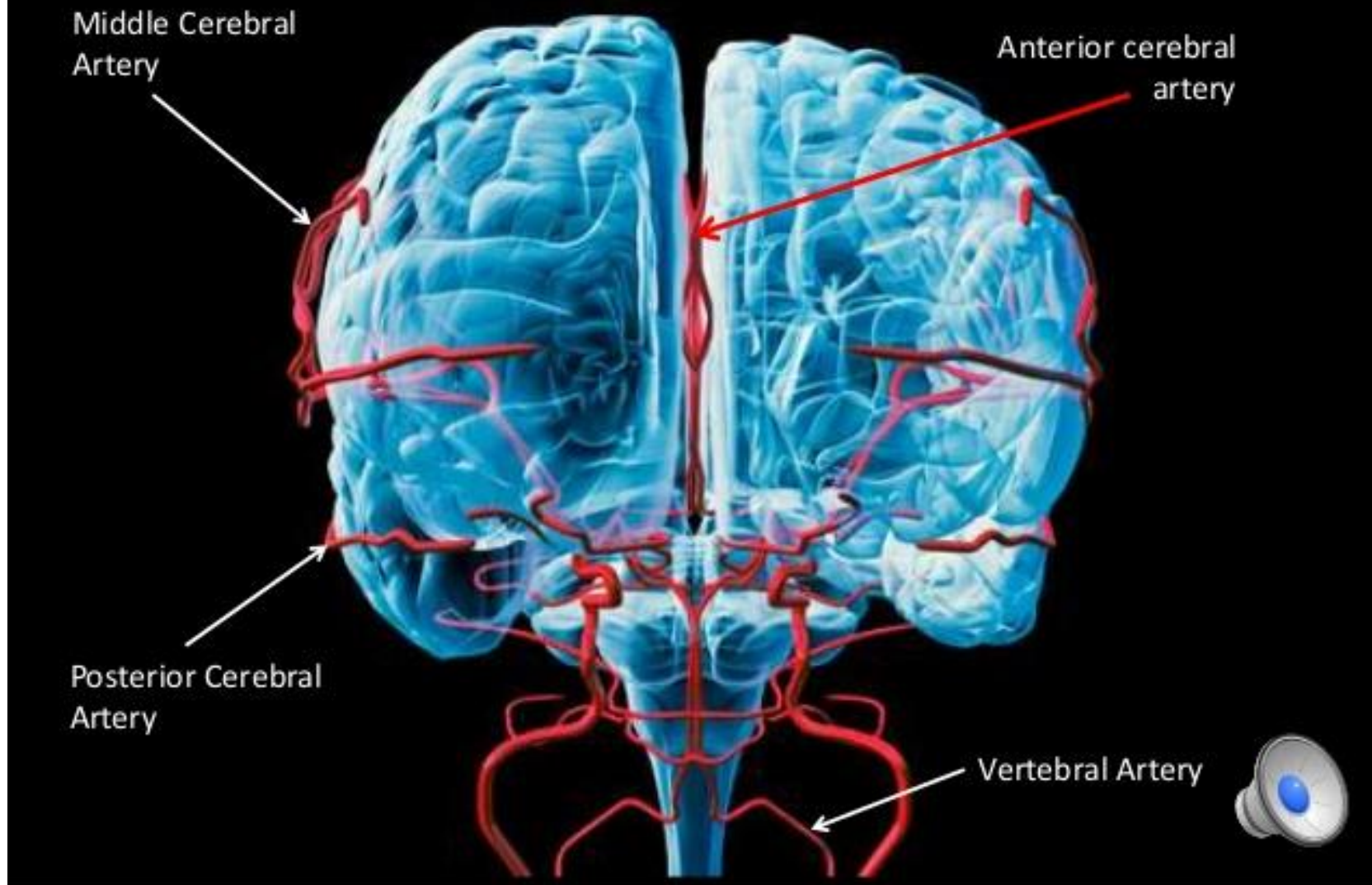


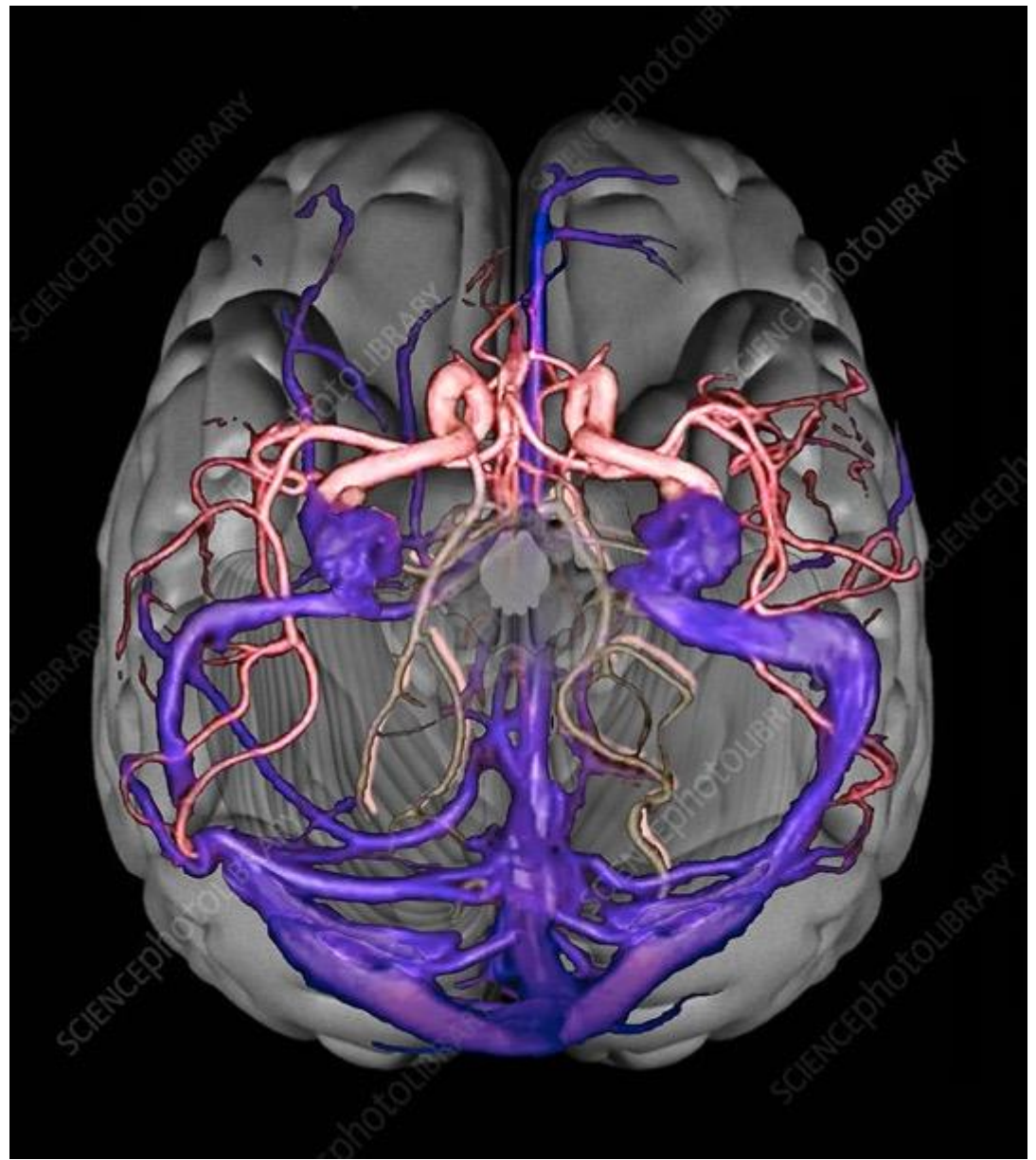
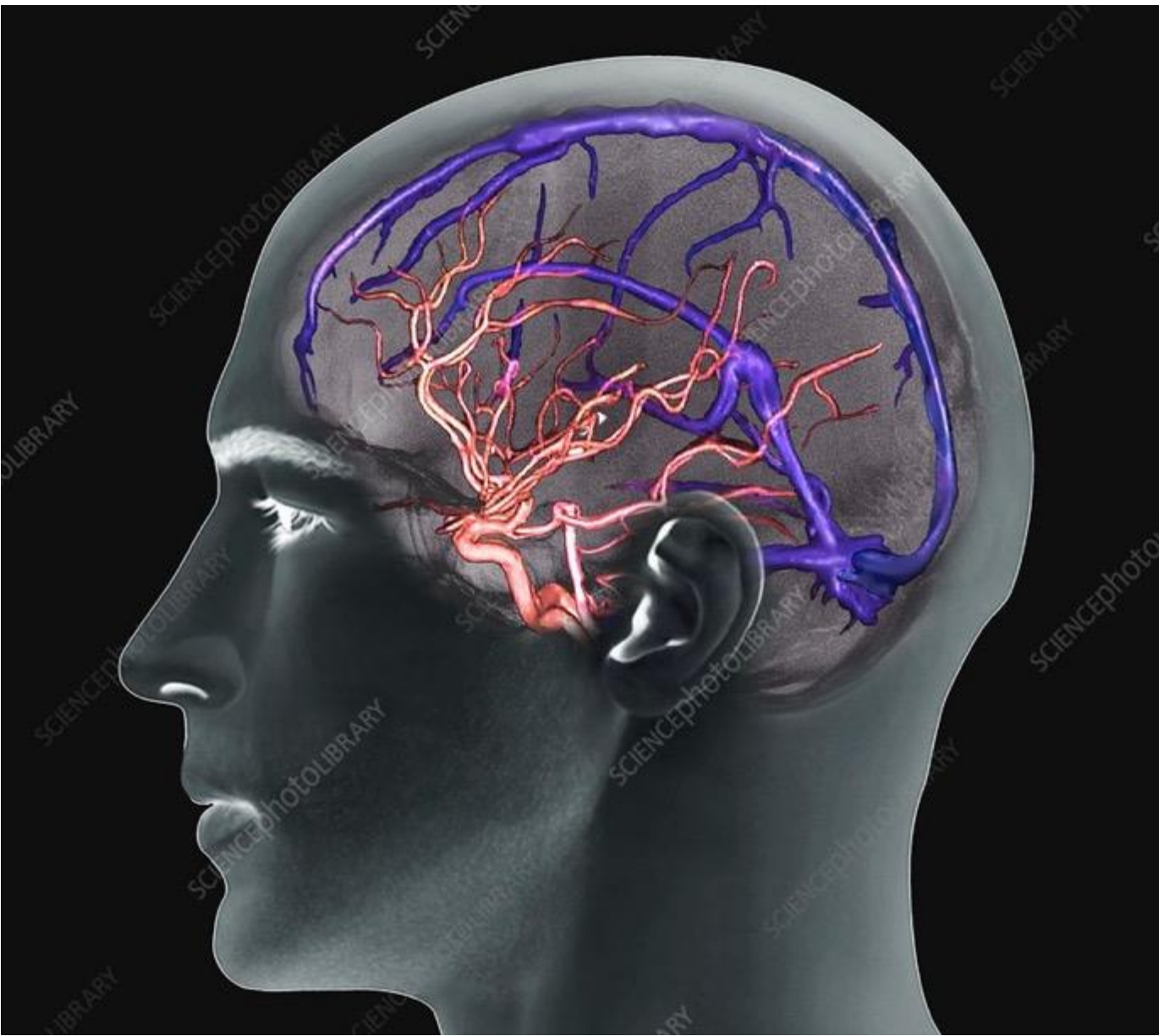
# 4. Sistem Arteri dan Vena



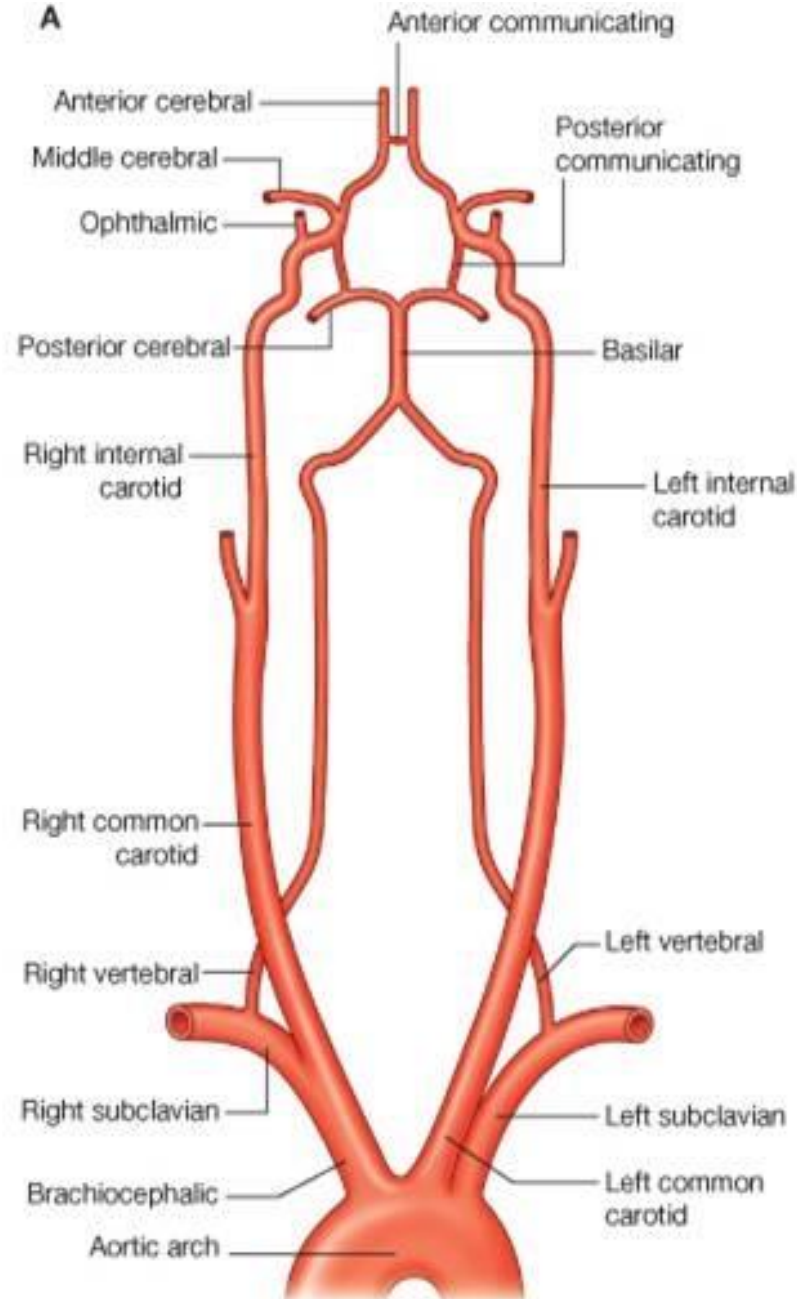


# 3D Perspective

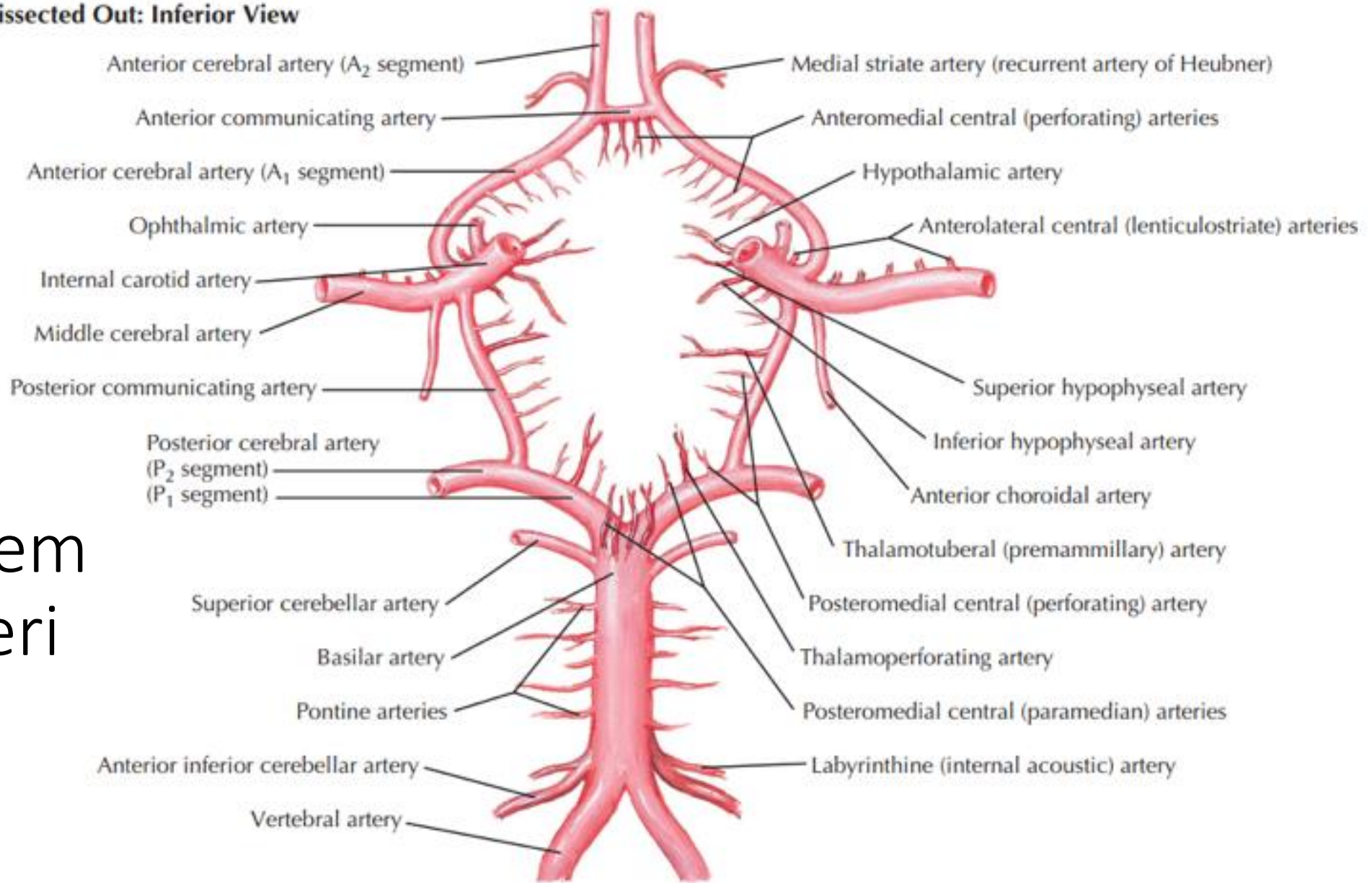




# Sistem Arteri



## Vessels Dissected Out: Inferior View



# Sistem Arteri

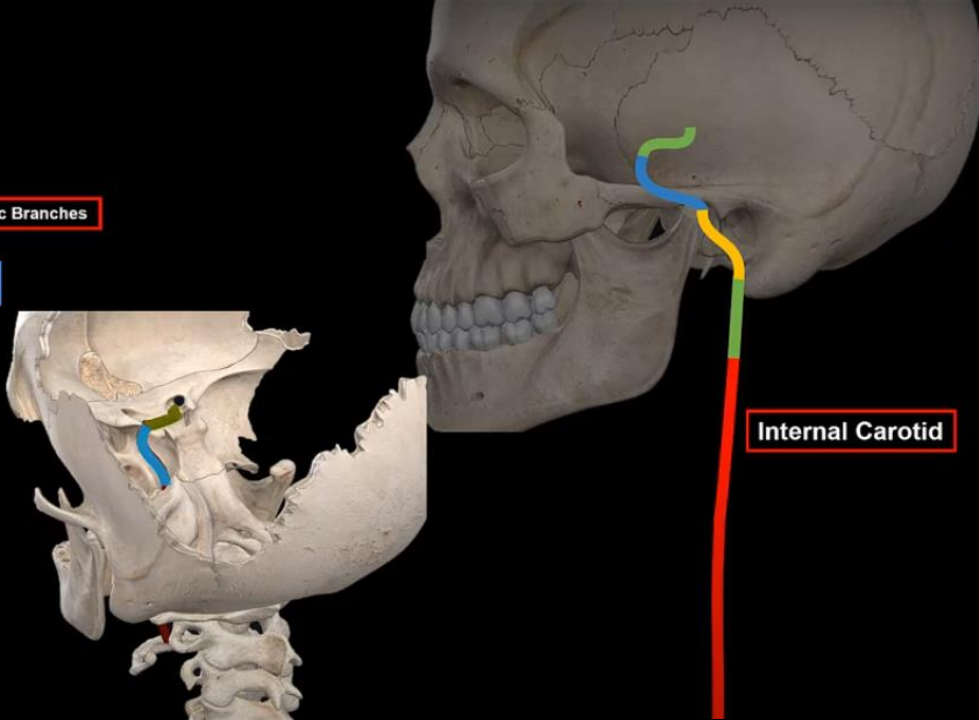
Cervical Part

Petrous Part

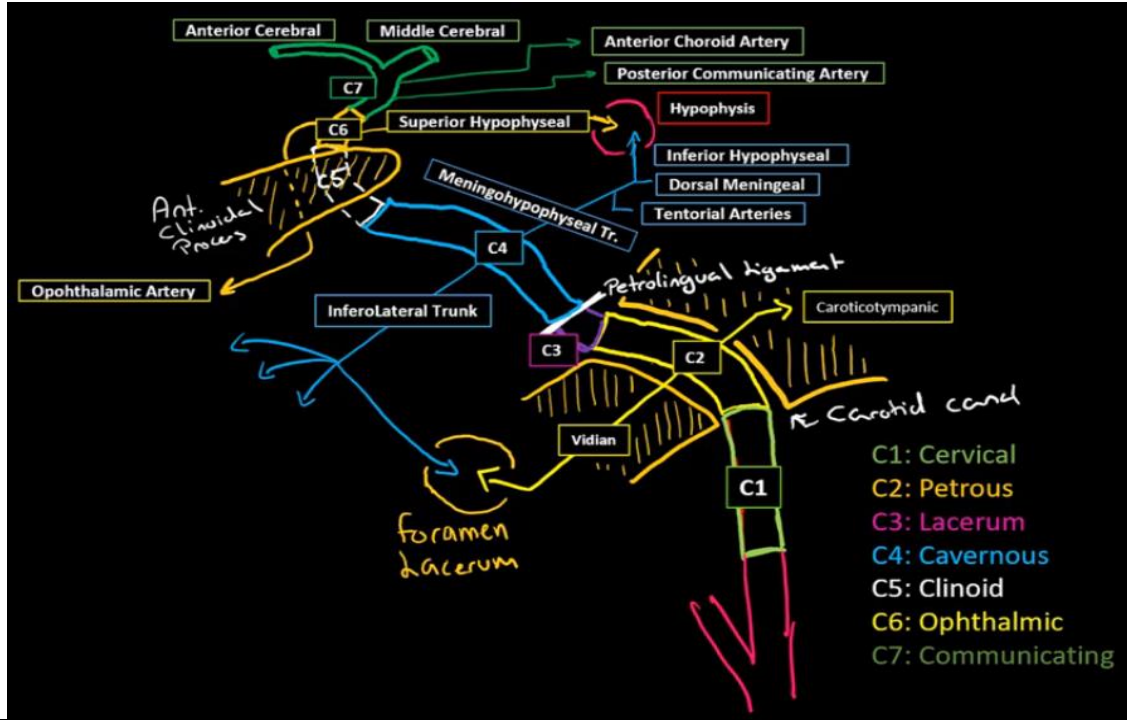
Caroticotympanic Branches

Cavernous Part

Cerebral Part



Internal Carotid



- C1: Cervical
- C2: Petrous
- C3: Lacerum
- C4: Cavernous
- C5: Clinoid
- C6: Ophthalmic
- C7: Communicating

Cervical Part

Petrous Part

Caroticotympanic Branches

Cavernous Part

Cerebral Part

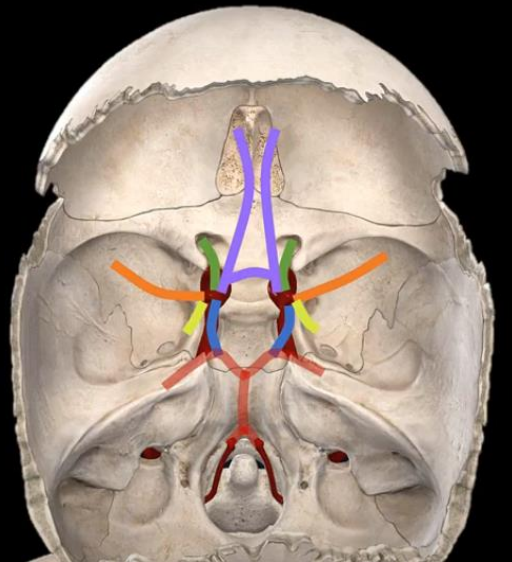
Ophthalmic Artery

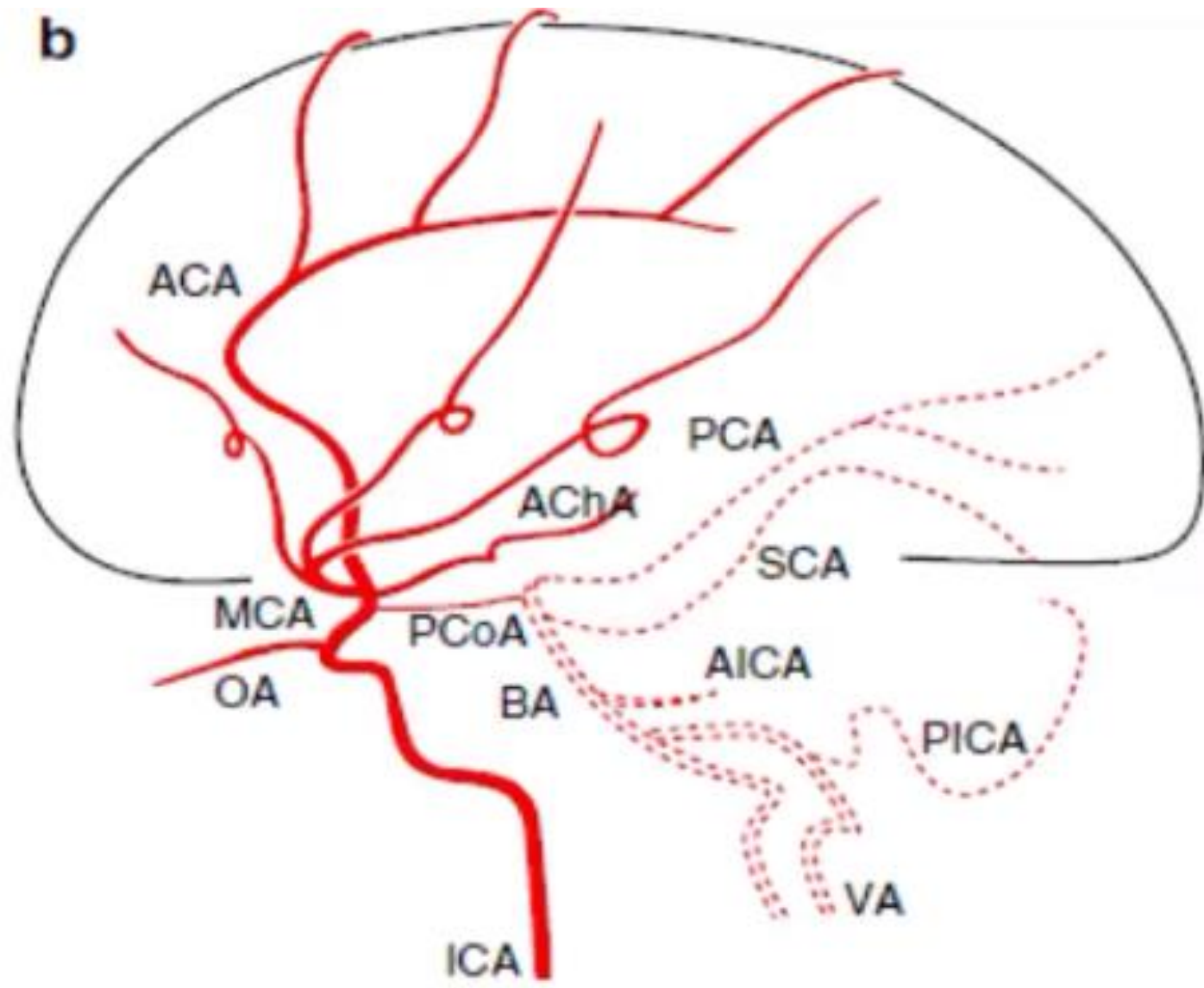
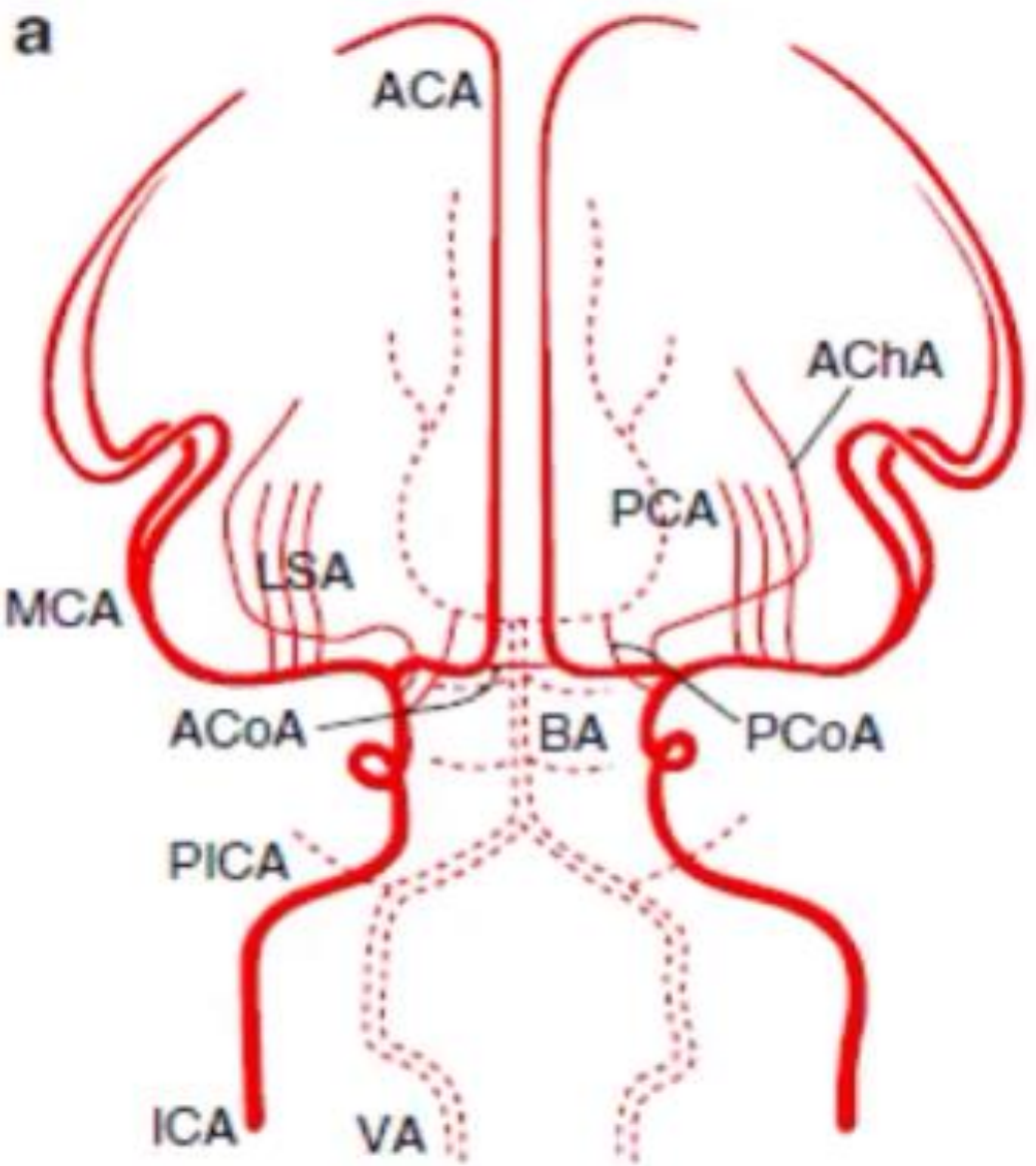
Anterior Cerebral Artery

Middle Cerebral Artery

Posterior Communicating Artery

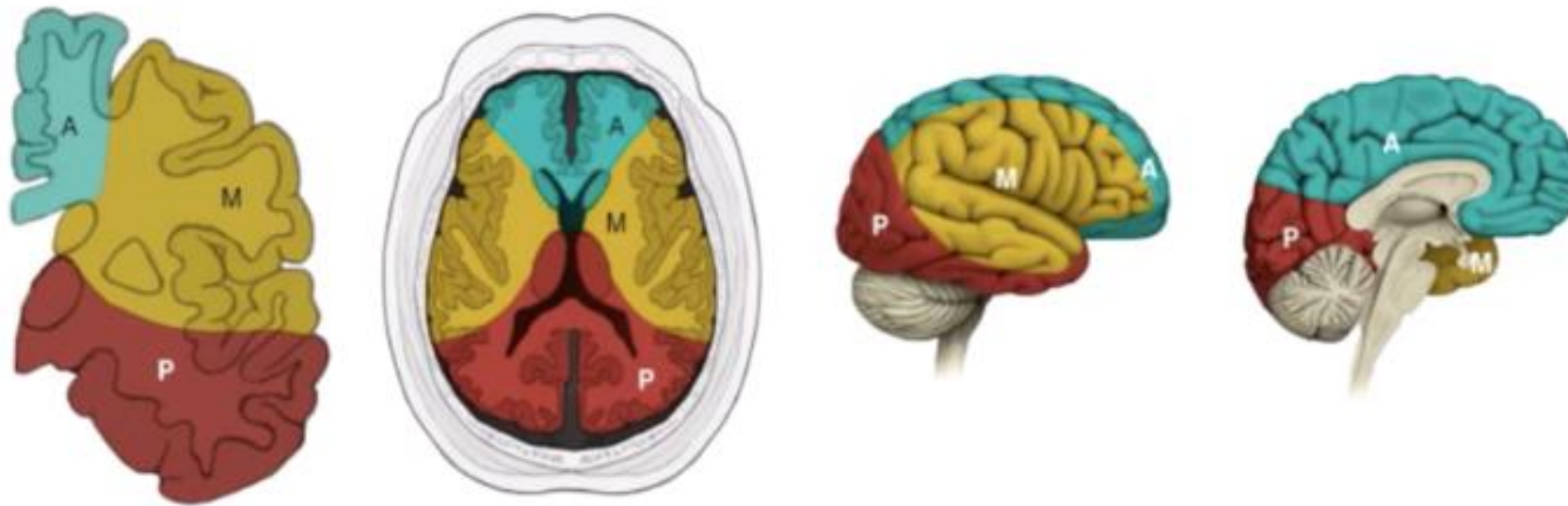
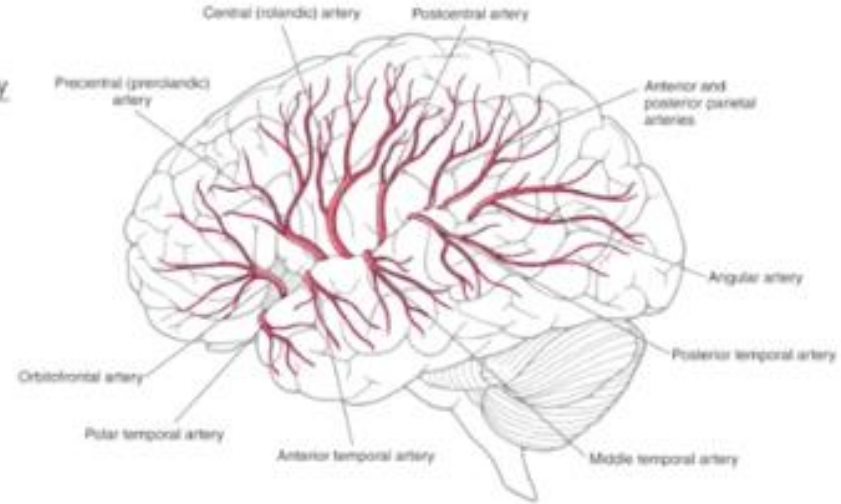
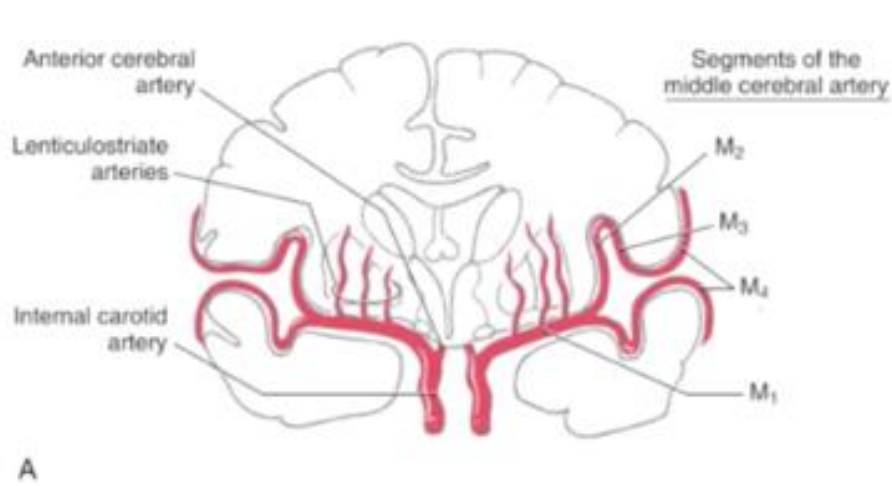
Anterior Choroid Artery

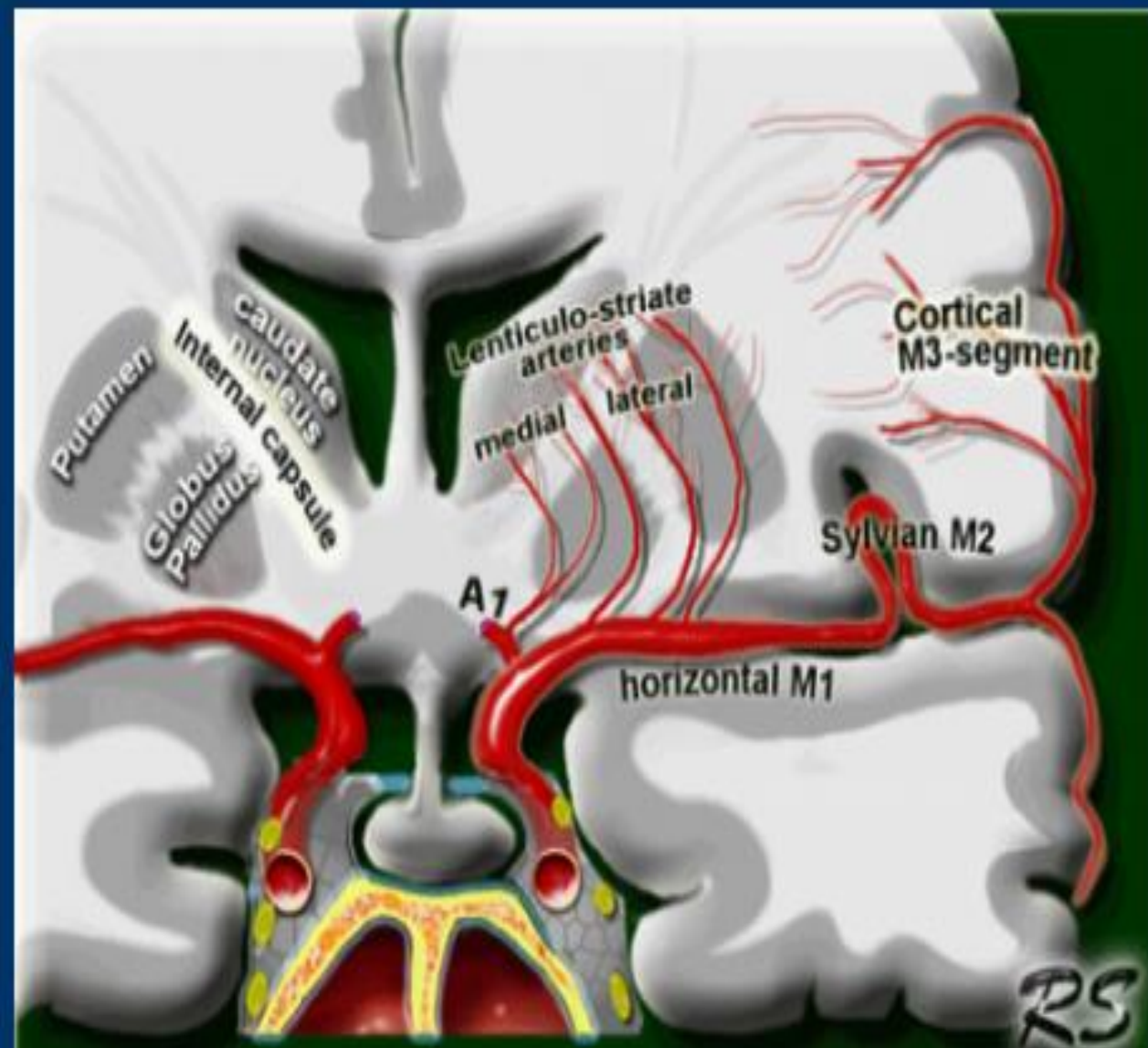






# The middle cerebral artery





## Lenticulo-striate arteries

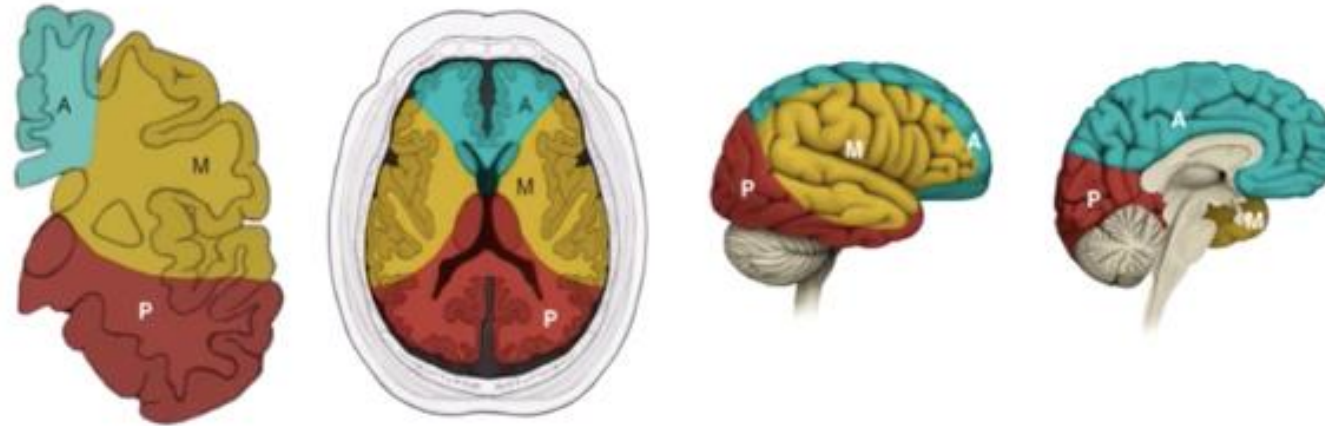
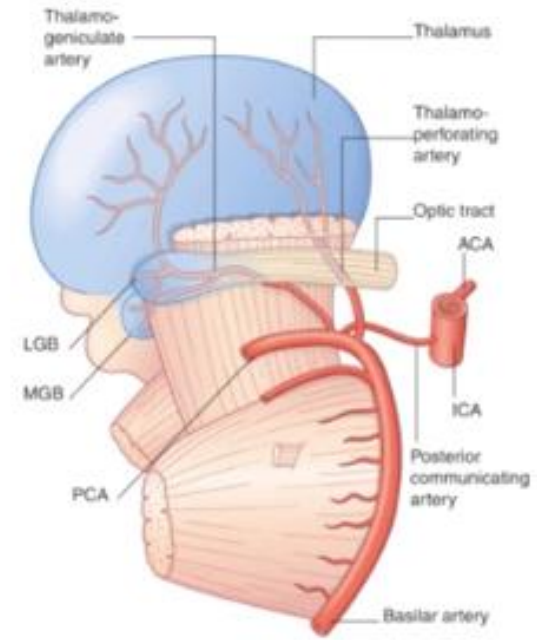
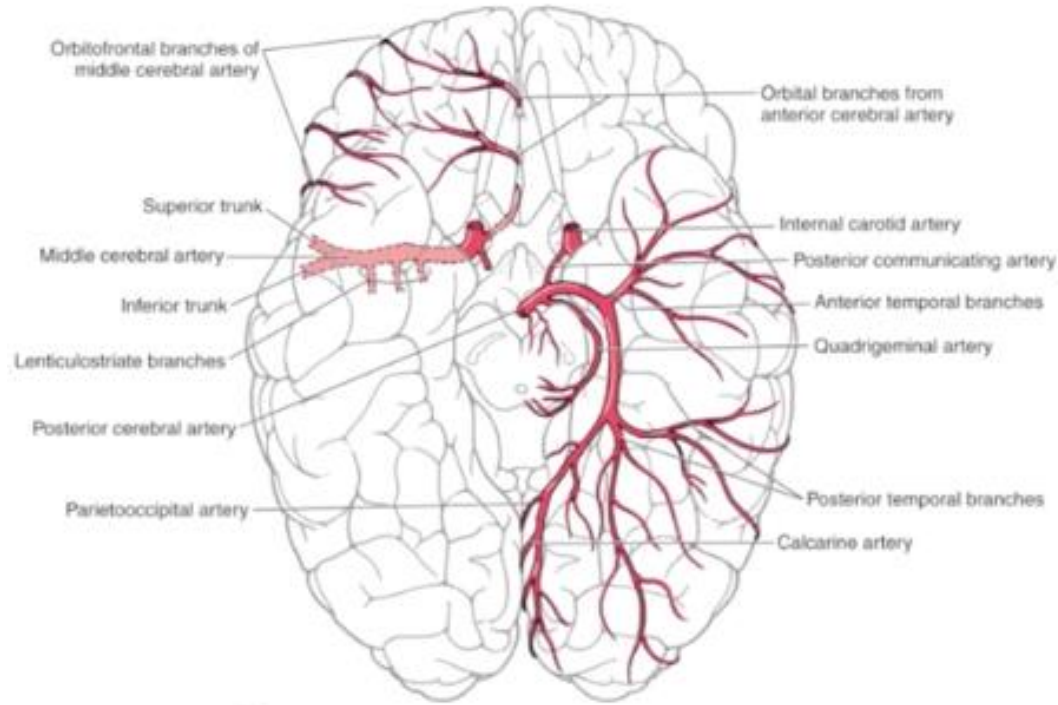
### **Medial lenticulo-striate arteries**

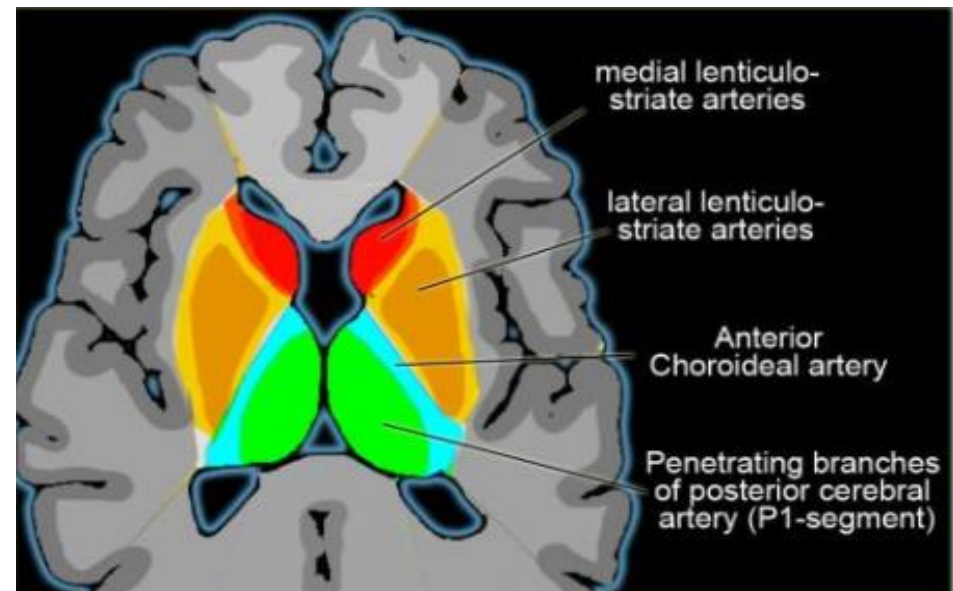
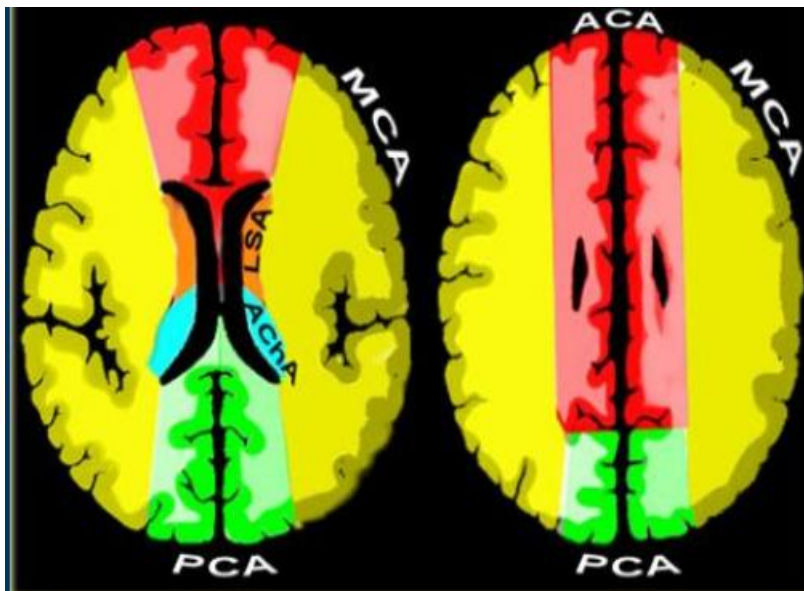
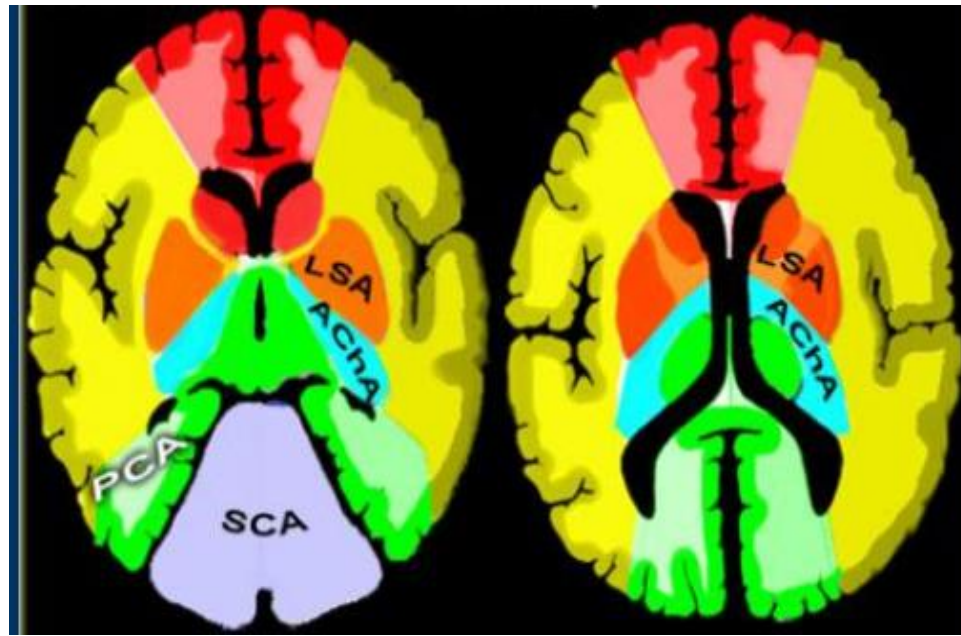
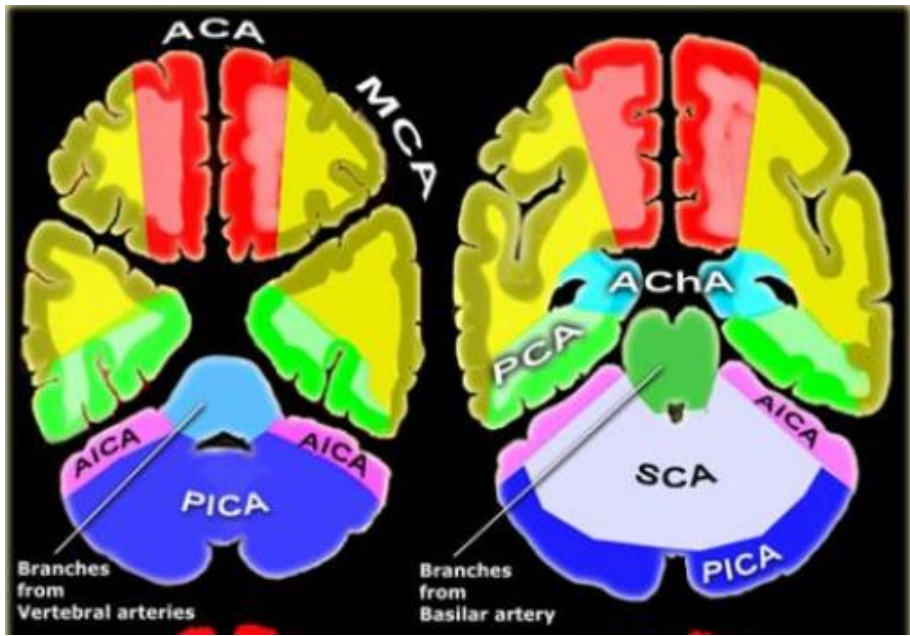
They are branches of the A1-segment of the anterior cerebral artery. They supply the anterior inferior parts of the basal nuclei. They also supply the anterior limb of the internal capsule together with the recurrent artery of Huebner, which also is a branch of the anterior cerebral artery.

### **Lateral lenticulo-striate arteries**

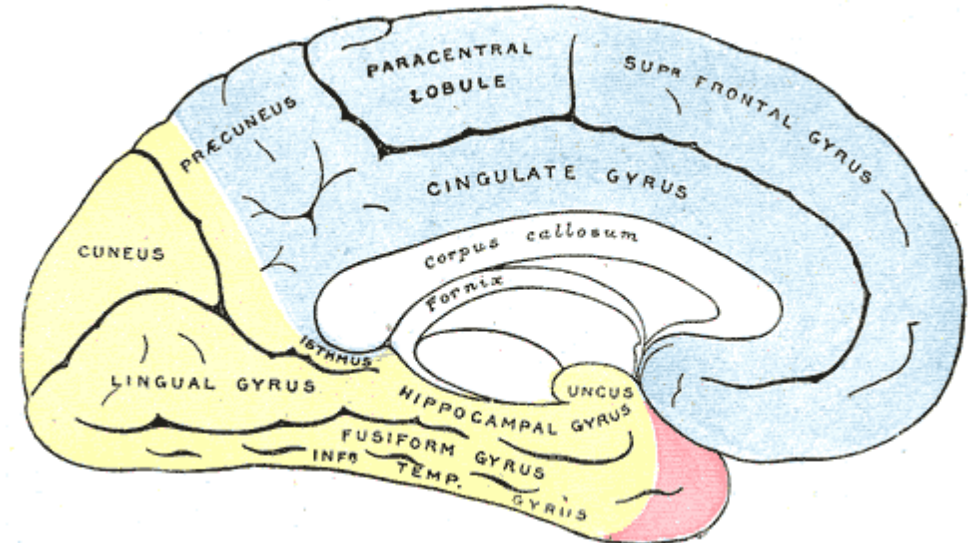
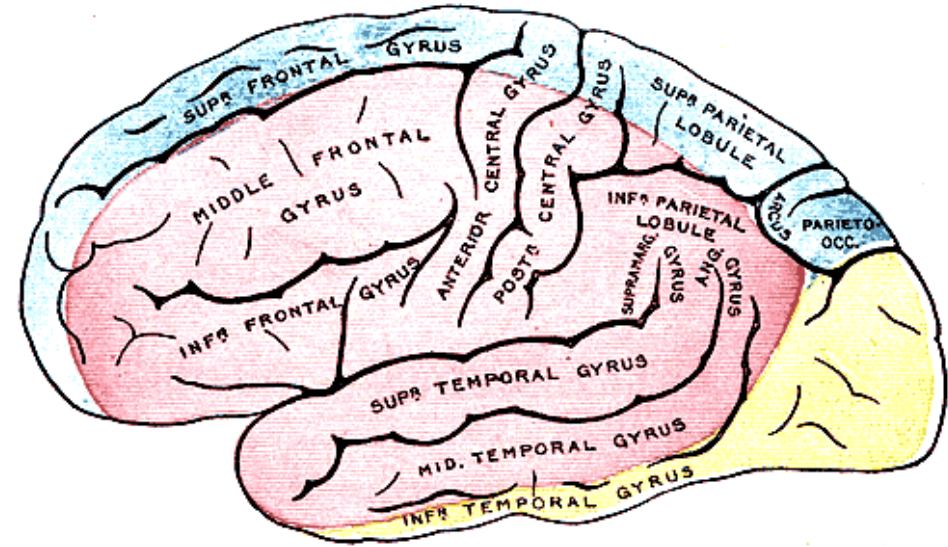
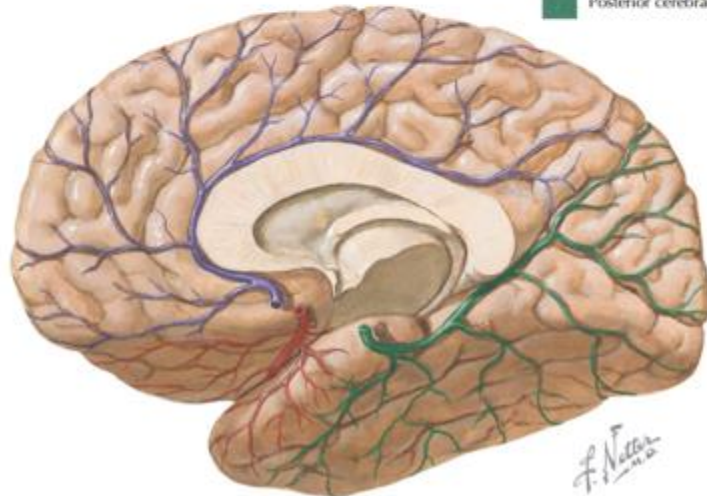
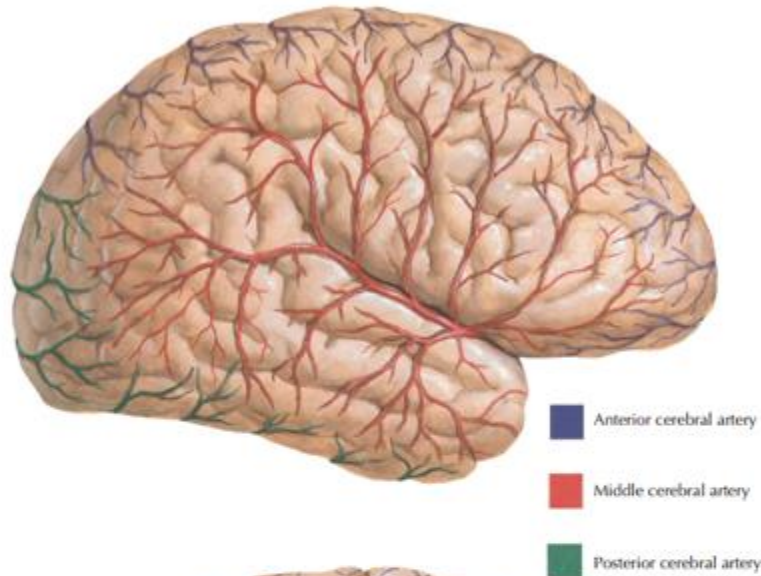
They are branches of the horizontal M1-segment of the middle cerebral artery. They supply the superior part of the head and the body of the caudate nucleus, most of the globus pallidus and putamen. They also supply the anterior limb of the internal capsule and parts of the posterior limb of the internal capsule, which is largely supplied by the [anterior choroidal artery](#).

# The posterior cerebral arteries



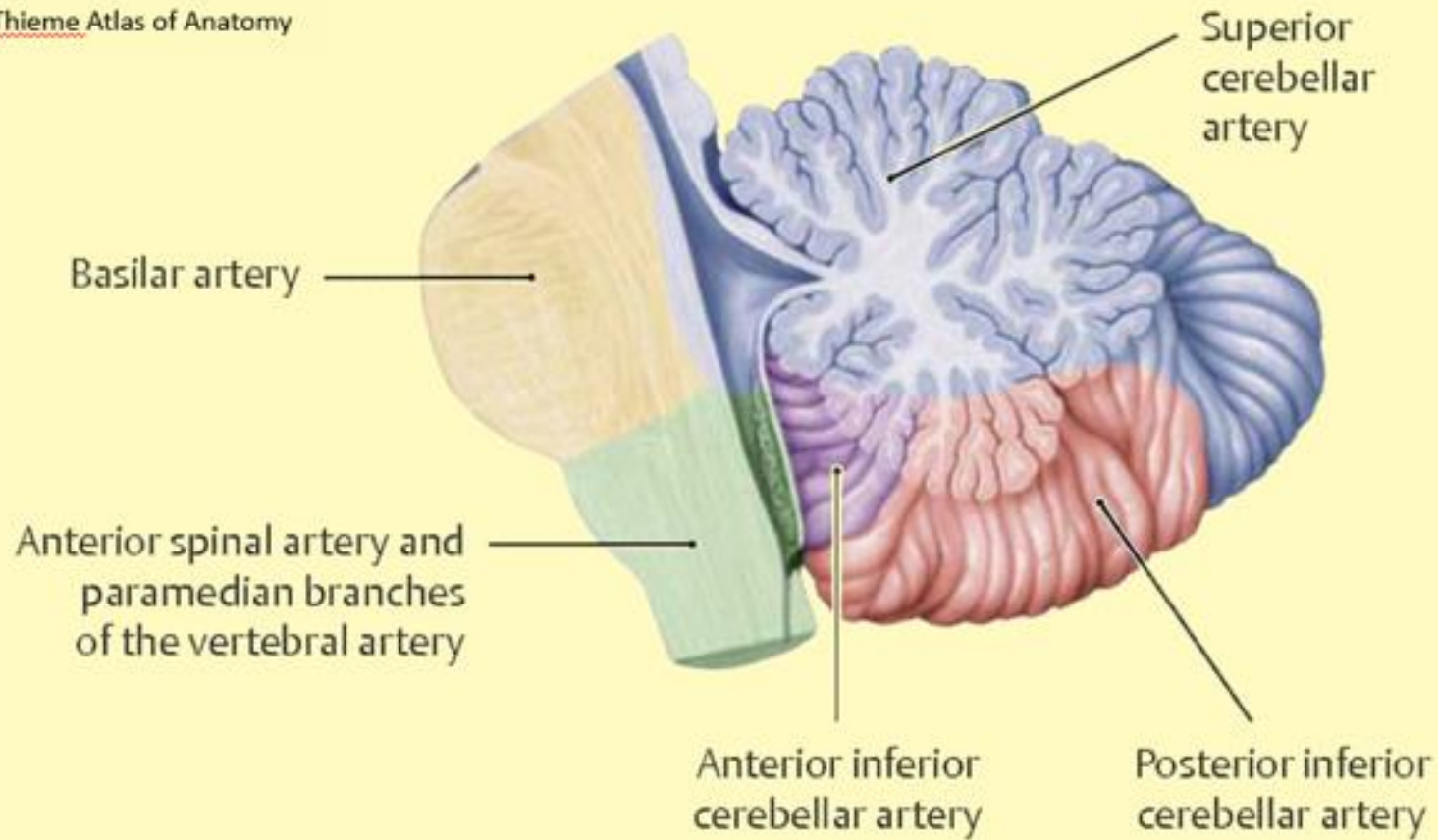


# Vaskularisasi Otak



# Arterial Supply to Cerebellum

Thieme Atlas of Anatomy



**Think:** Midbrain/SCP/Anterior lobe, deep nuclei/Superior Cerebellar Artery  
Pons/MCP/Basilar and AICA  
Medulla/ICP/Posterior lobe/PICA

# Sistem Vena Otak

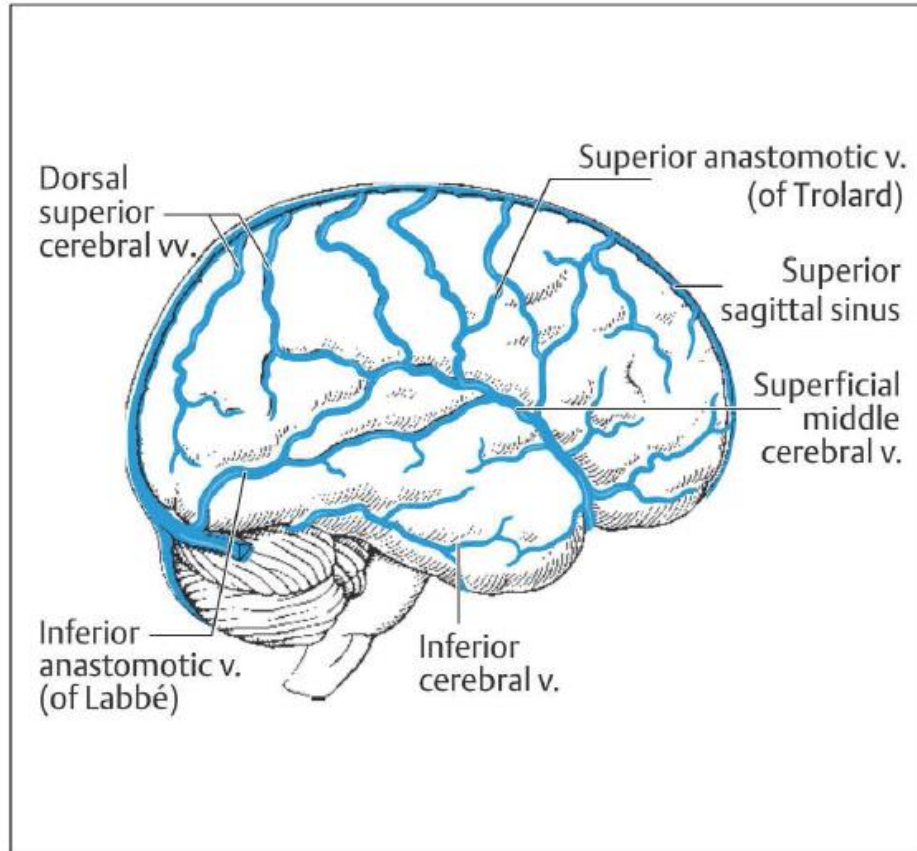


Fig. 11.13 Veins of the brain, lateral view

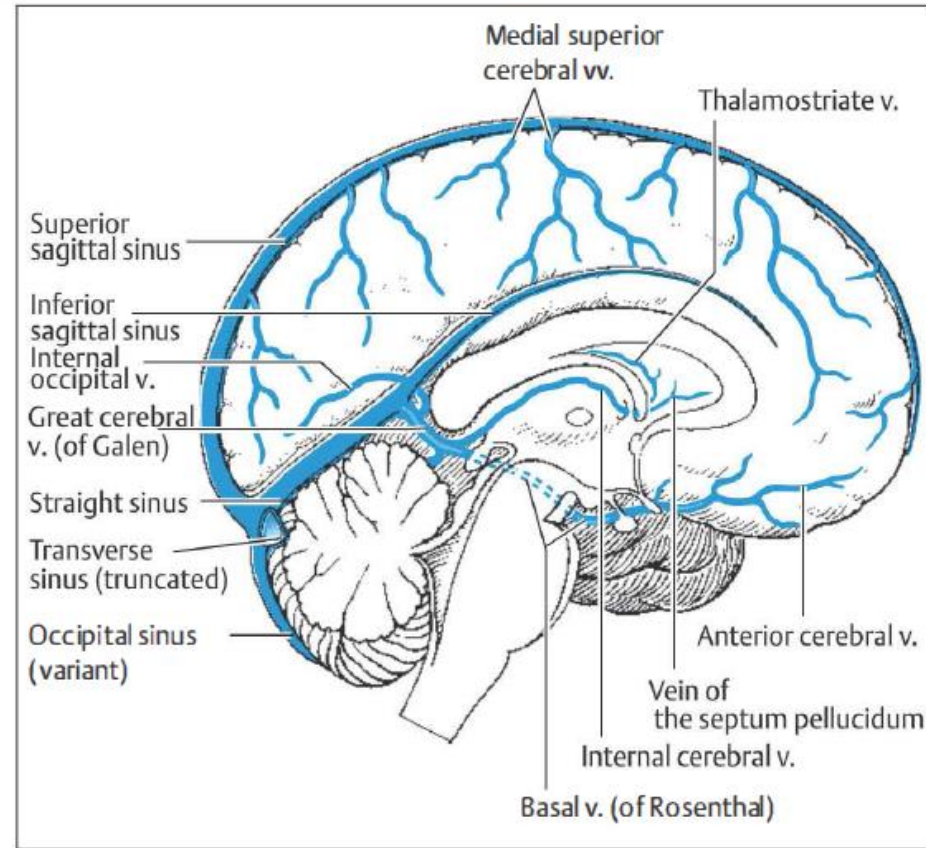
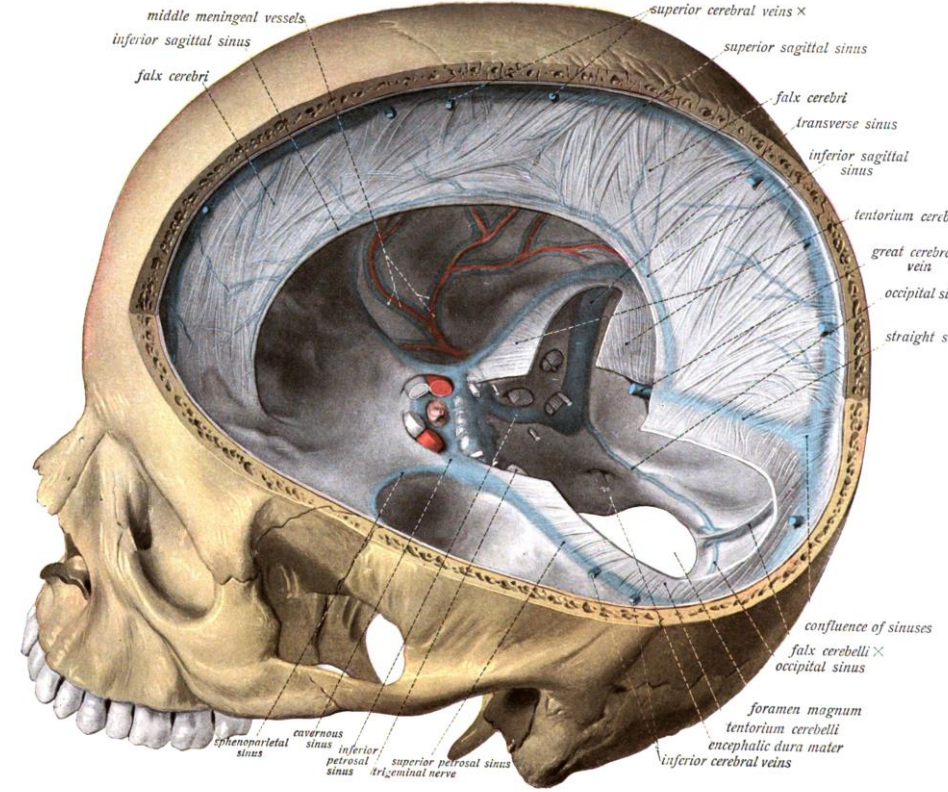
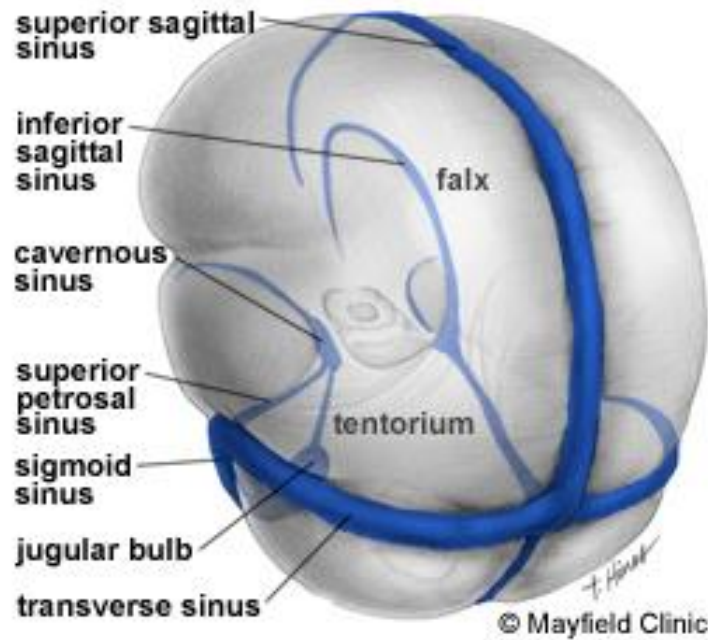
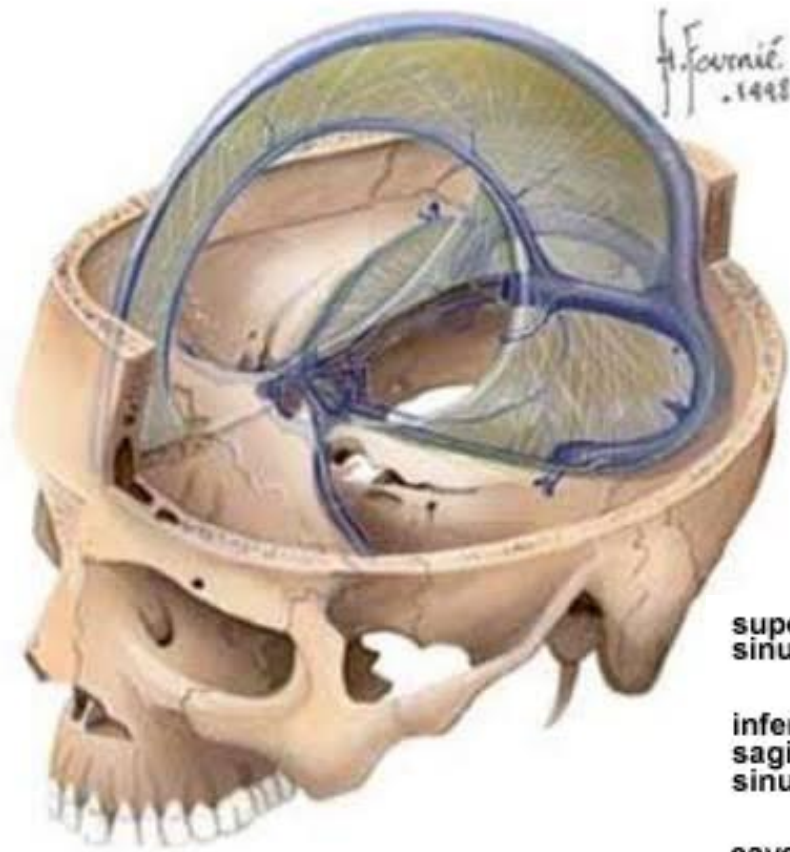
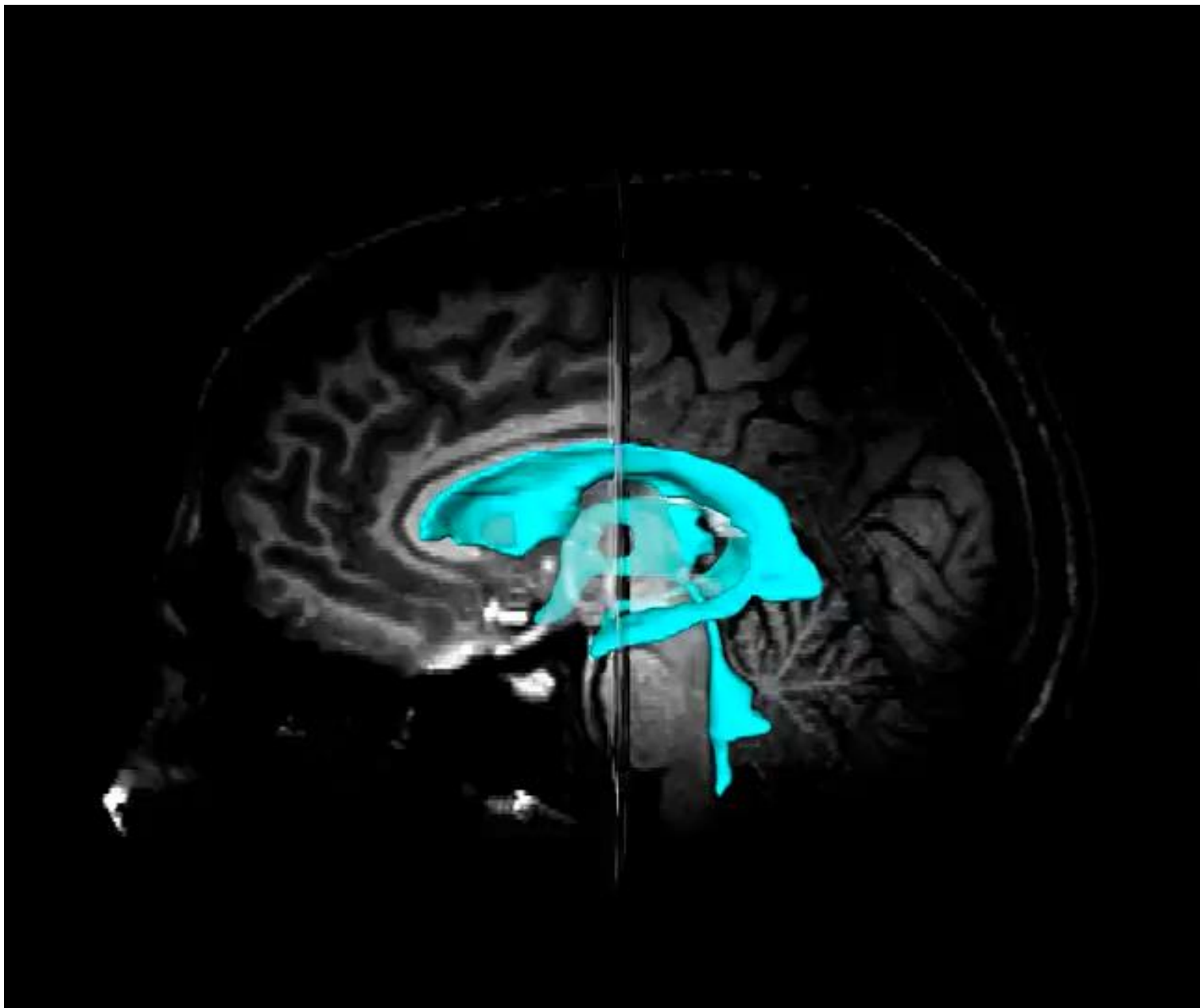


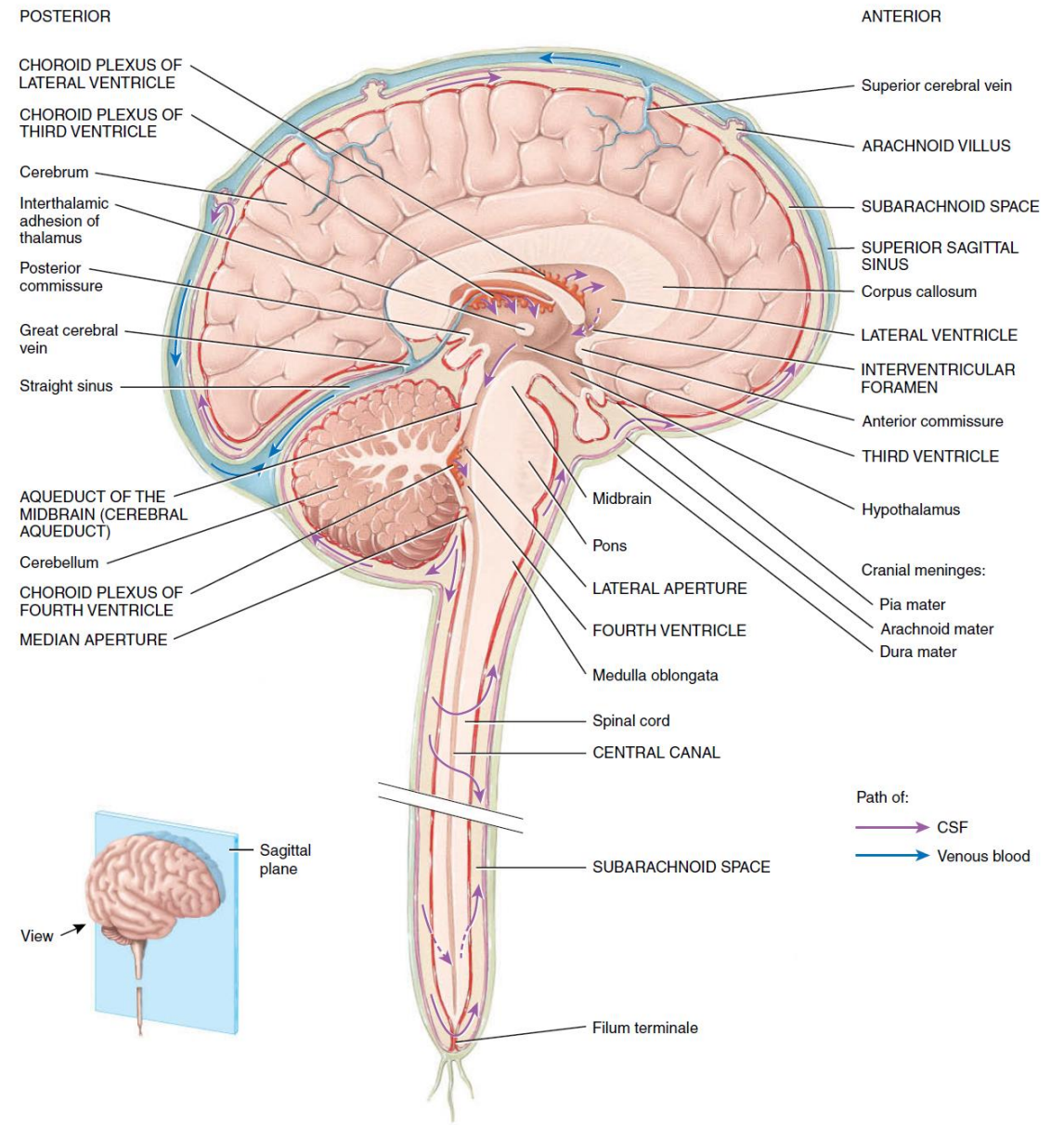
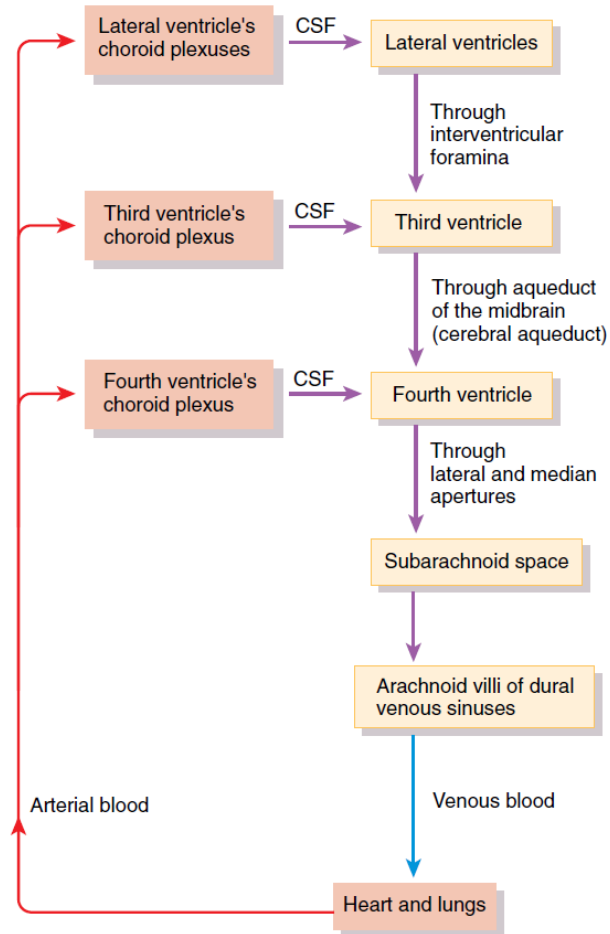
Fig. 11.14 Veins of the brain, medial view

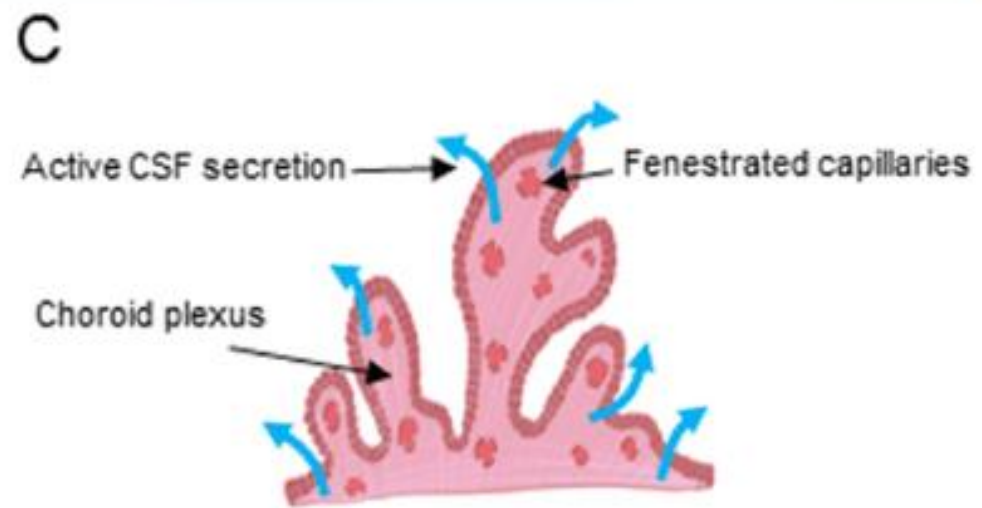
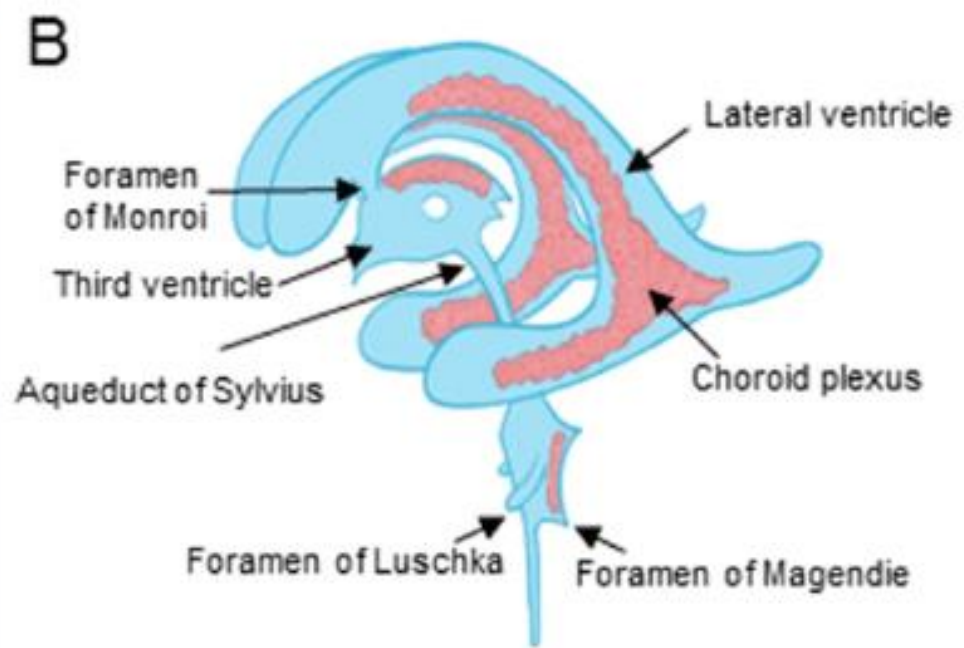
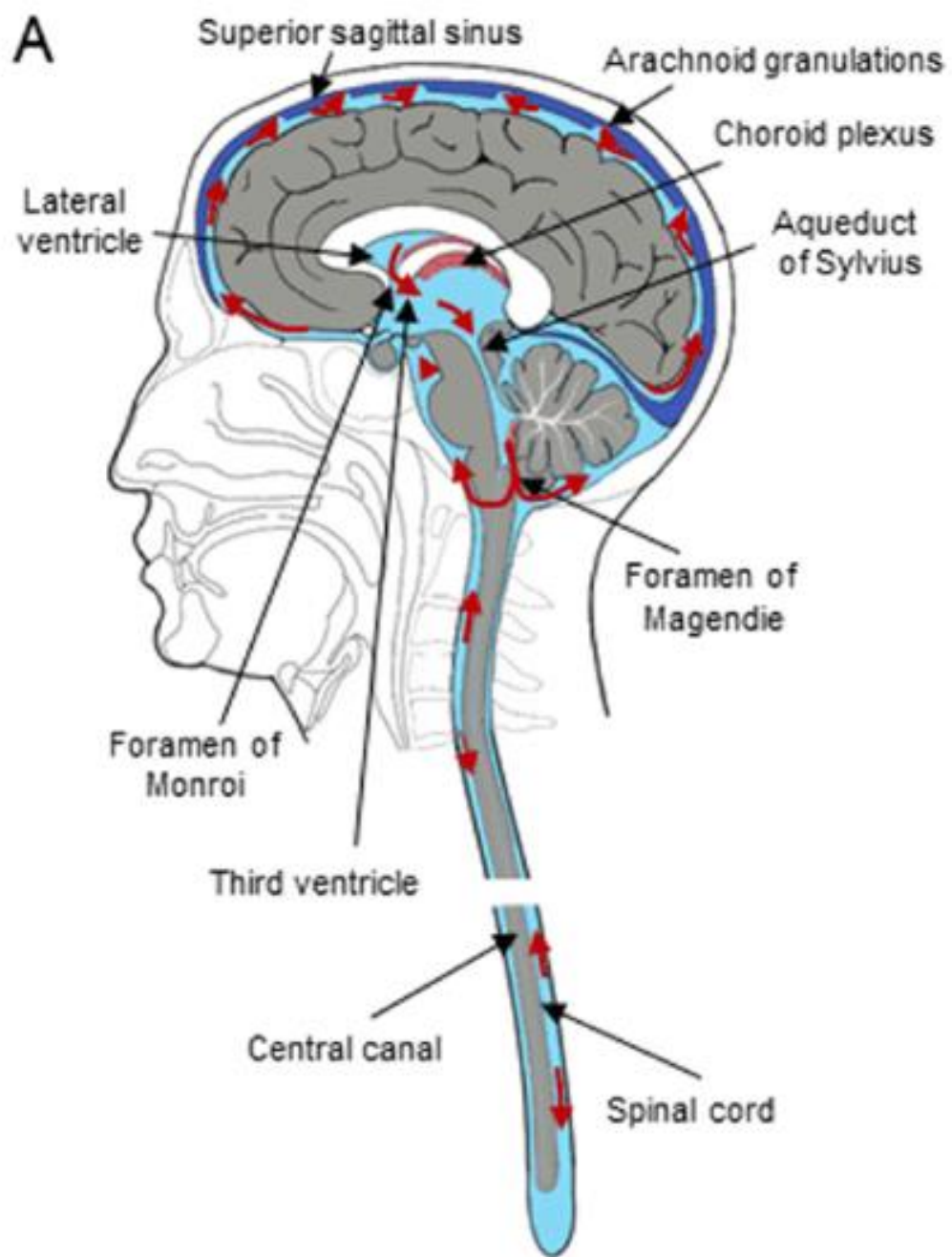


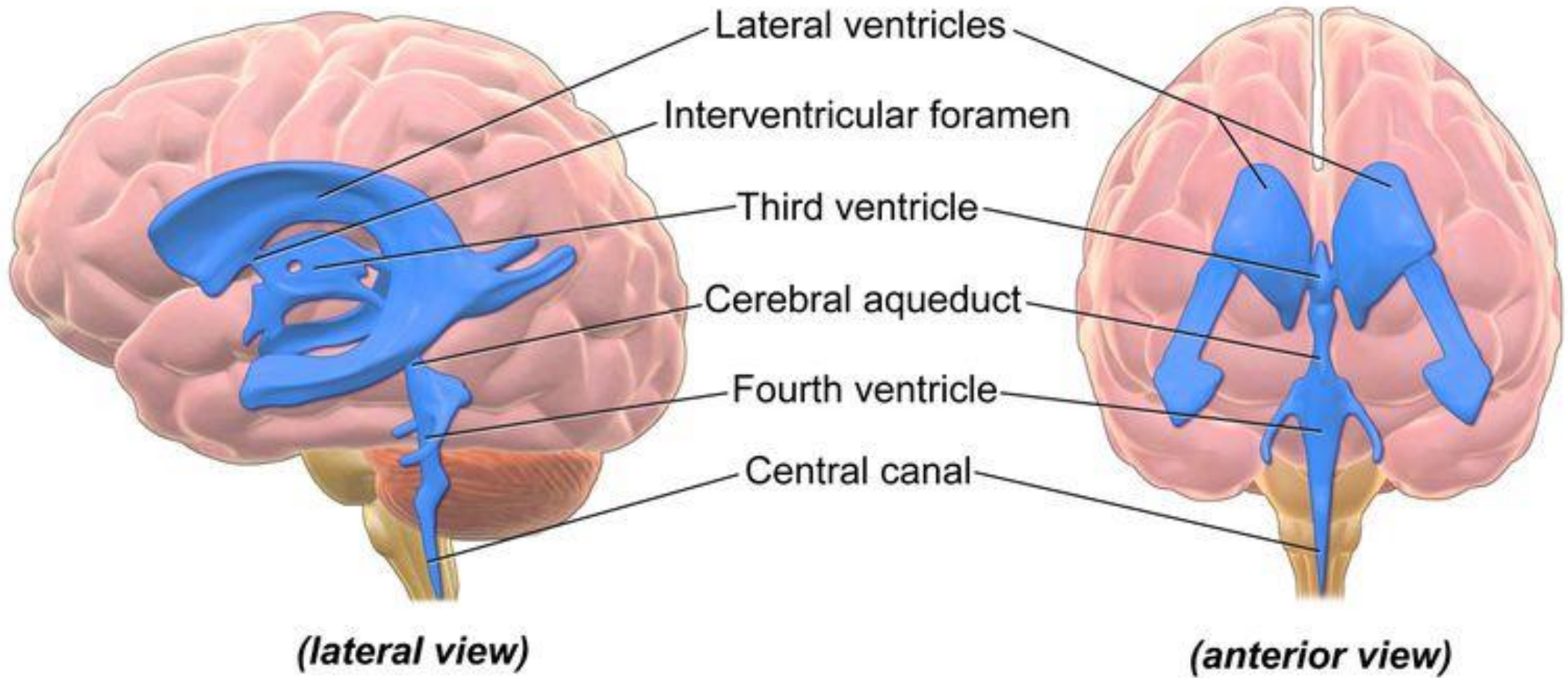
# 5. SISTEM VENTRIKEL DAN ALIRAN LCS



# Sistem Ventrikel dan Sirkulasi CSF







# Sesi 2

# Aplikasi Neuroanatomi dalam Pemeriksaan Imaging

Sesi 2

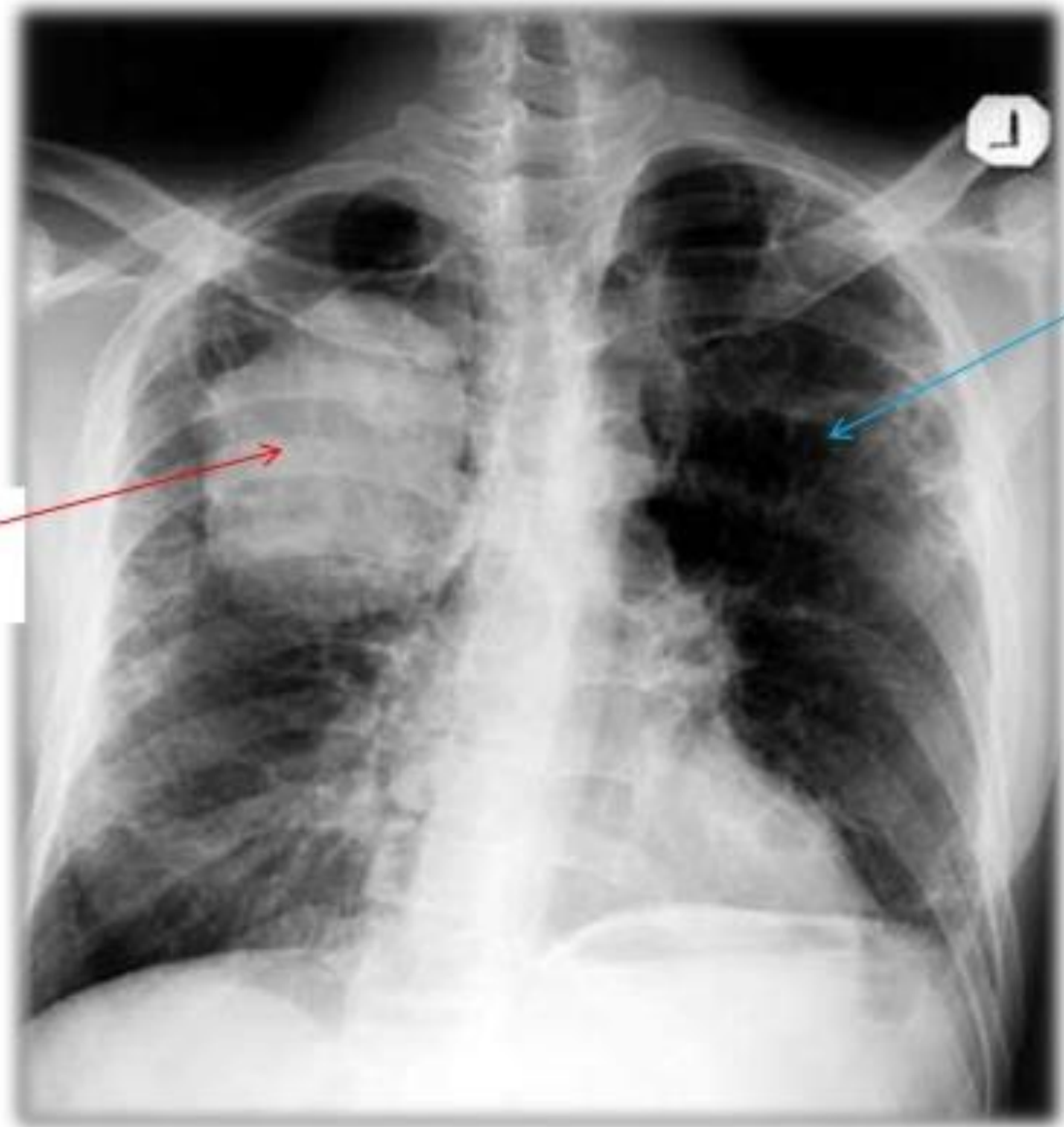
# Outline

1. Konsep dasar pemeriksaan imaging
  1. X ray Based
    1. Skull
    2. CT
    3. DSA
  2. Magnetic Based
2. Jenis potongan dalam pemeriksaan imaging
3. Gambaran normal pada CT scan
  1. Tulang
  2. Cerebral dan cerebellum
  3. Vaskularisasi

# 1. Konsep dasar pemeriksaan imaging

X - ray

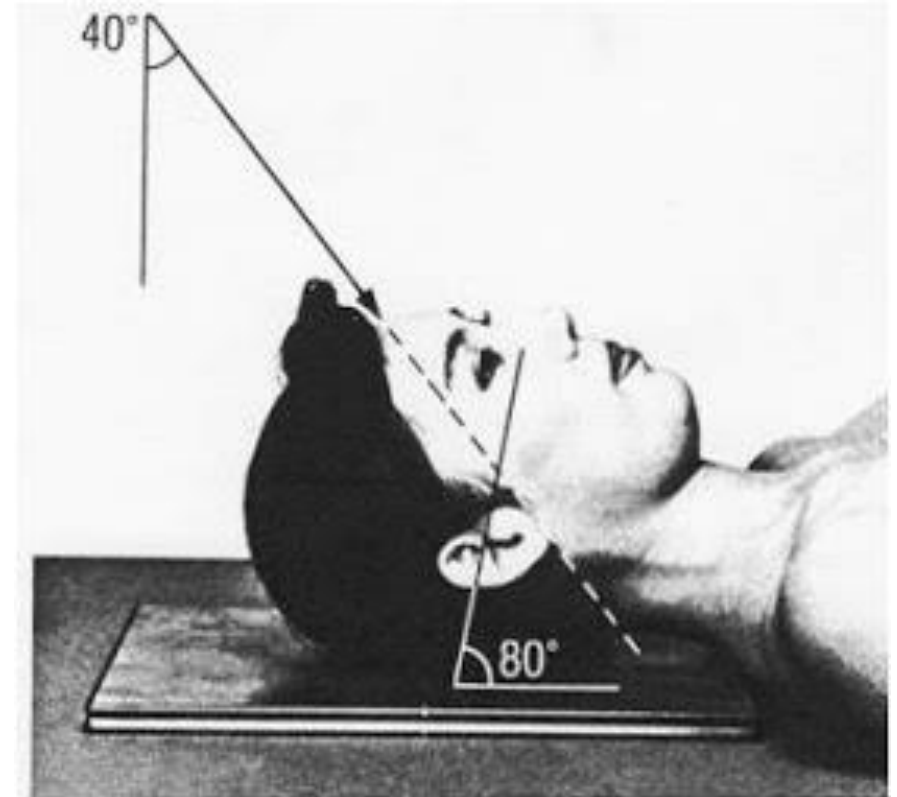
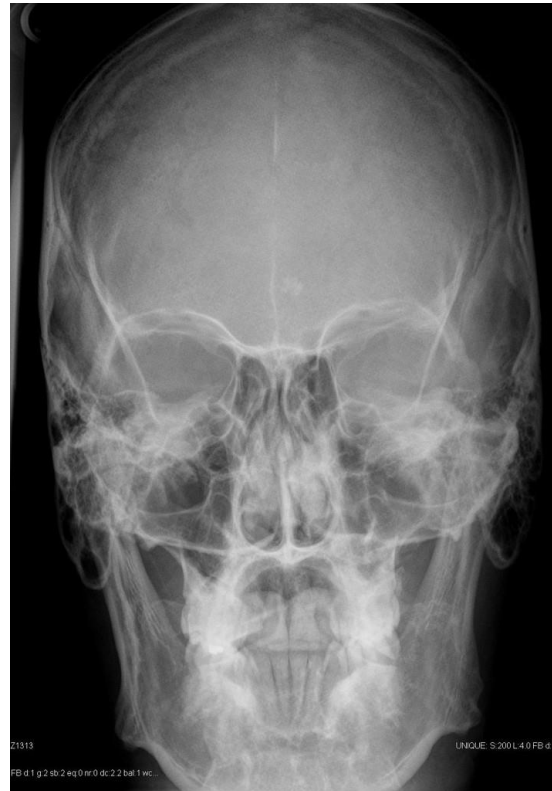RADIODENSE  
RADIOPAQUE

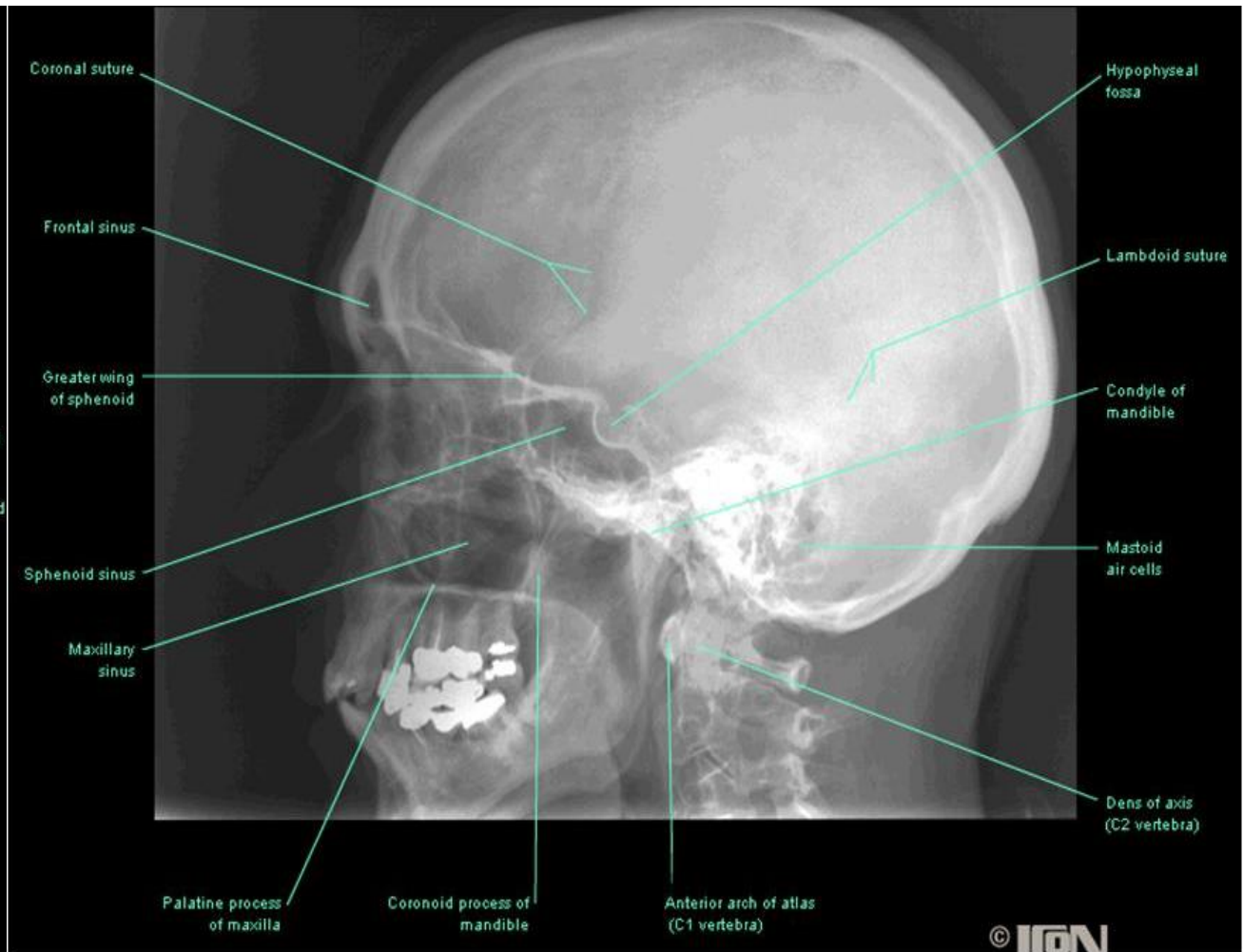
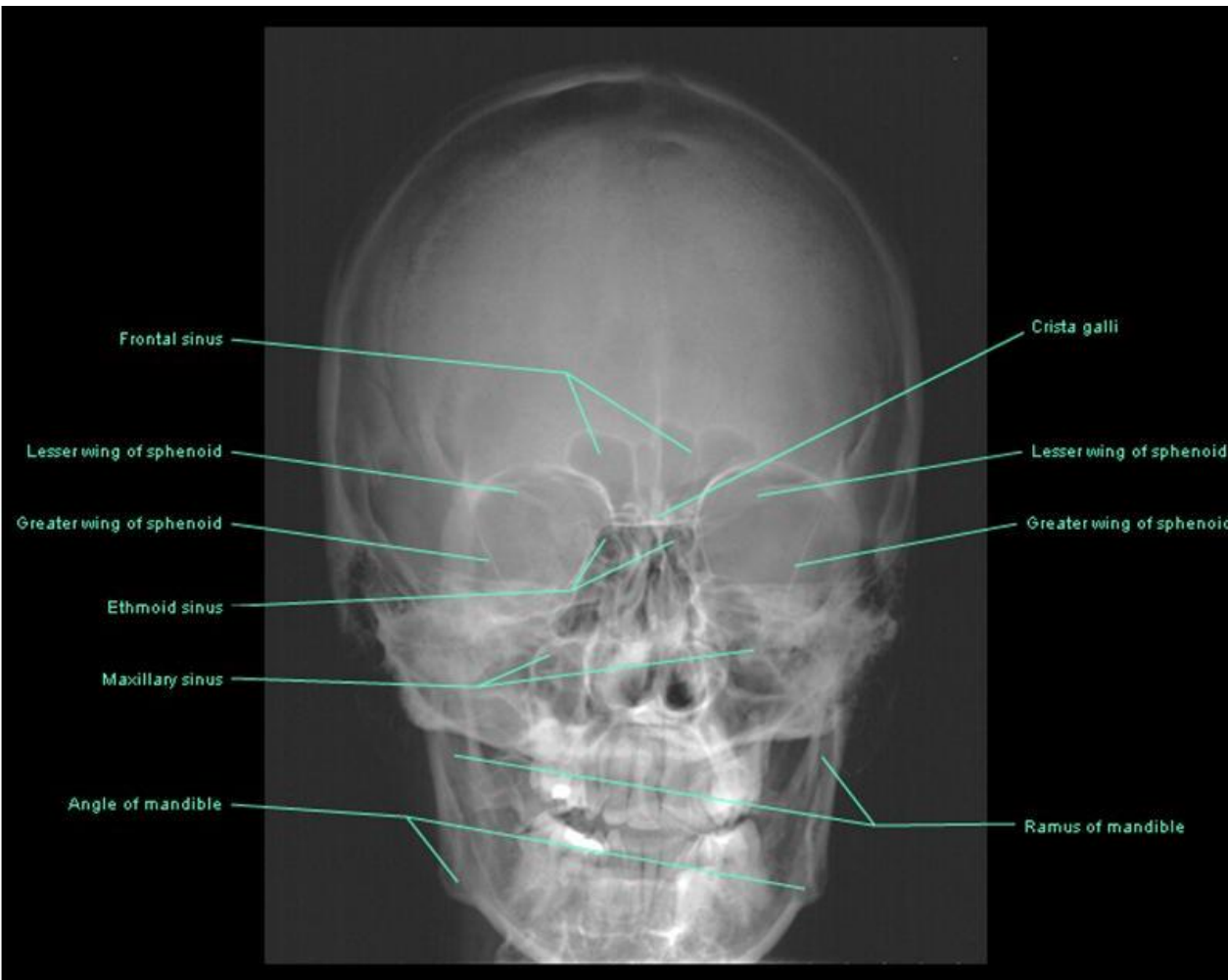


RADIO LUCENT

# Skull X-ray

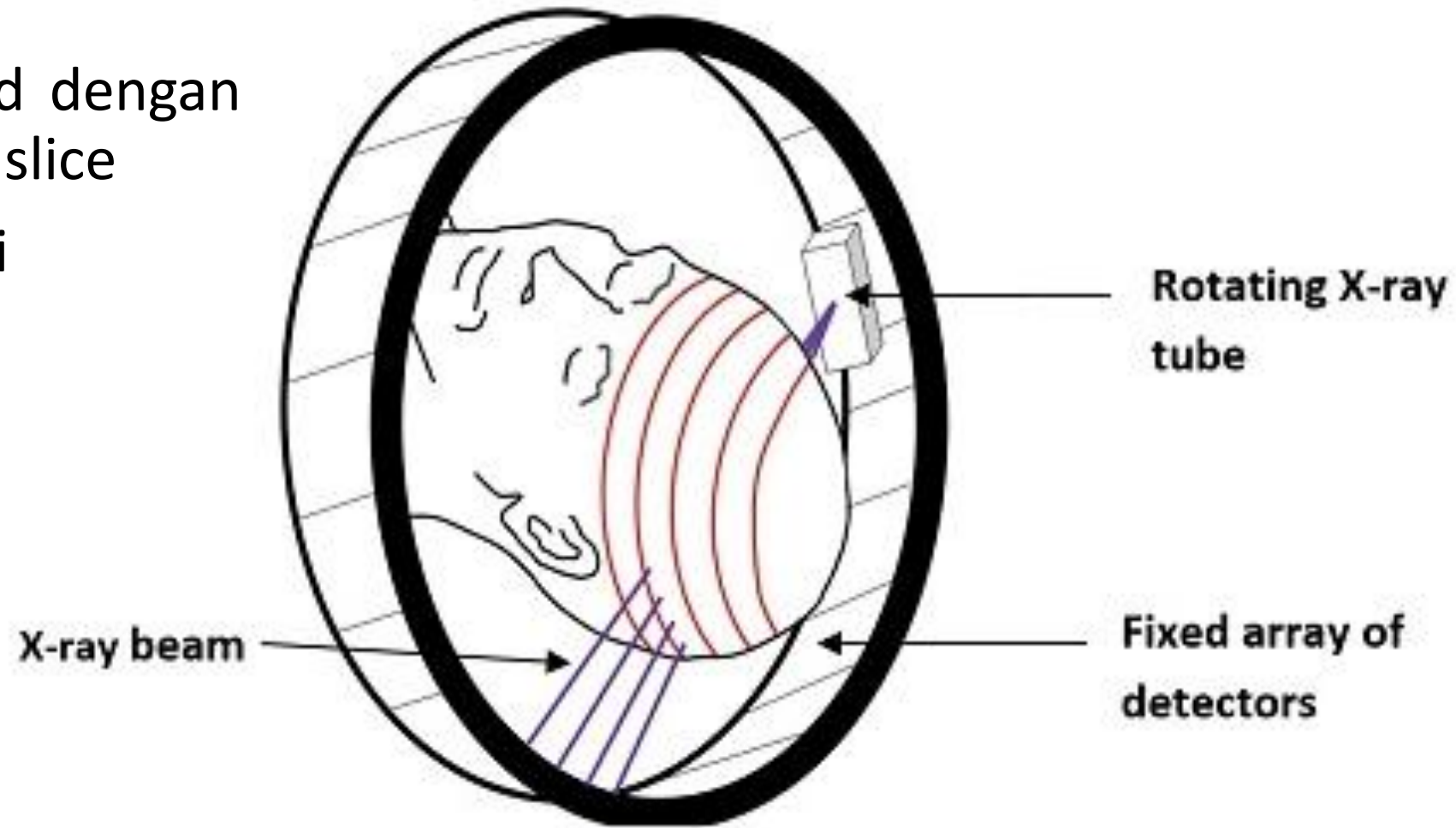
- Foto kepala atau skull biasanya dilakukan pada pasien post trauma capitis, pasien dicurigai kelainan pada sinus maupun mastoid.
- Foto skull jarang dilakukan pada pasien dengan kelainan saraf pusat
- Sudah ditinggalkan karena ada imaging lain seperti CT Scan dan MRI





# CT Scan

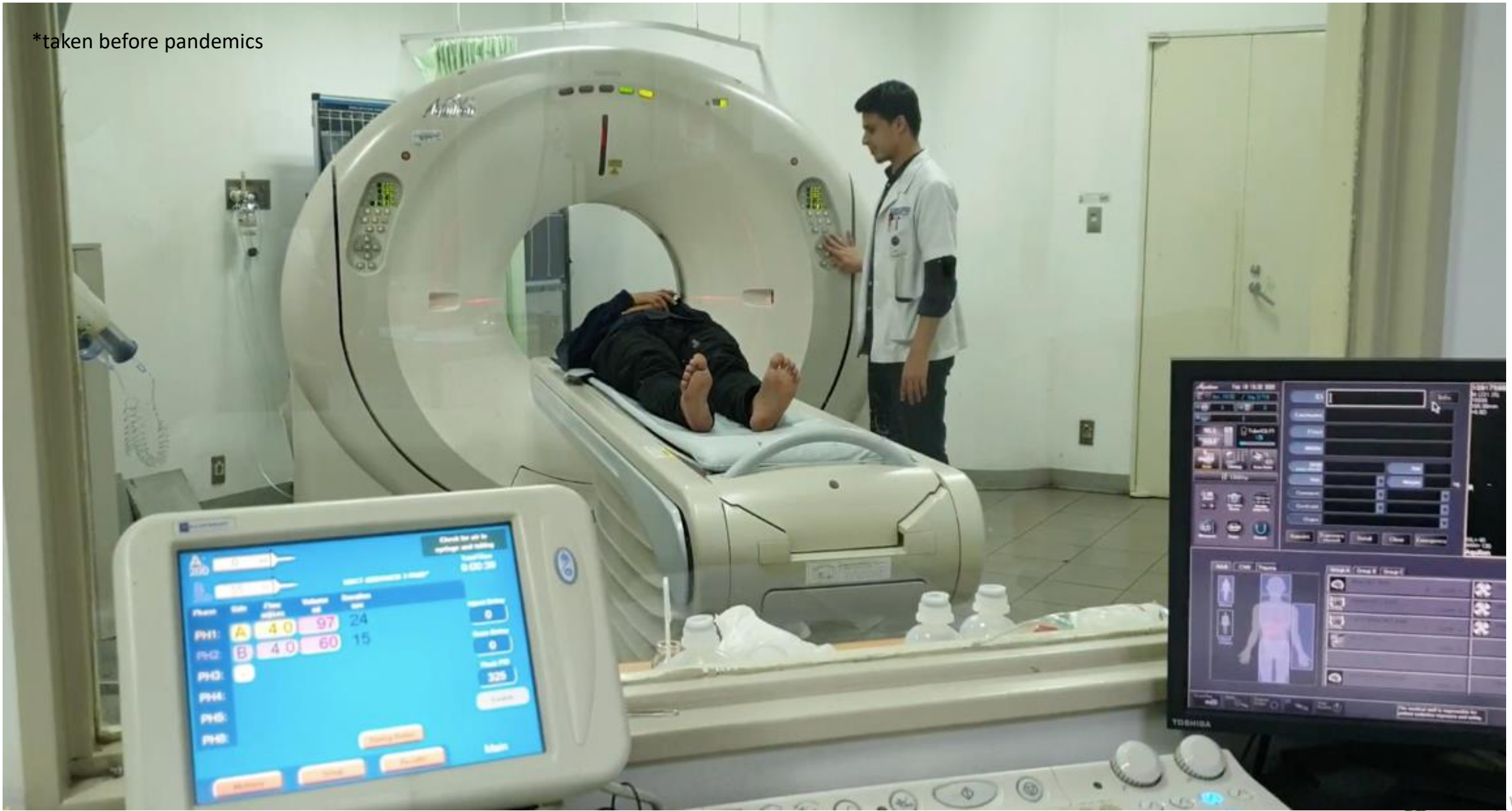- Imaging x ray based dengan multipel potongan/ slice
- Bisa 3D rekonstruksi



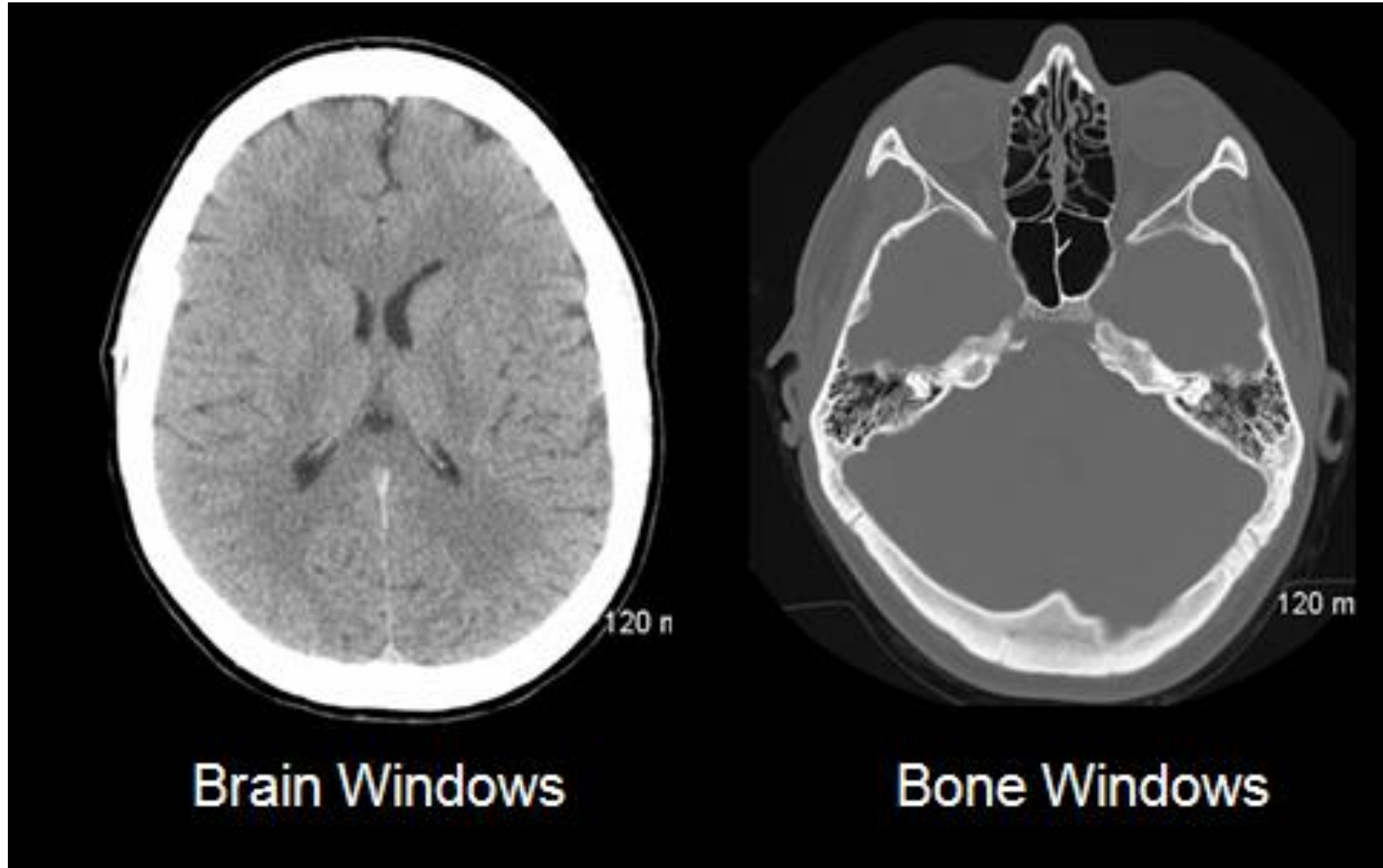
\*taken before pandemics

yang diproyeksikan terhadap target organ tubuh  
secara berputar dan terus menerus

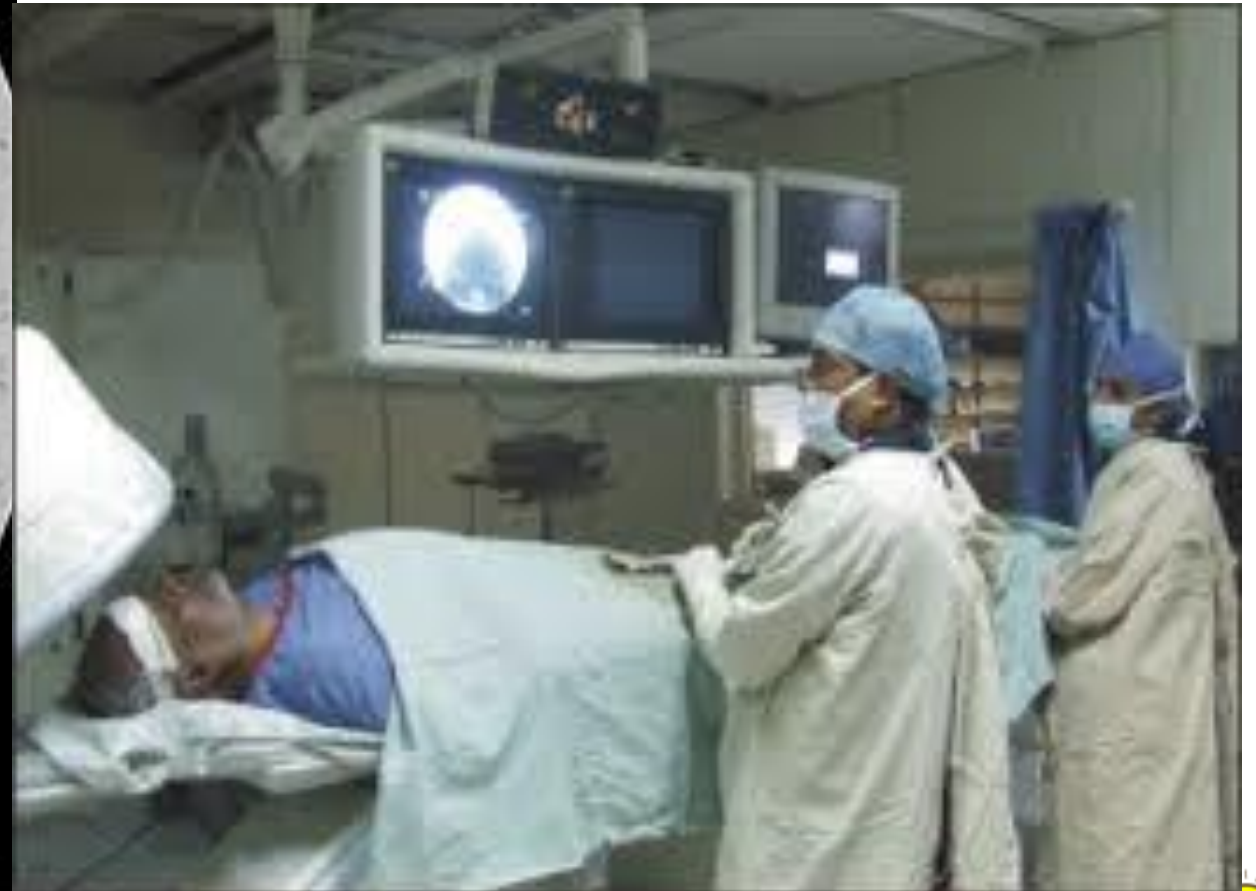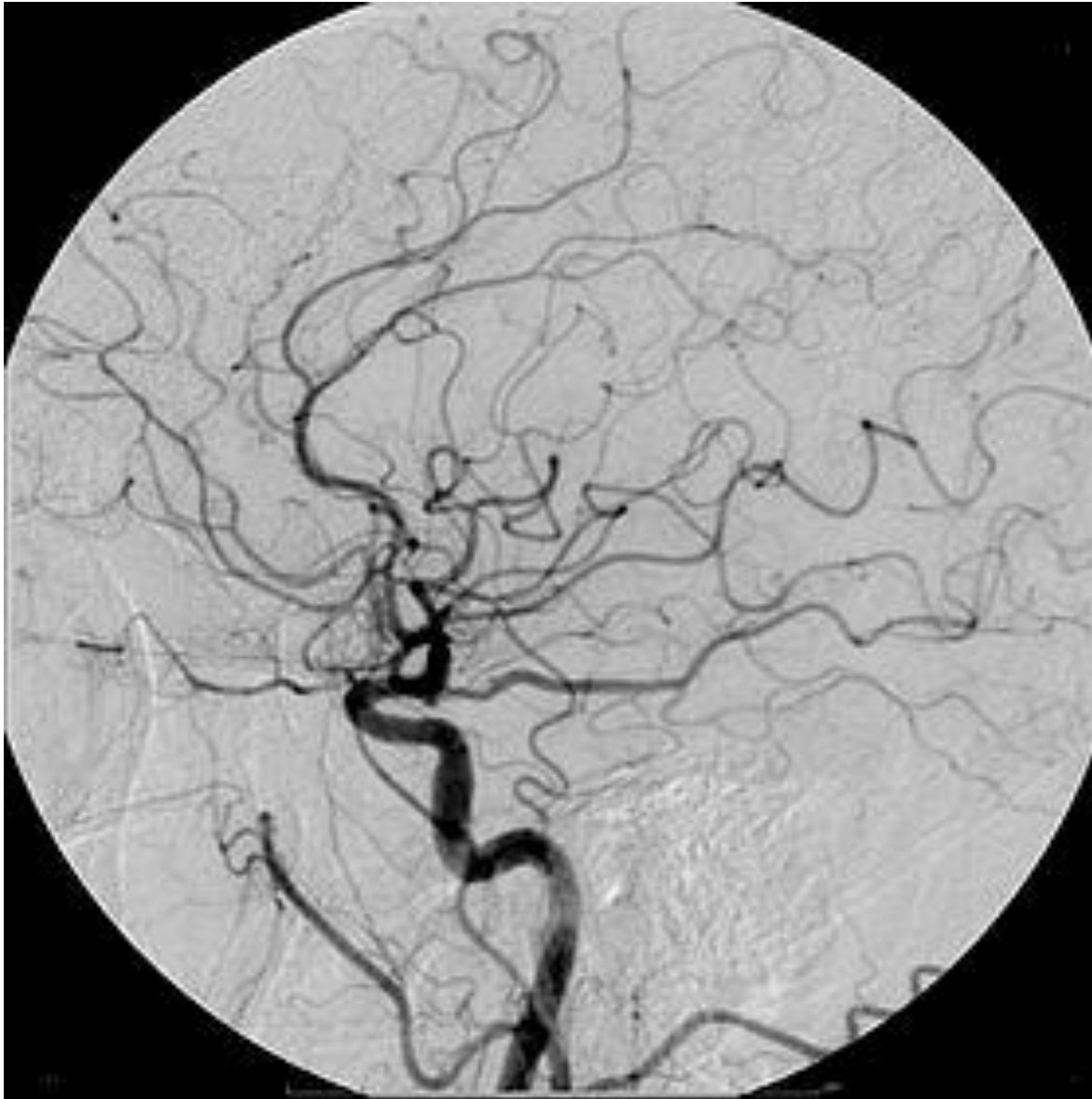
\*taken before pandemics

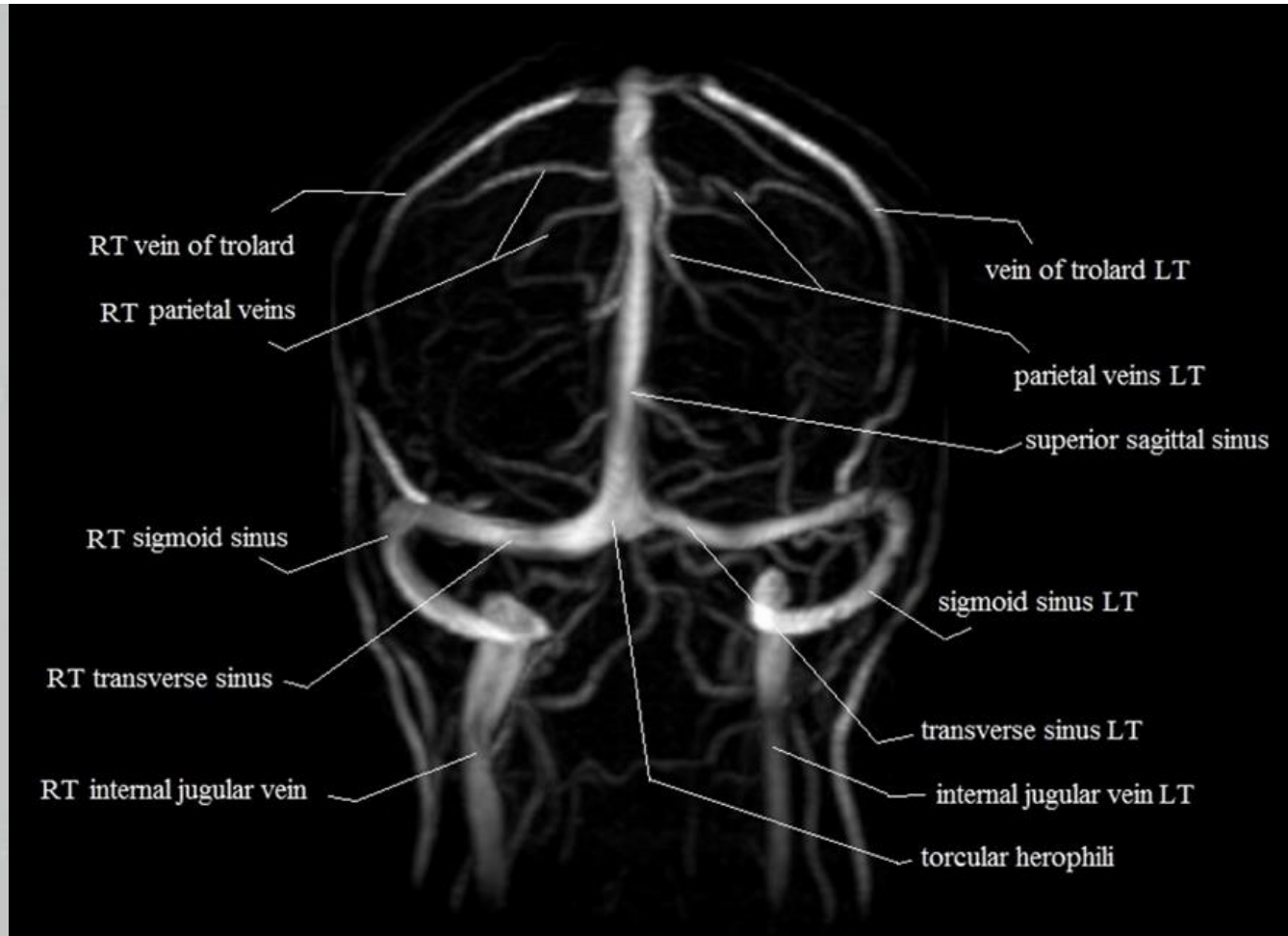
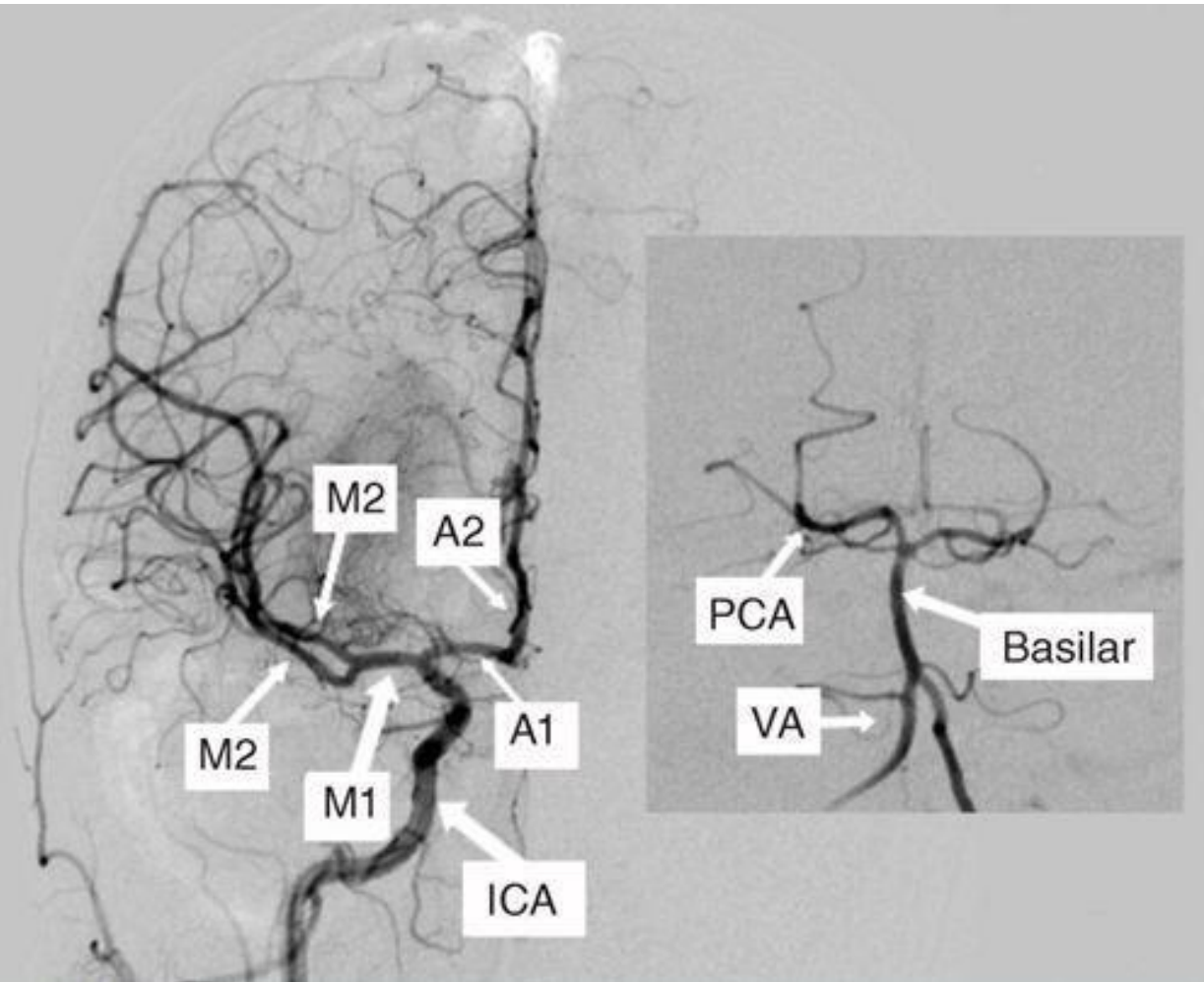


# Brain window vs Bone Window



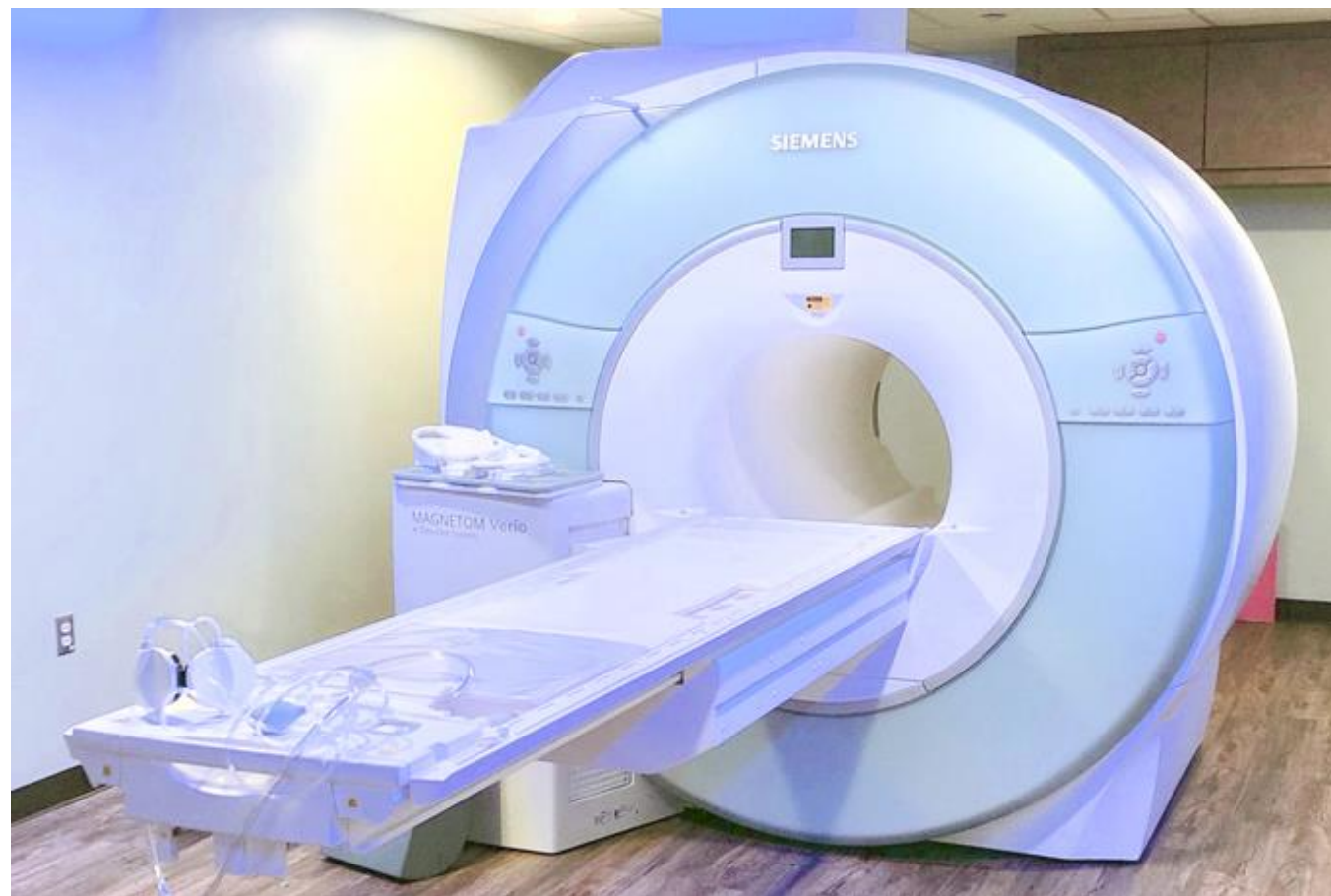# Digital Subtraction Angiography (DSA)

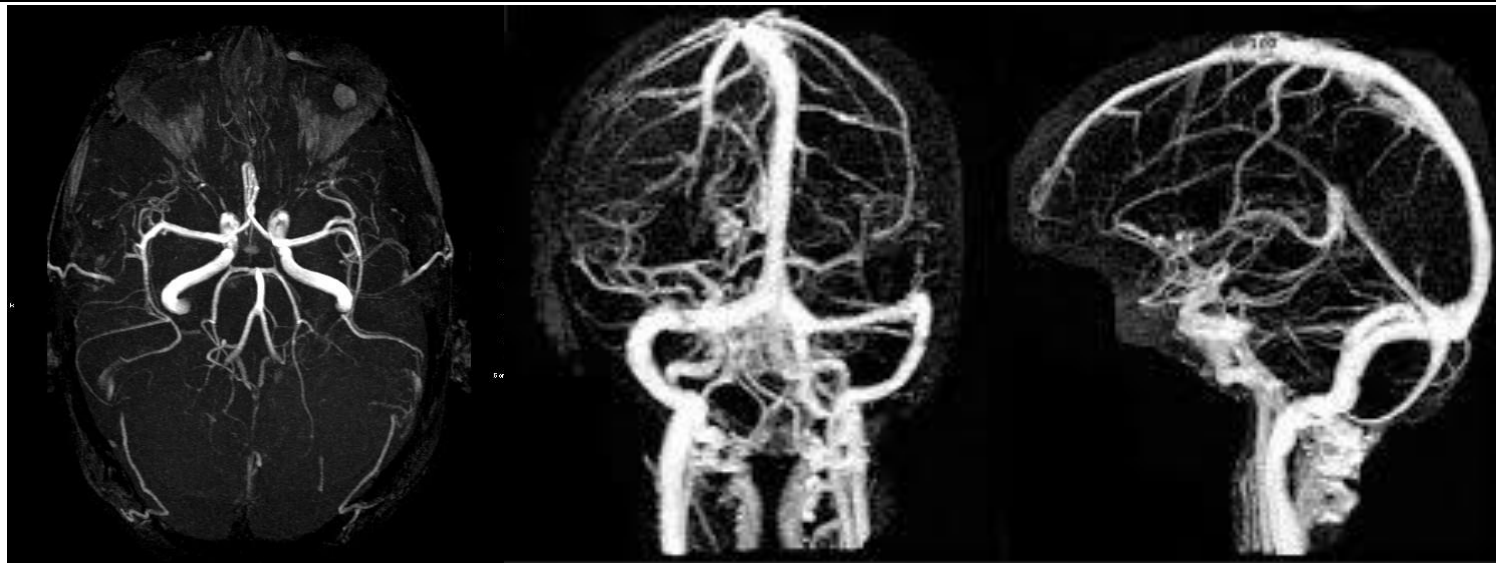
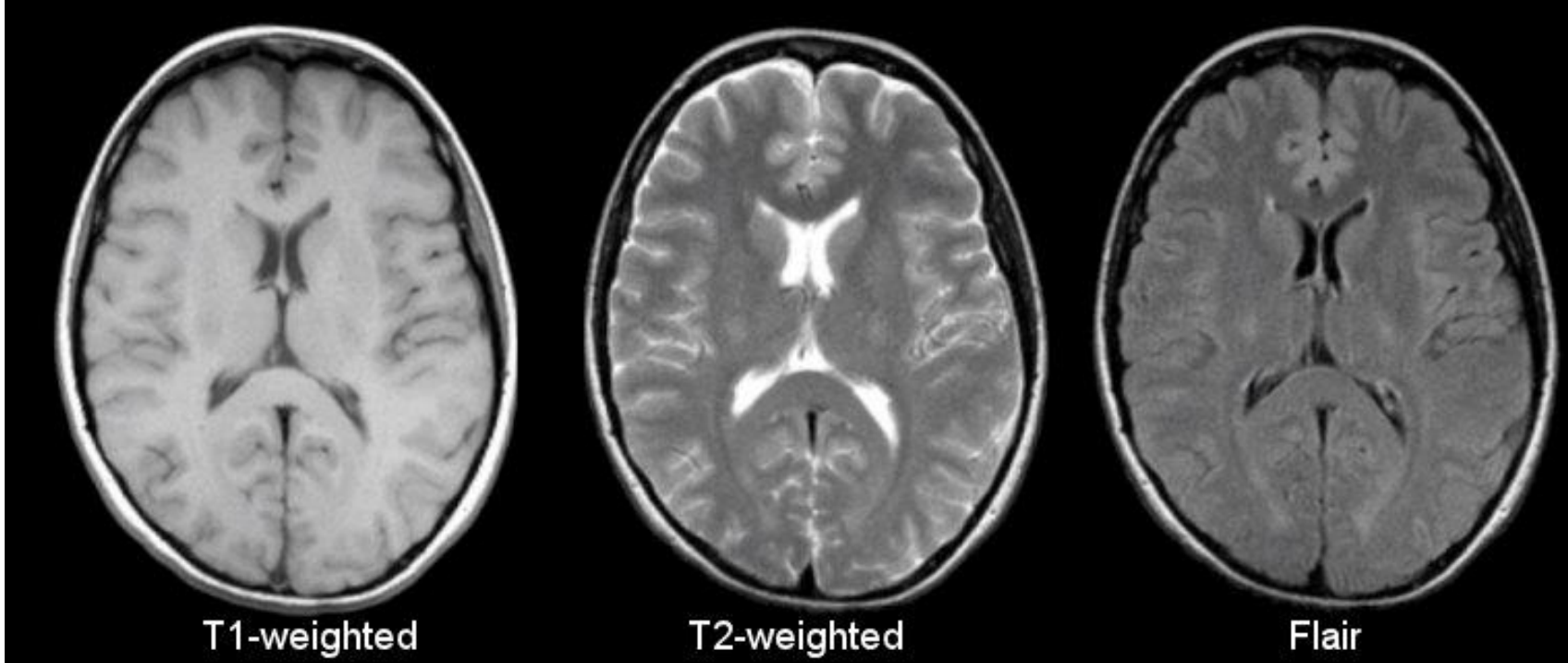




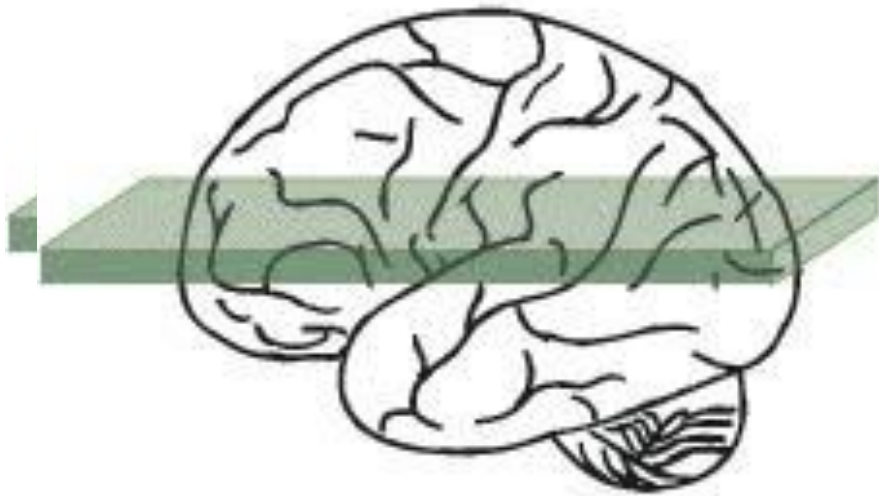
# MRI (Magnetic Resonance Imaging)

- Menggunakan medan magnet
- Baik dalam mengevaluasi soft tissue

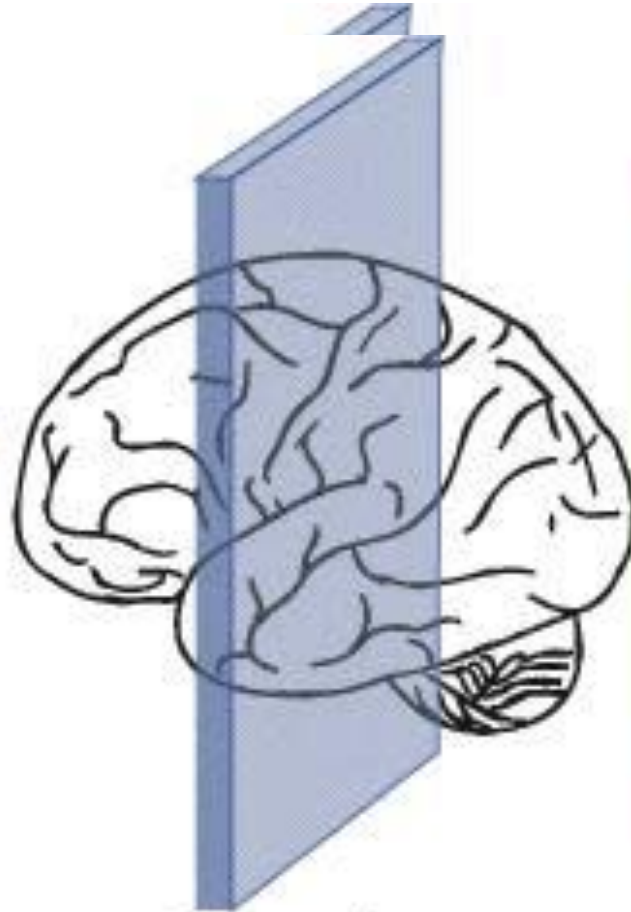




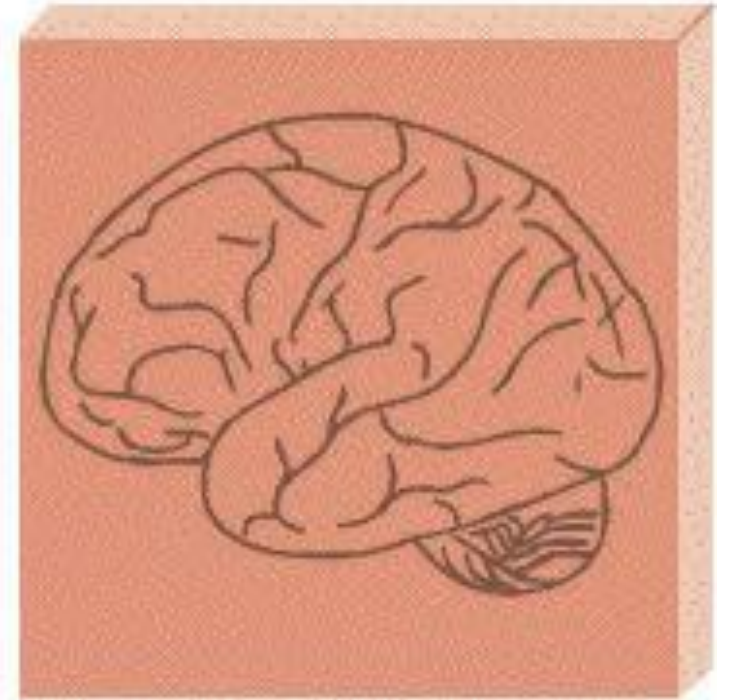## 2. Jenis potongan dalam pemeriksaan imaging



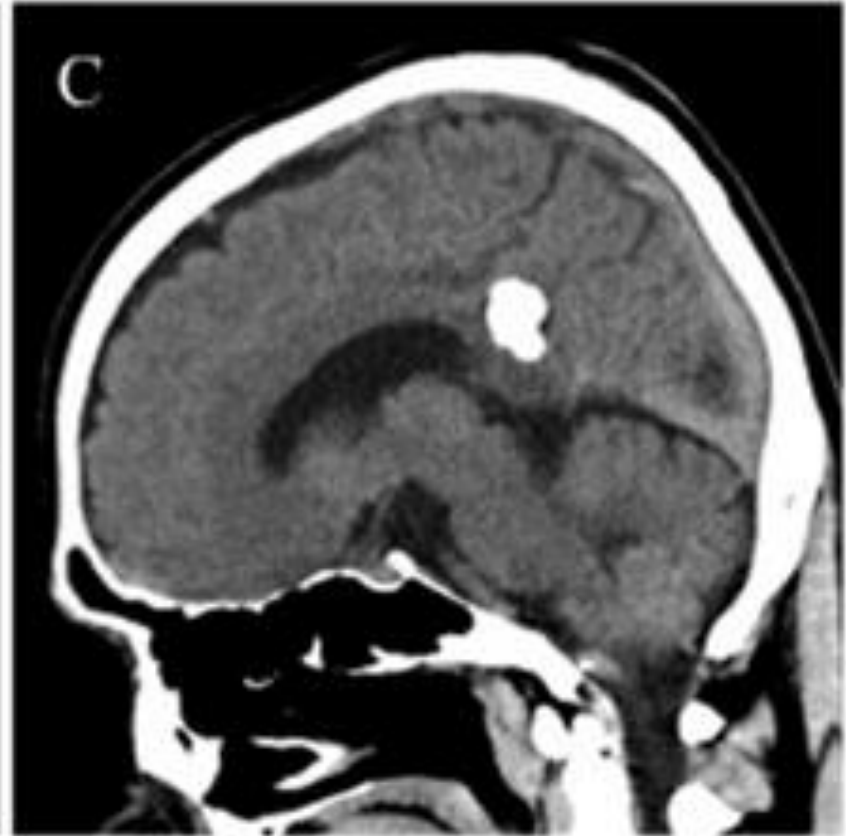
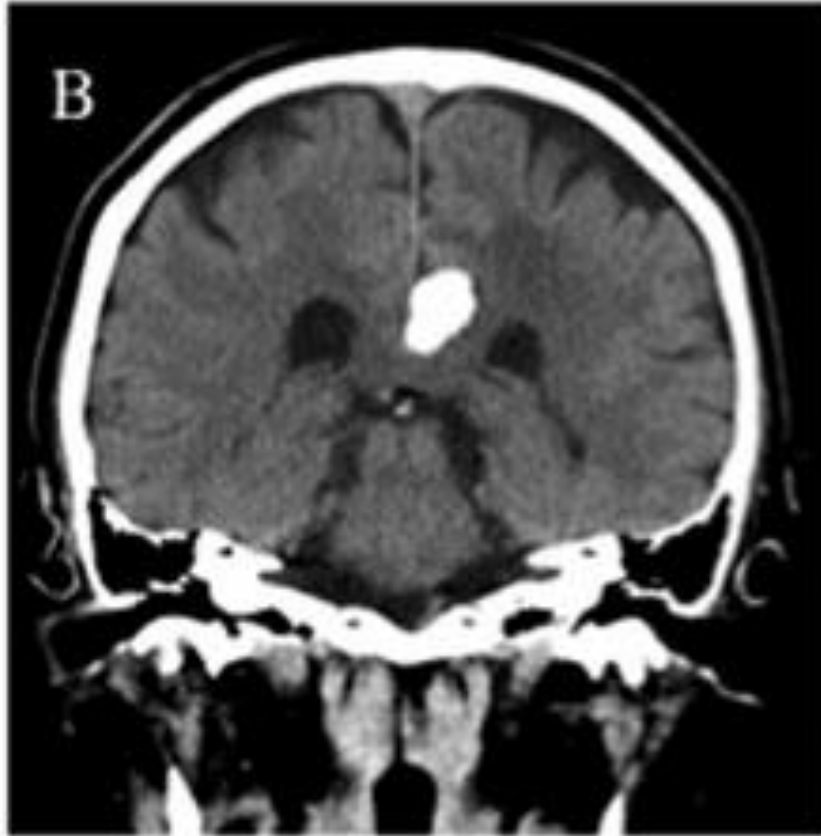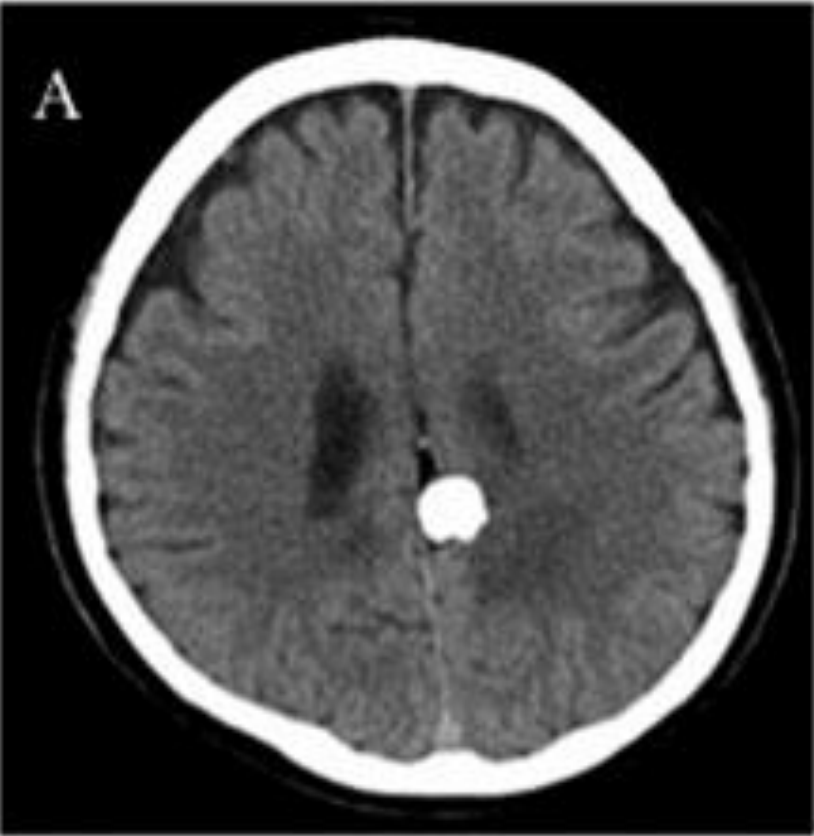Axial



Coronal

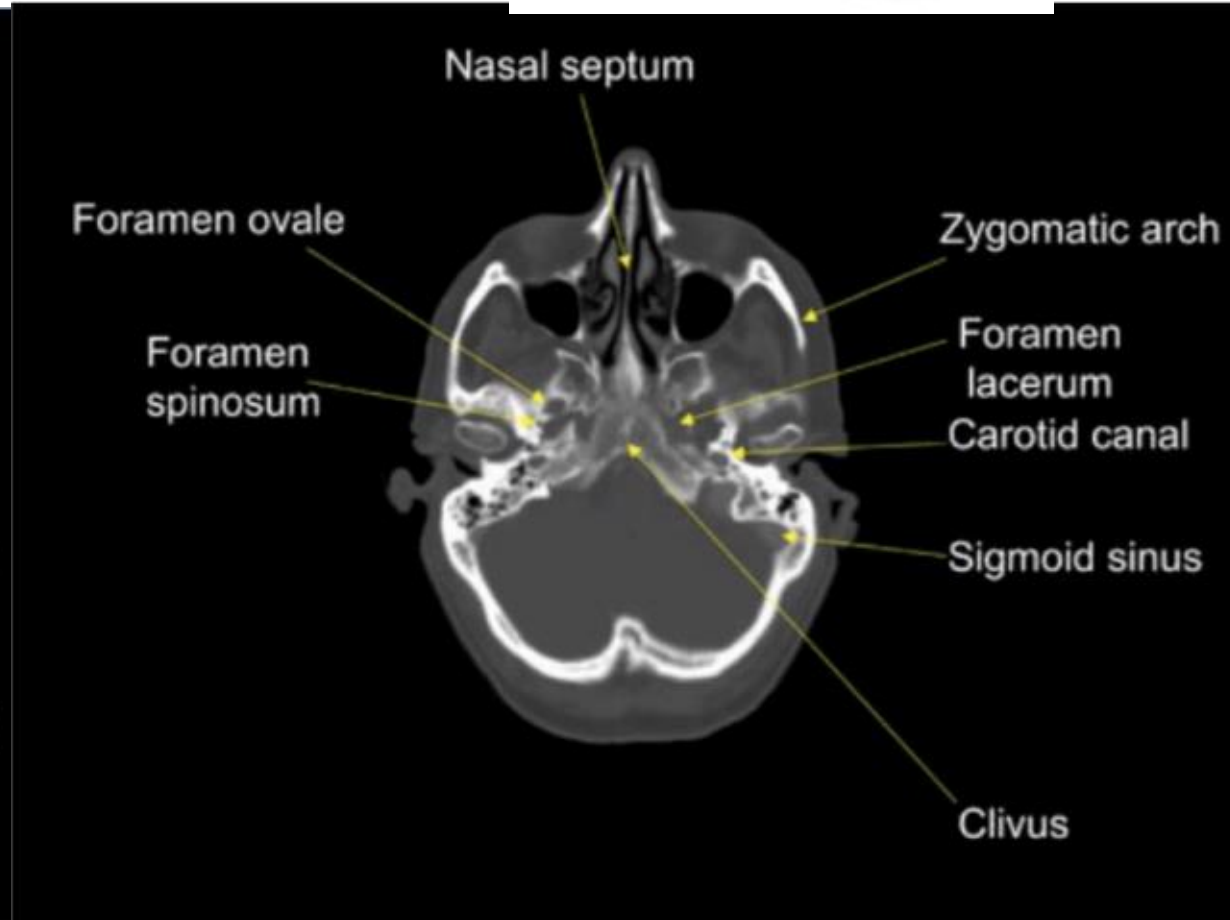
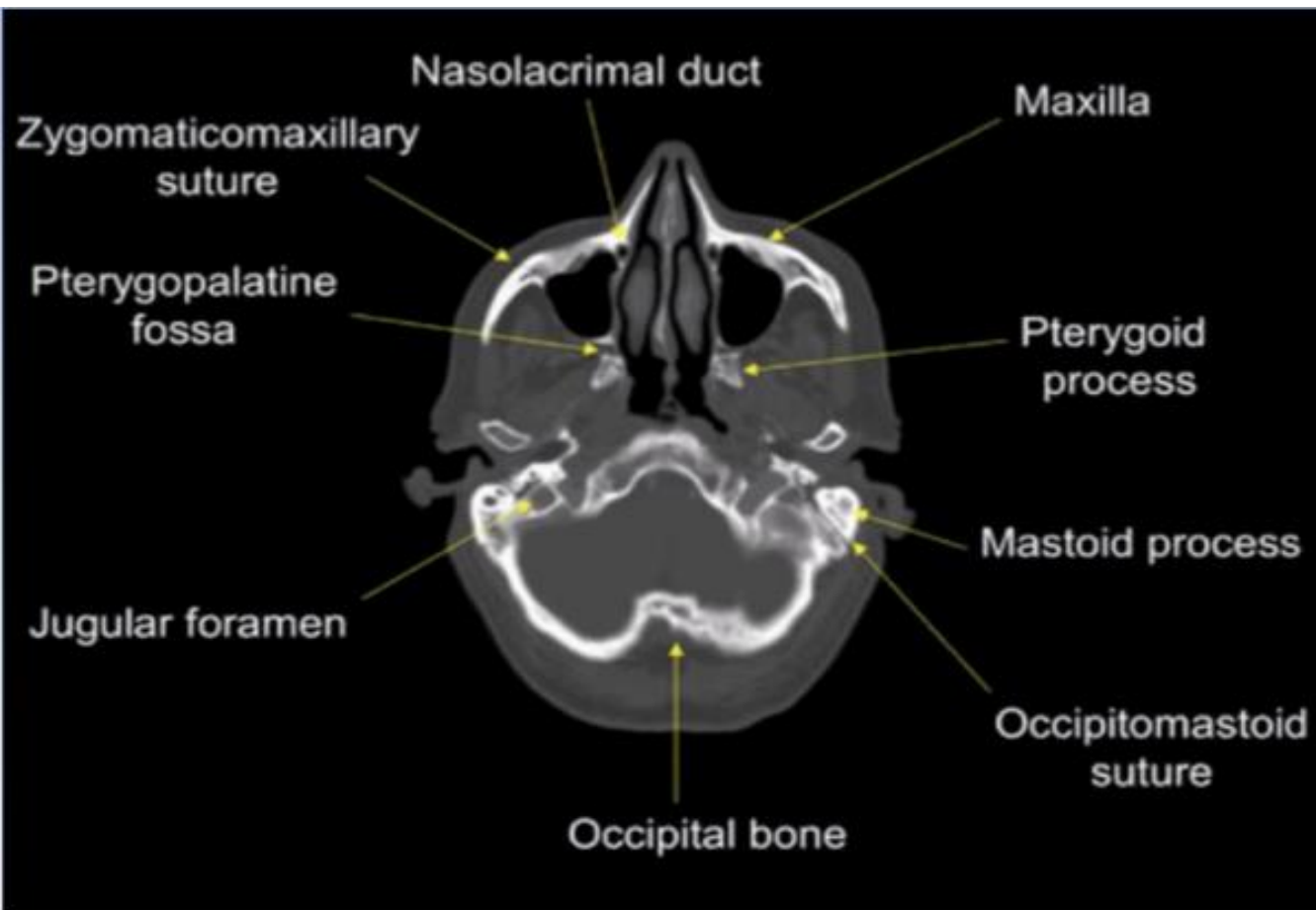
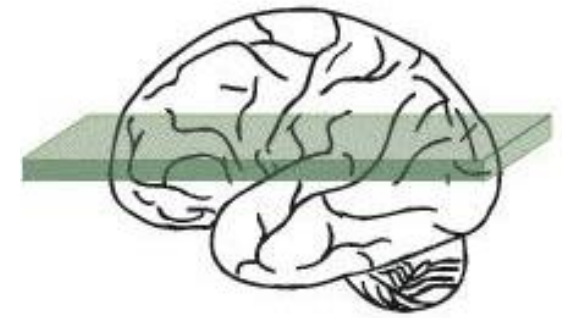


Sagittal

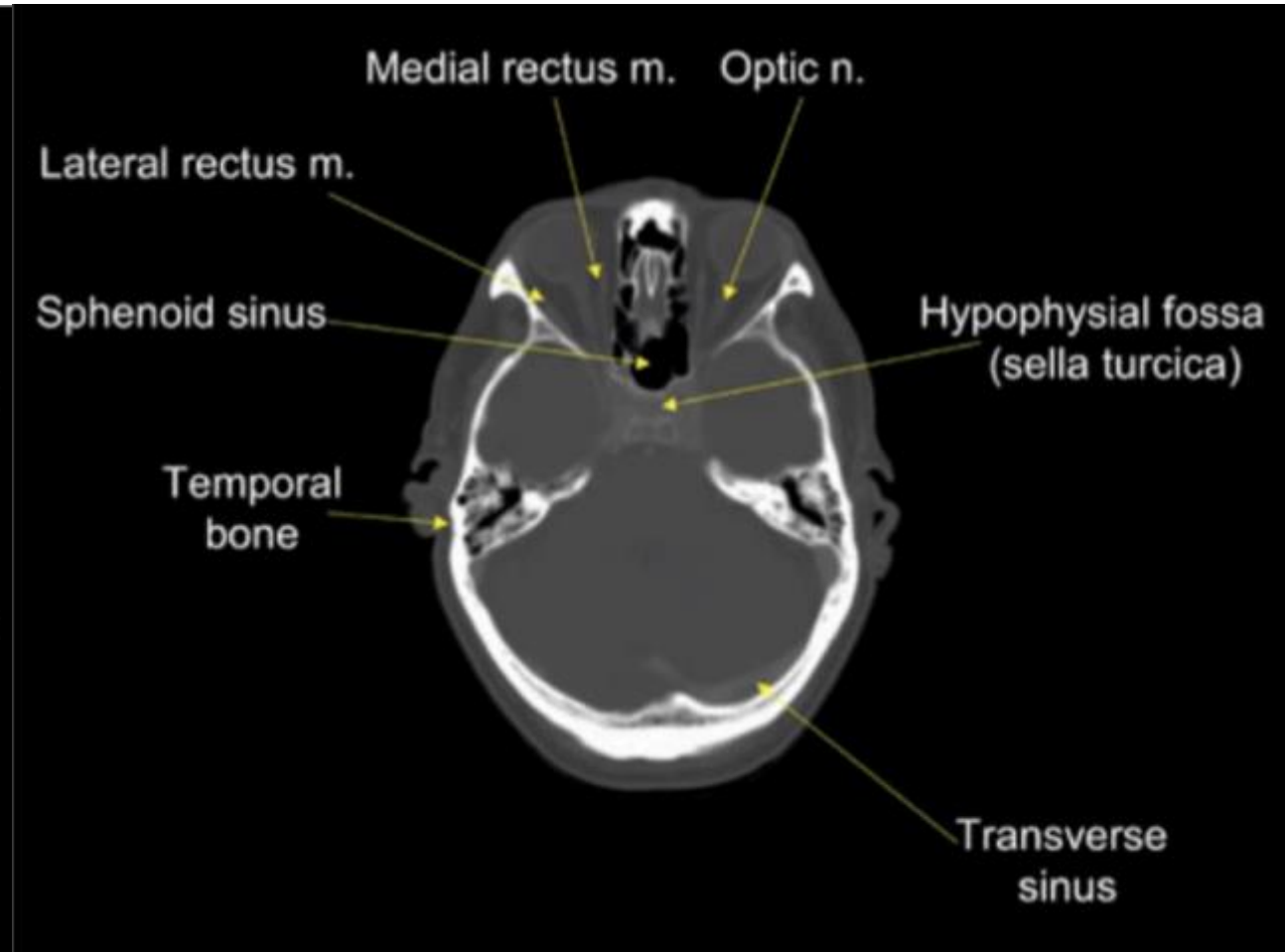
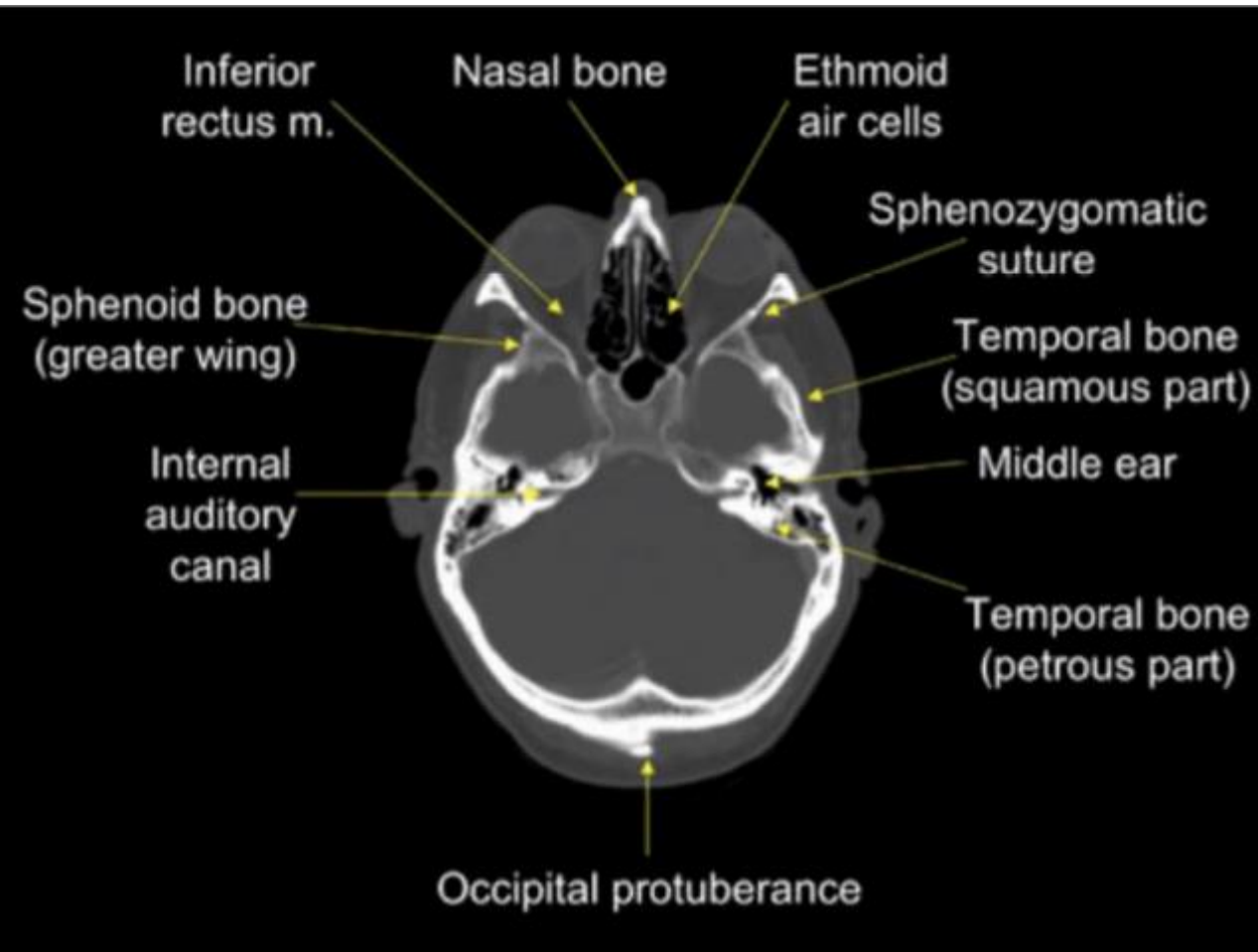
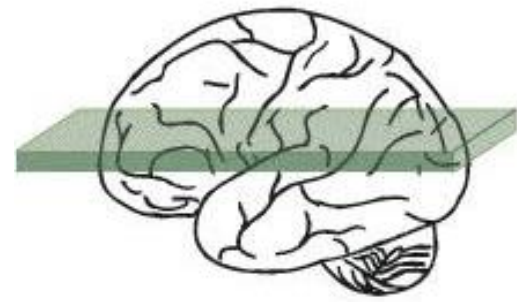


# 3. Gambaran normal CT Scan

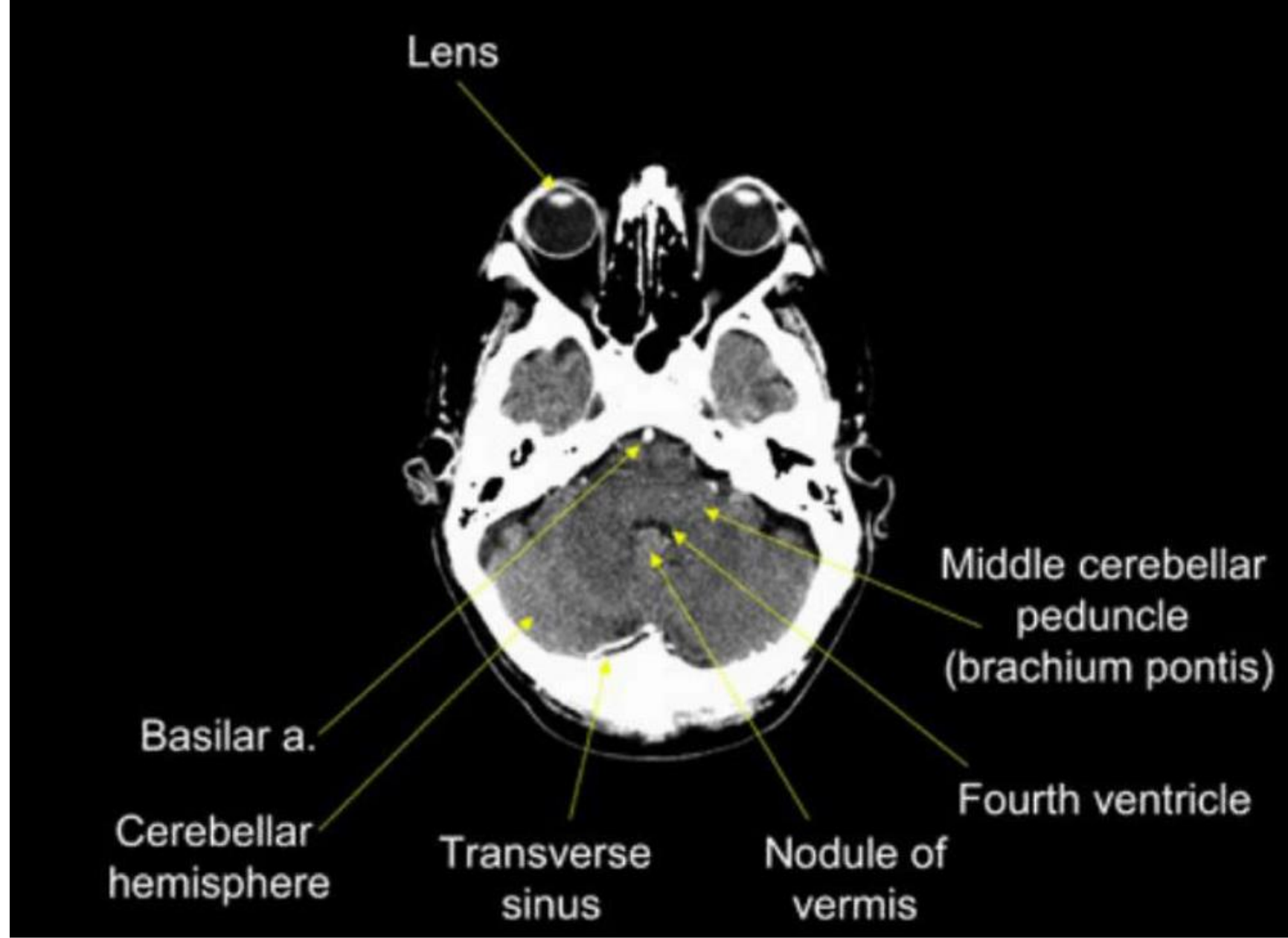
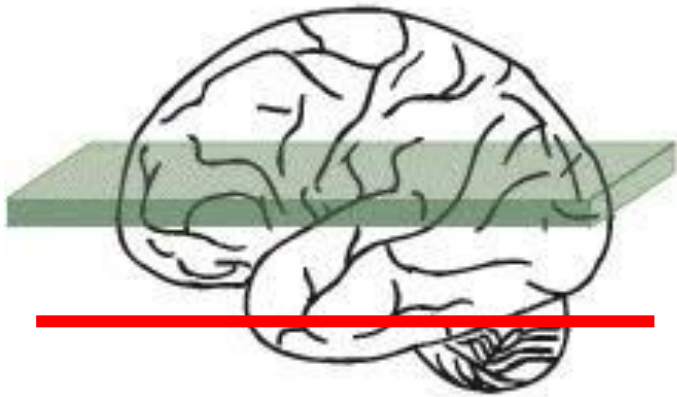
# Bone Window



# Bone Window

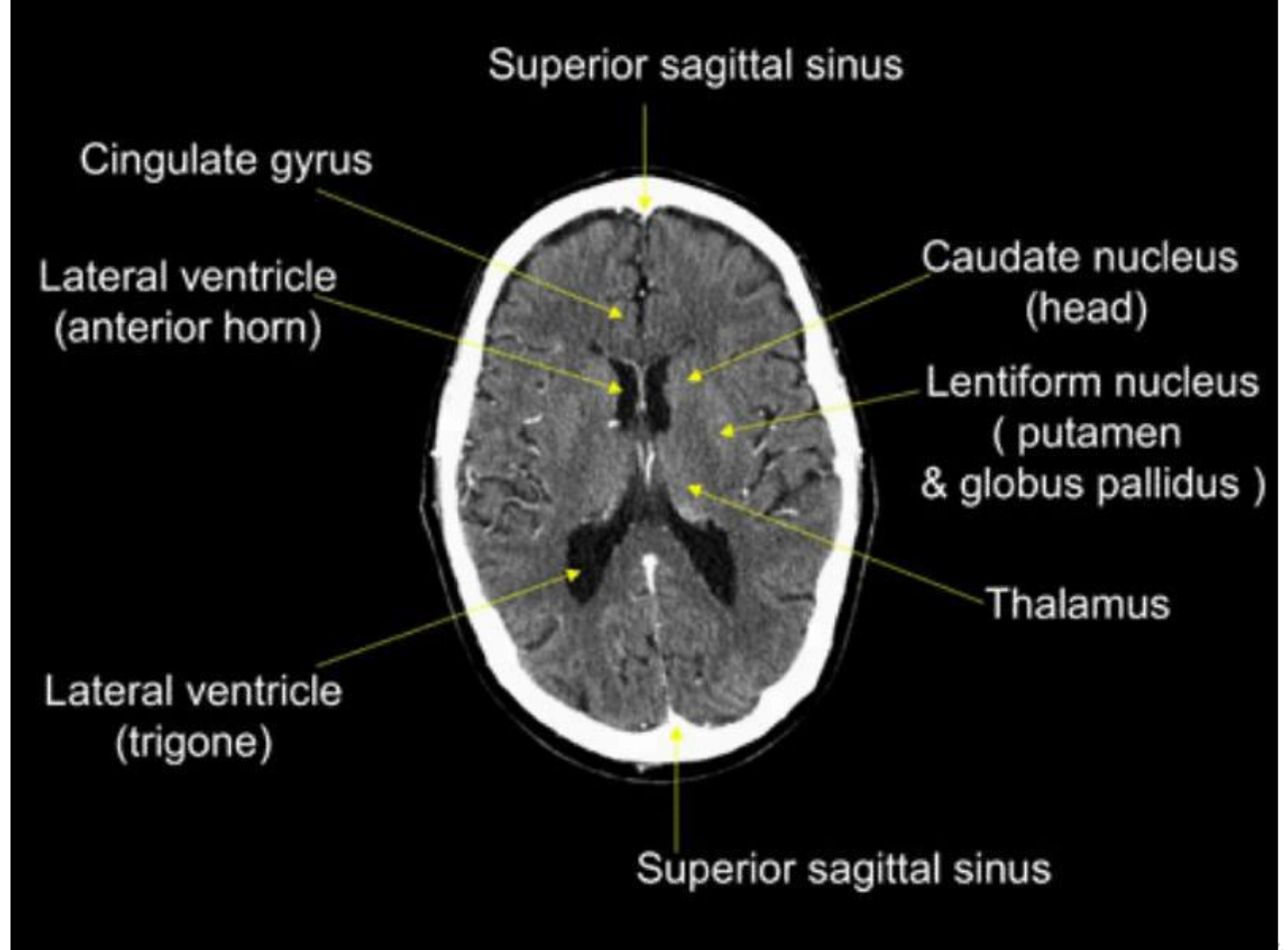
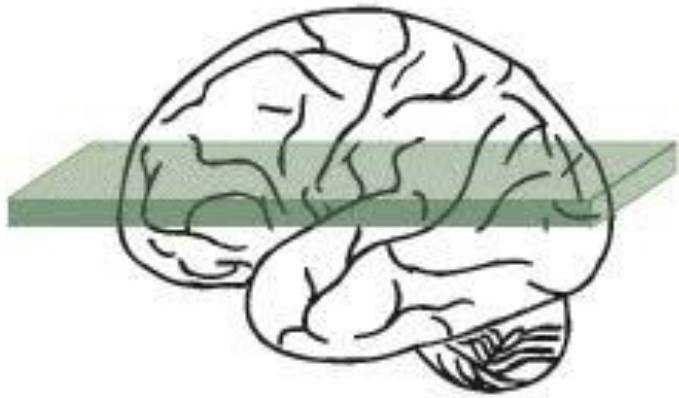


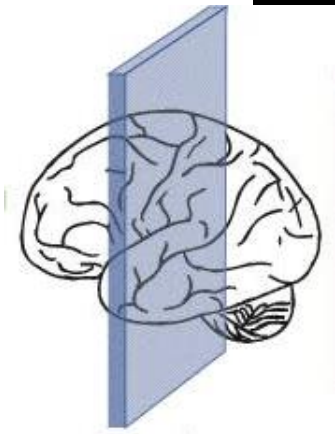
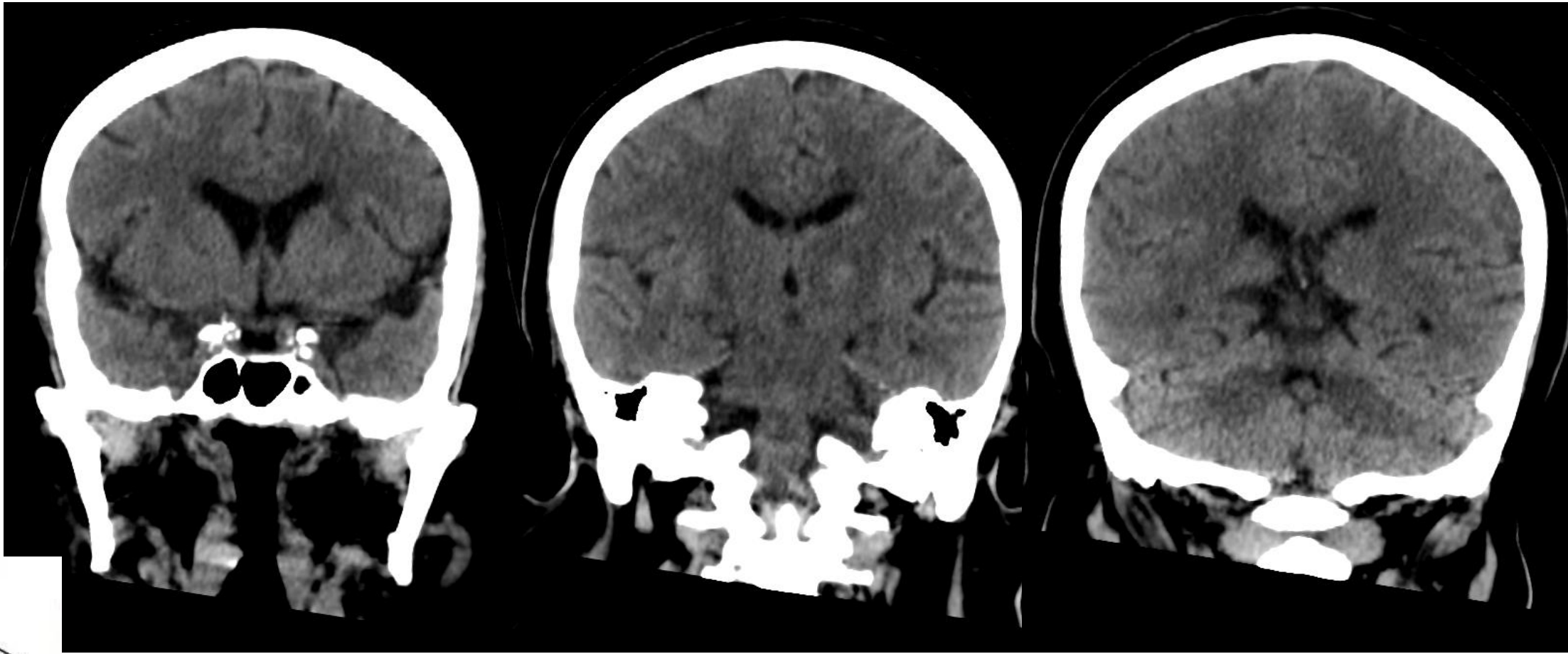
# Cerebellum



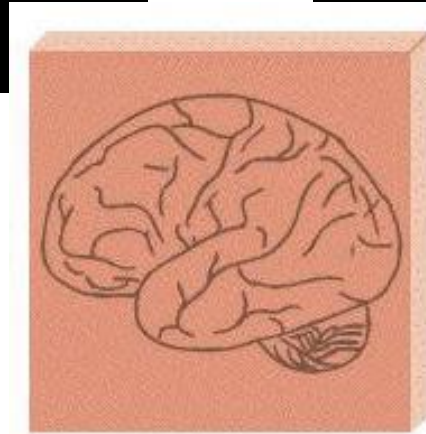
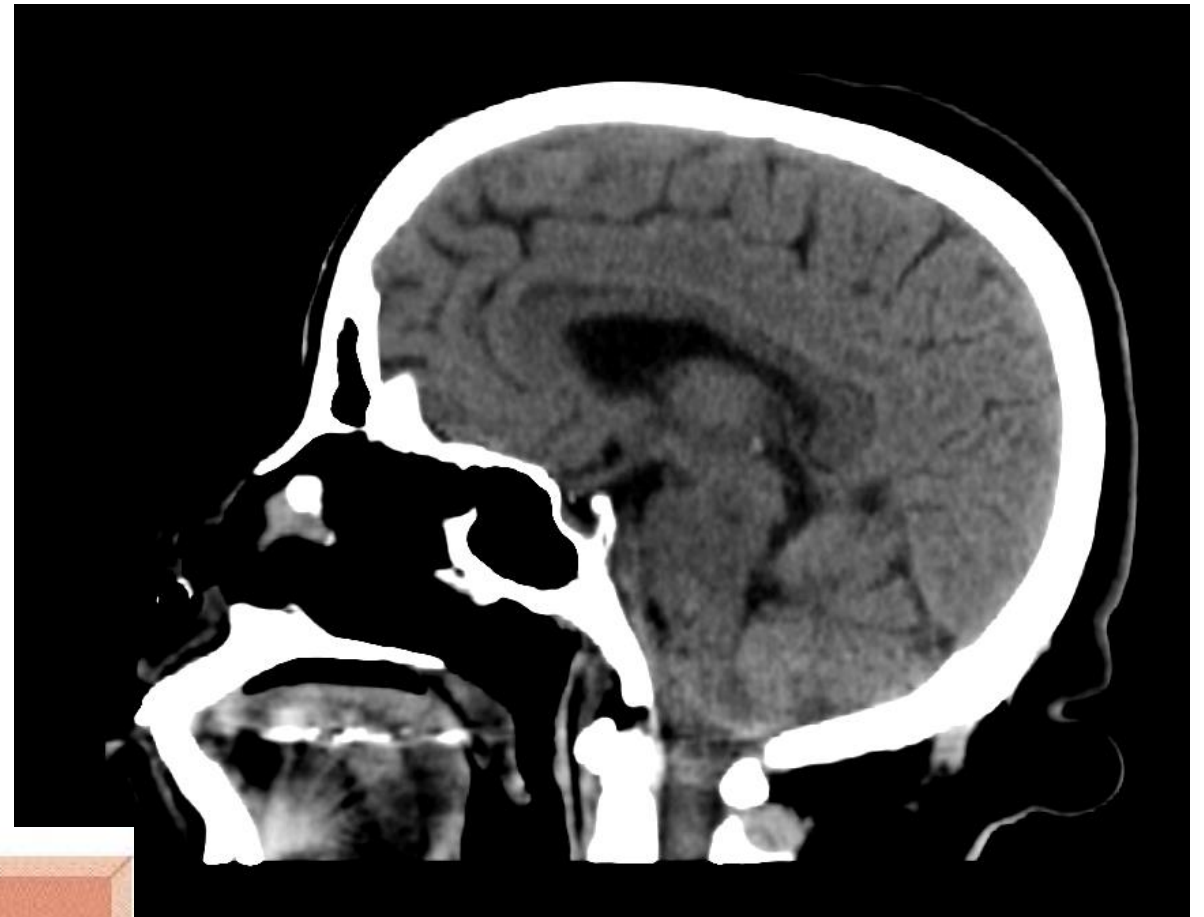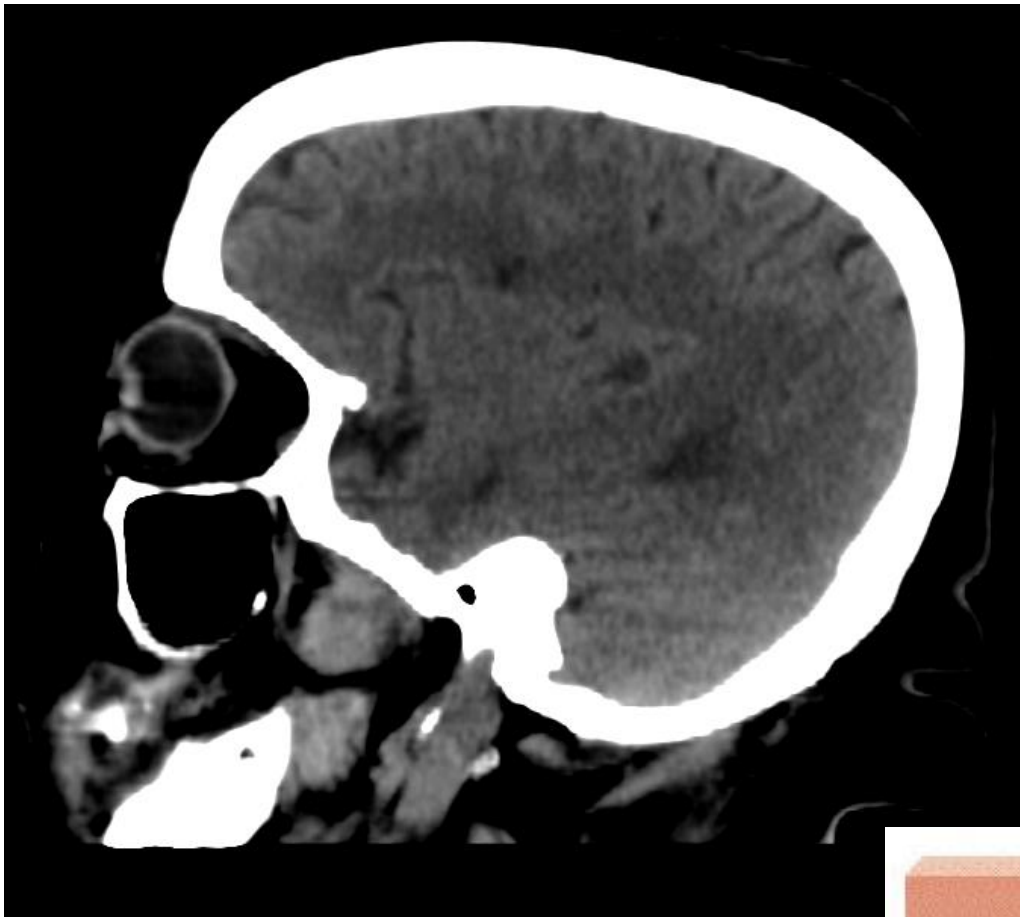# Identifikasi !

1. ventrikel
2. sulcus
3. MLS



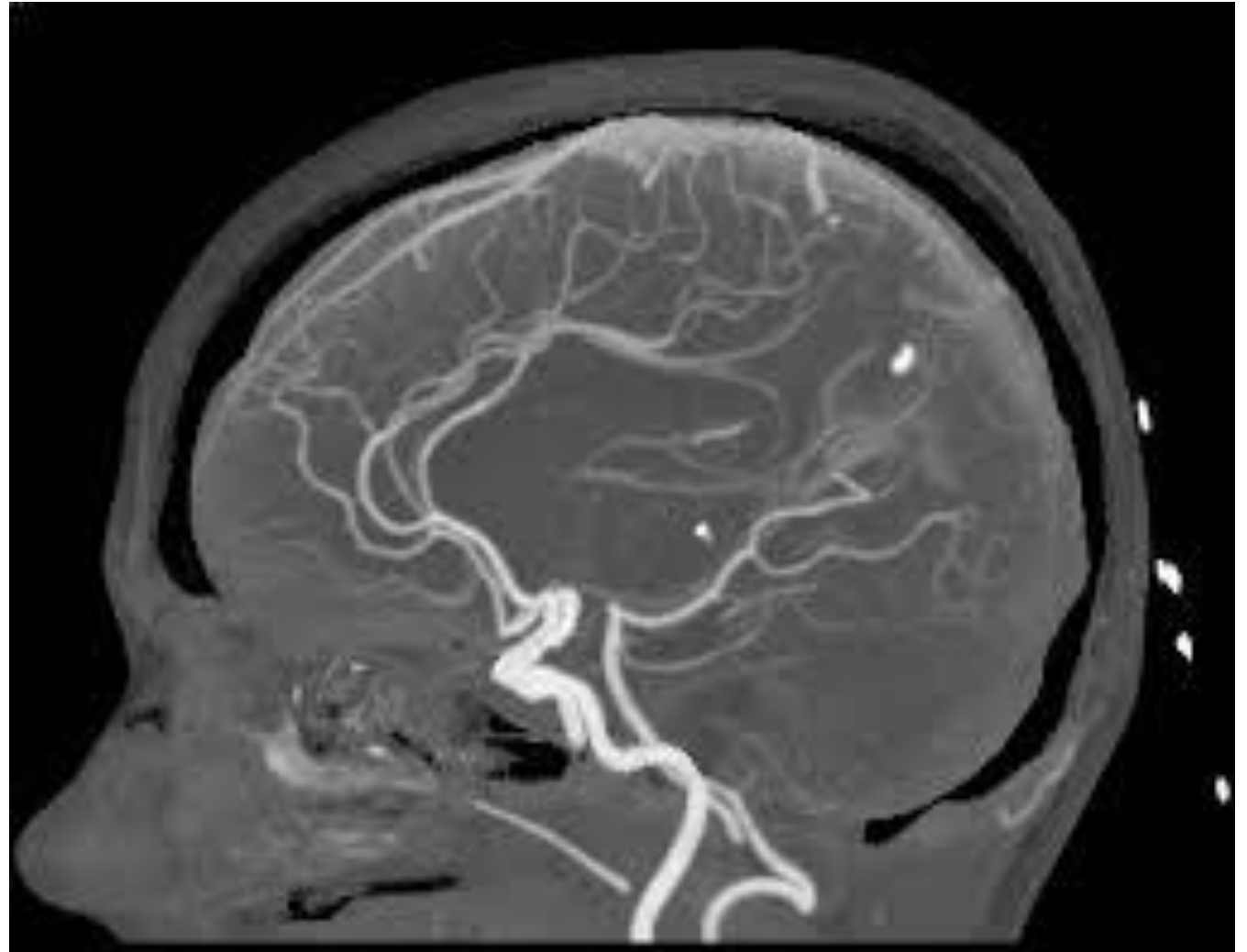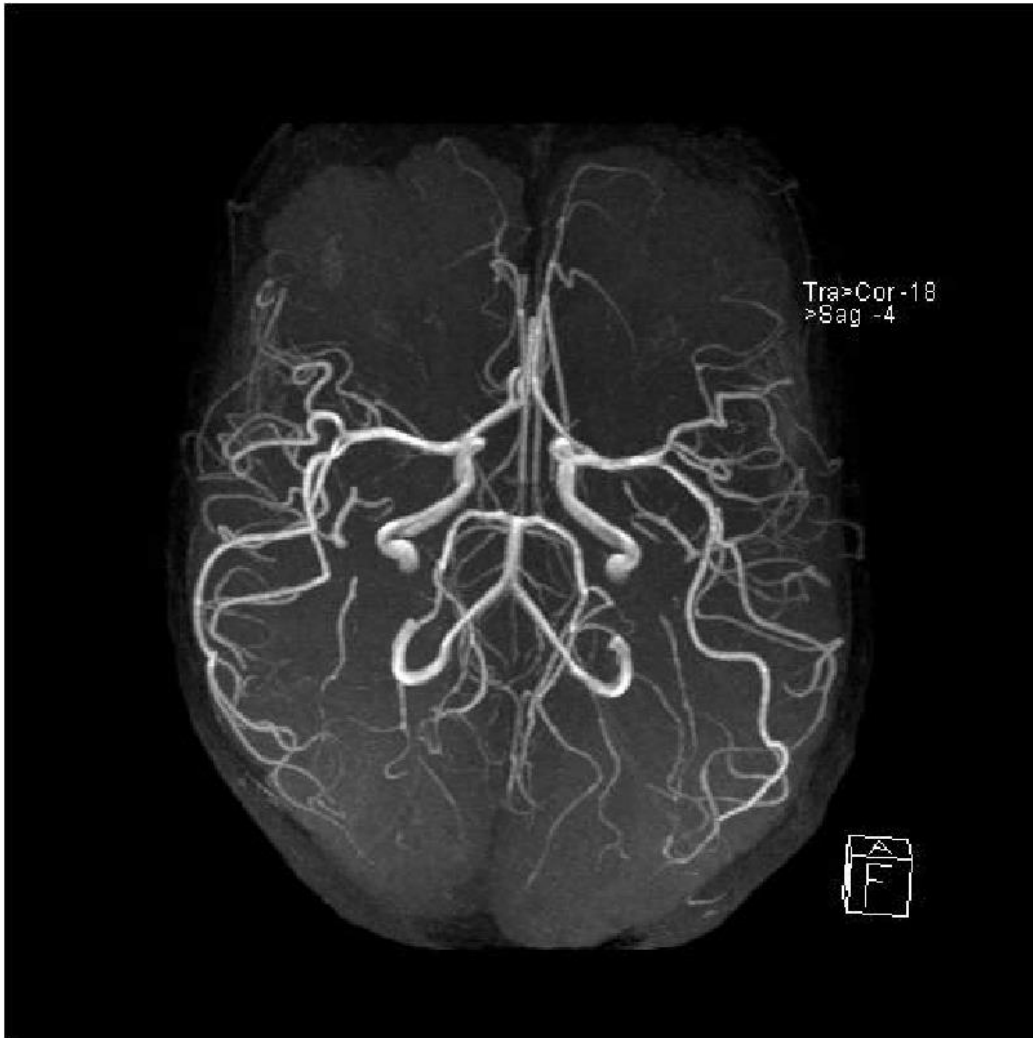


# Coronal

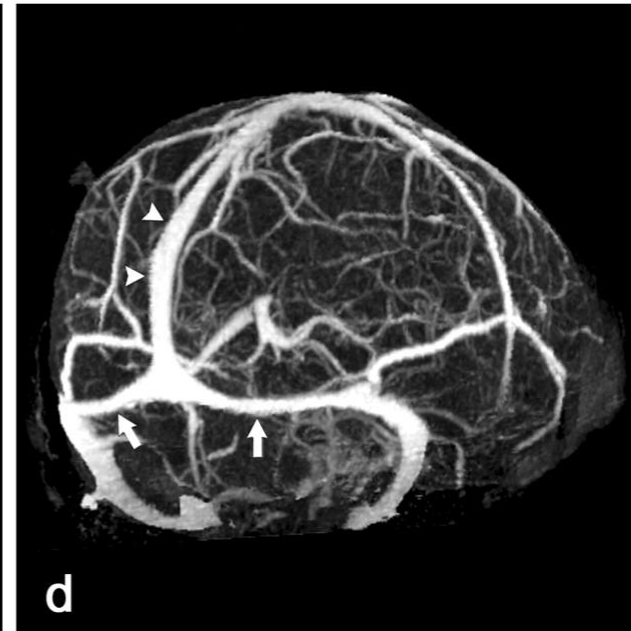
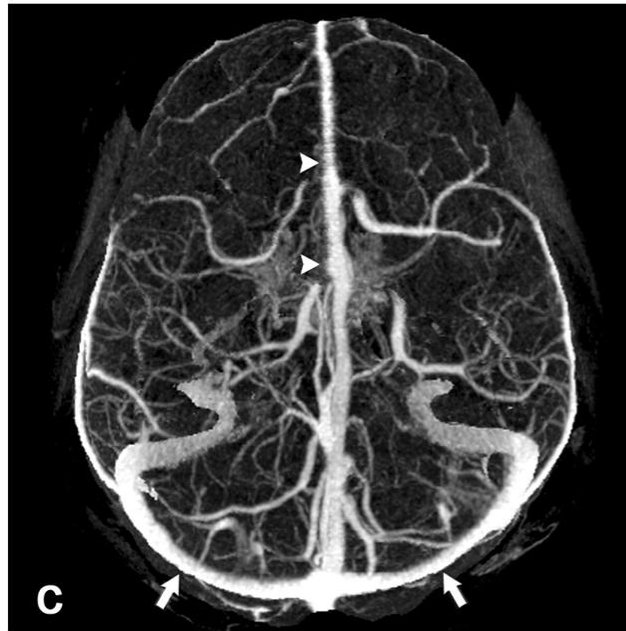
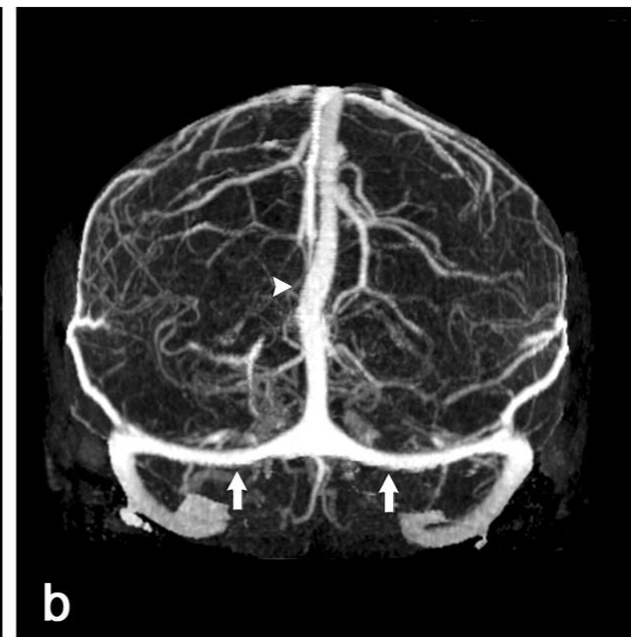
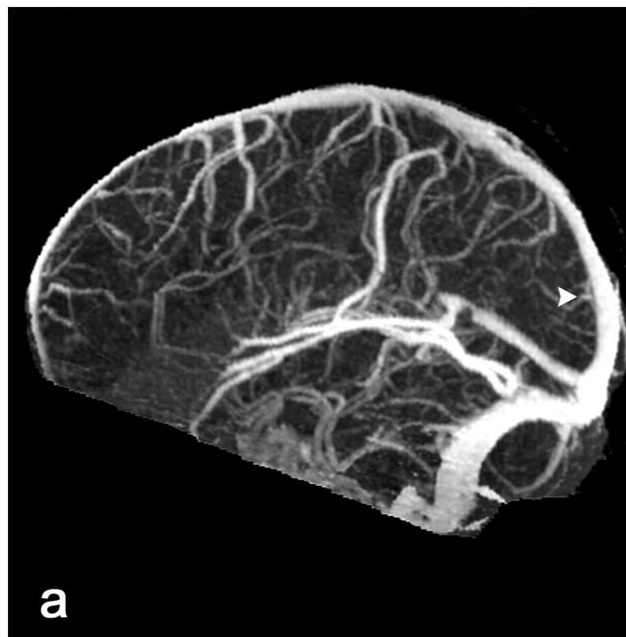


Sagittal

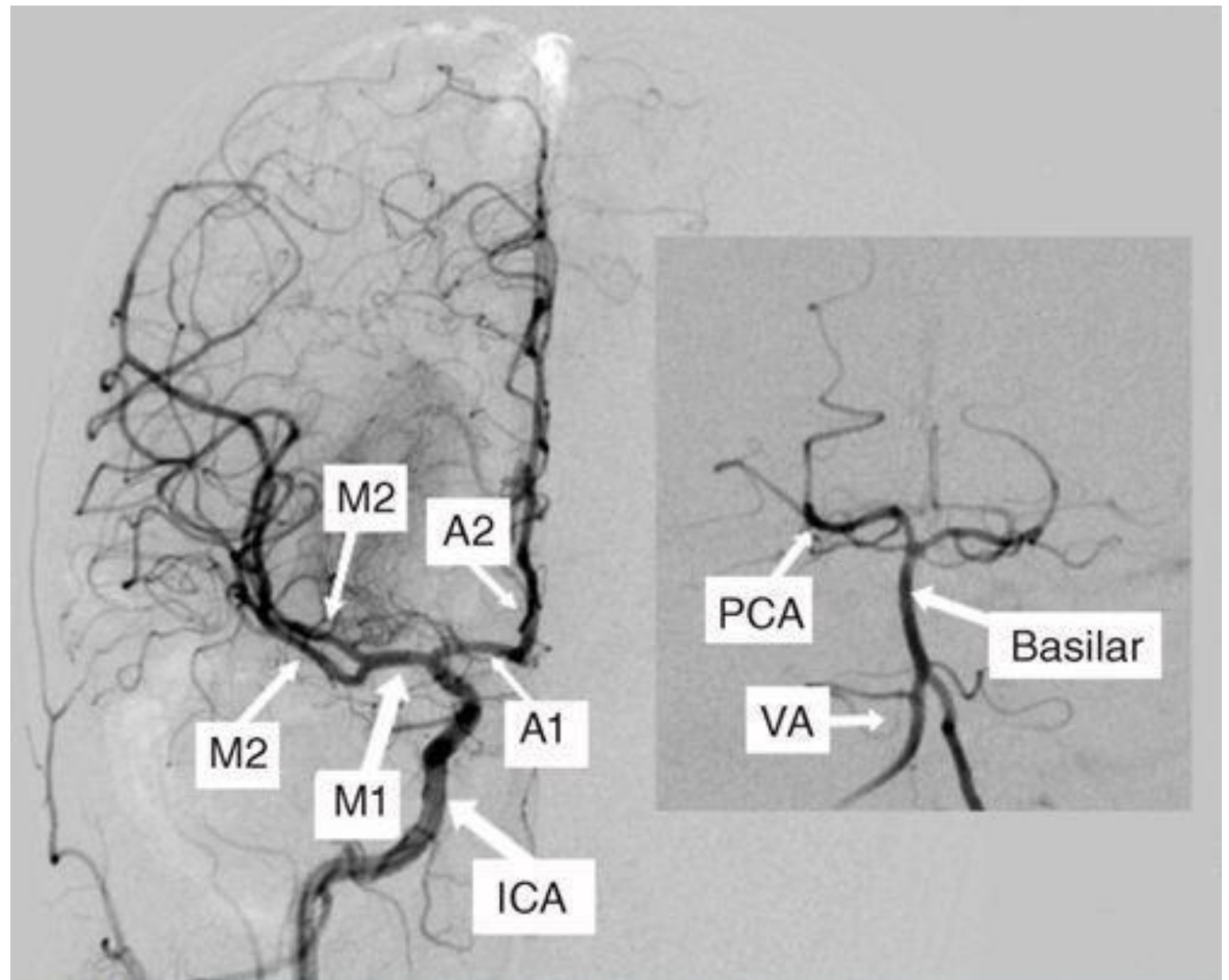
# CT Angiography → ARTERI





# CT Venography VENA



# Digital Subtraction Angiography (DSA)





# Sesi 3

# Tips untuk Mengidentifikasi Gambaran Patologis pada CT Scan

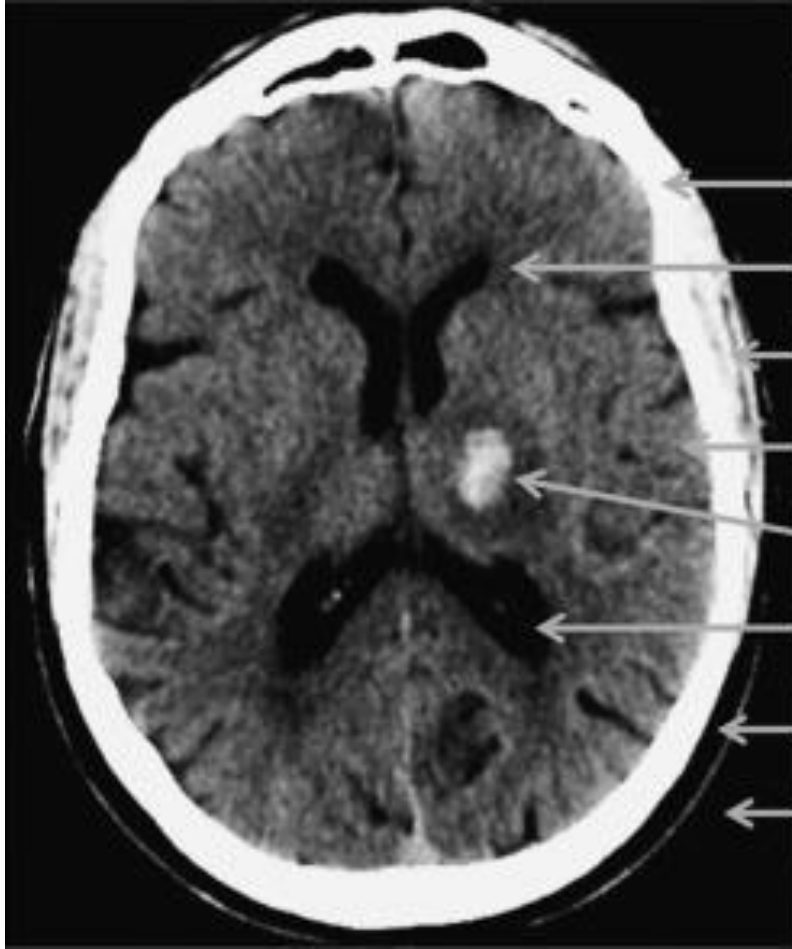
Sesi 3

# Outline

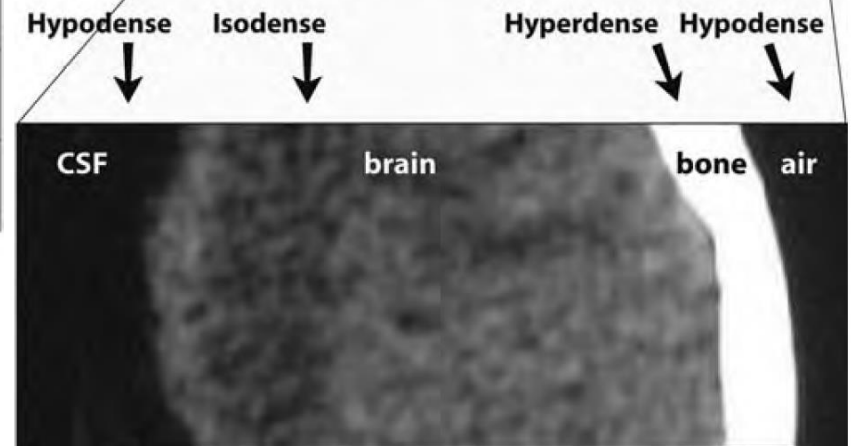
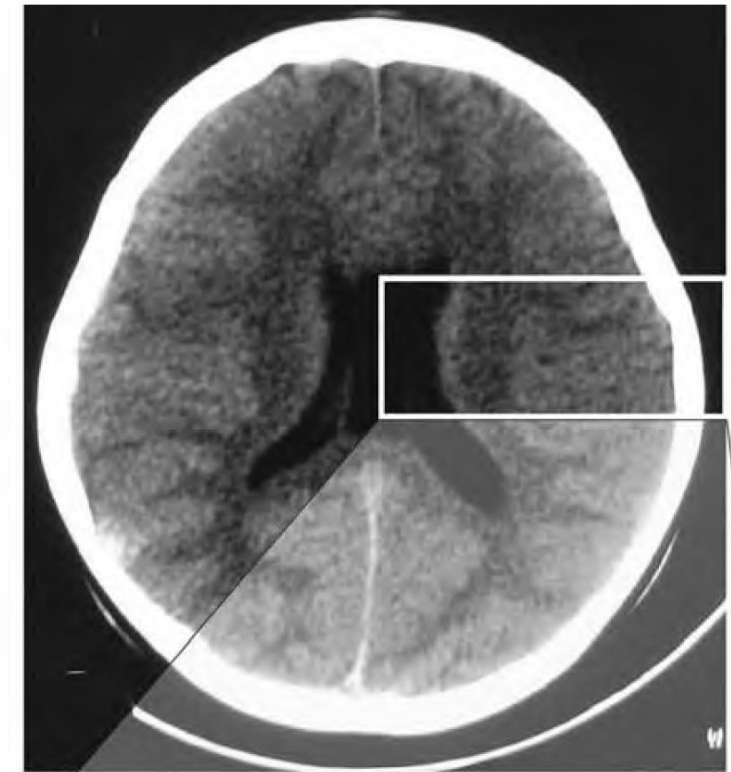
1. Gambaran umum patologis dalam CT
  1. Densitas → DOT ( HU unit )
2. Gambaran **stroke perdarahan dan infark**
  1. Infark ( akut dan kronik )
  2. SAH
  3. IVH
3. Gambaran **trauma kepala**
  1. EDH
  2. SDH → kontracoup . Akut dan kronik
  3. ICH dan kontusional
4. Gambaran **tumor otak**
  1. Efek massa + MLS
  2. Perbedaan kontras dan tanpa kontras
  3. Kasus : meningoma , pituitary adenoma dan glioma

# Gambaran Patologis Umum pada CT Scan

# Densitas pada CT Scan



CT Number Ranges in Hounsfield Units (HU)	
Bone	+1000
White matter	+20 to 30
Muscle	+20 to 40
Gray matter	+30 to 40
Hemorrhage	+65 to +95
CSF (water)	0
Fat	-30 to -70
Air	-1000



M.H. Lev, R.G. Gonzalez, in Brain Mapping: The Methods (Second Edition), 2002

# Stroke

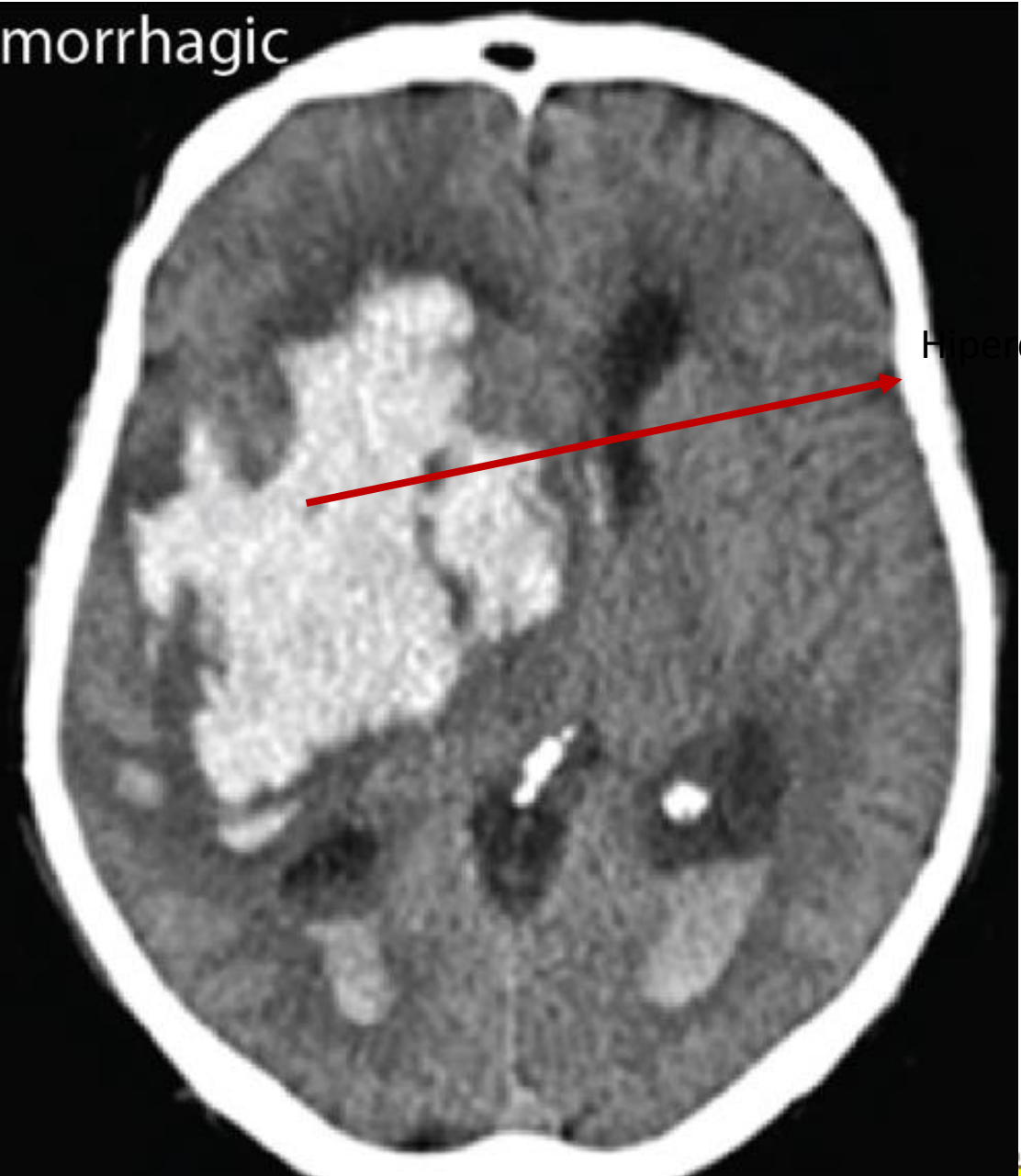
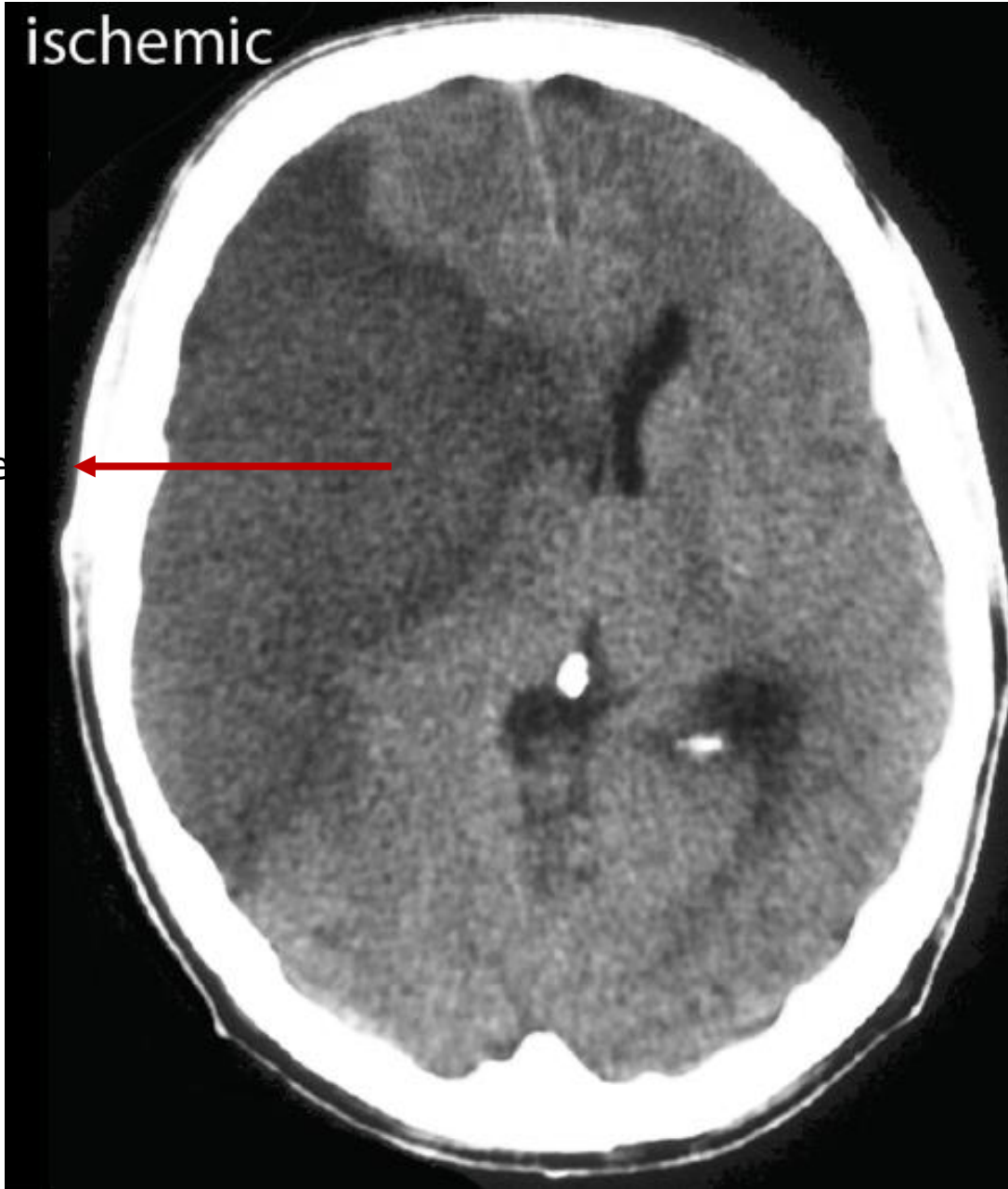Perdarahan v/s. Infark

ischemic

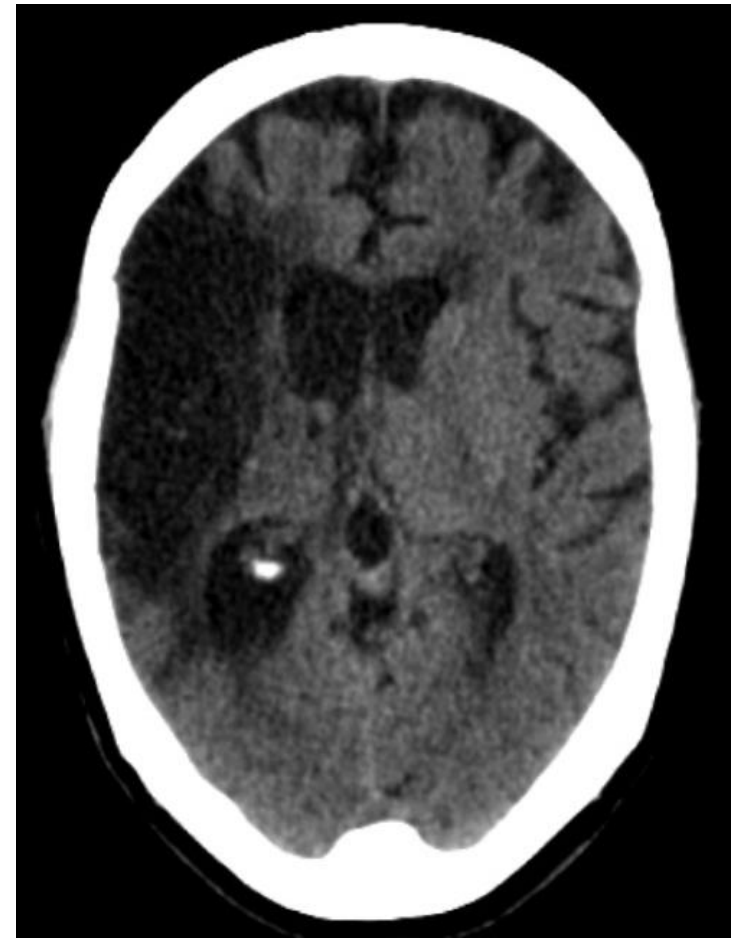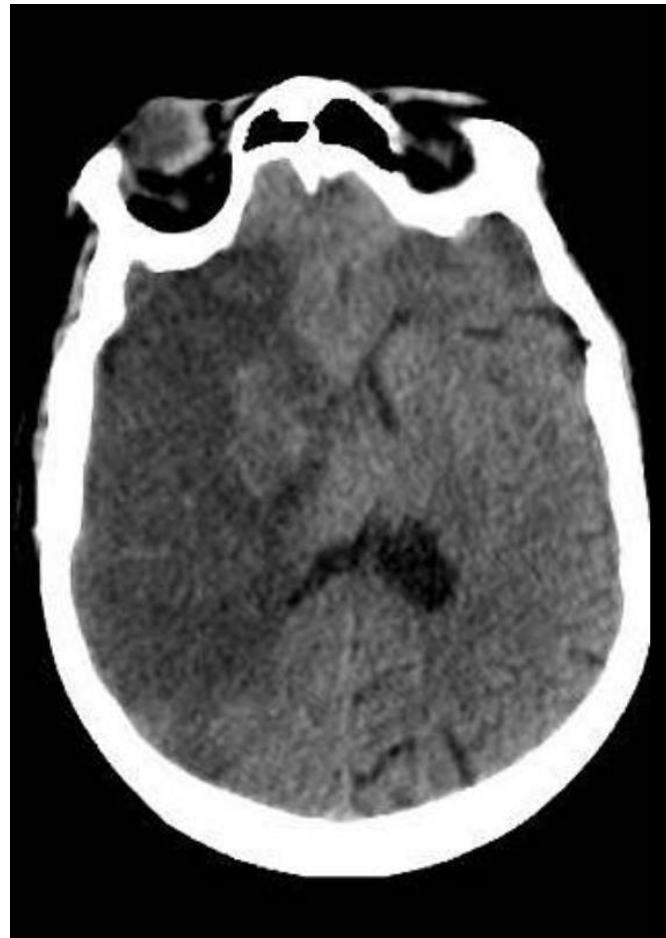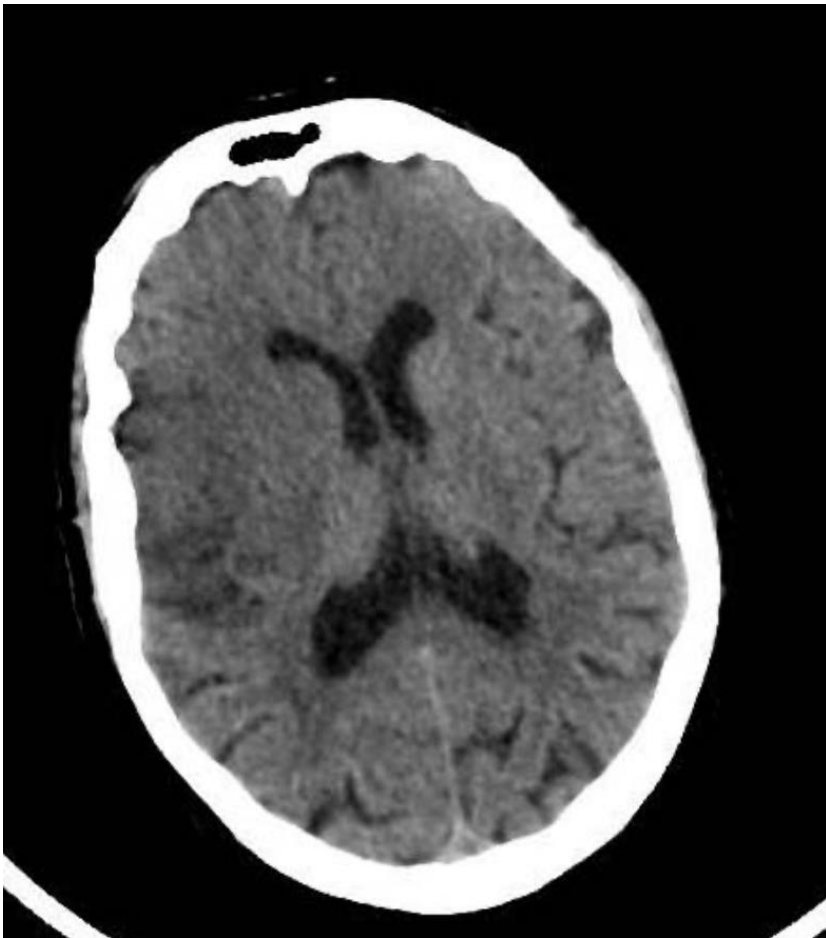hemorrhagic

Hipode

Hiperdens

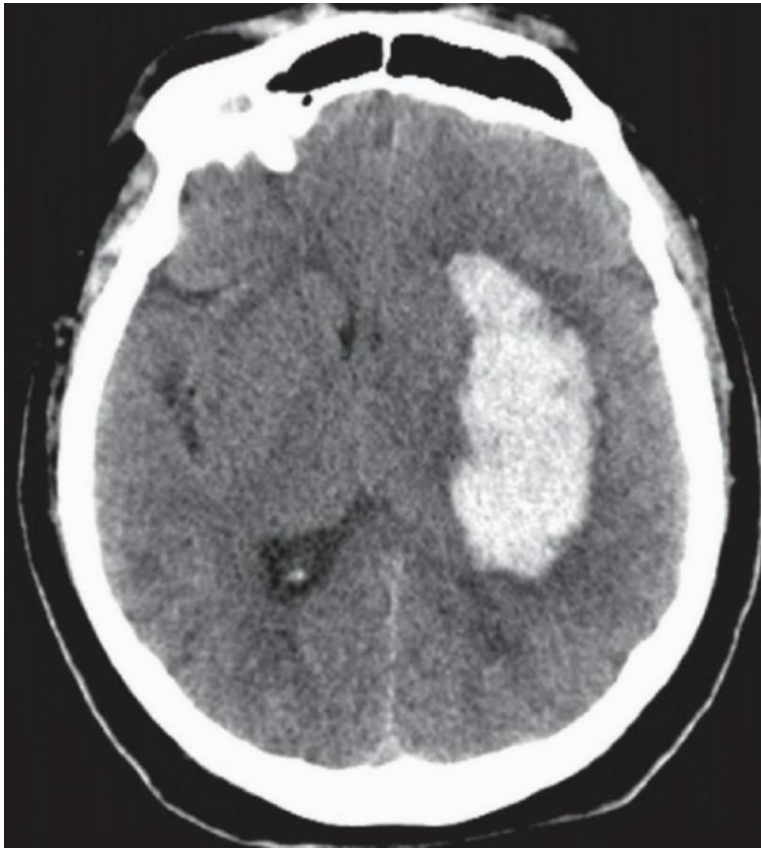


Hyper Acute → Acute → Chronic **Infarct**

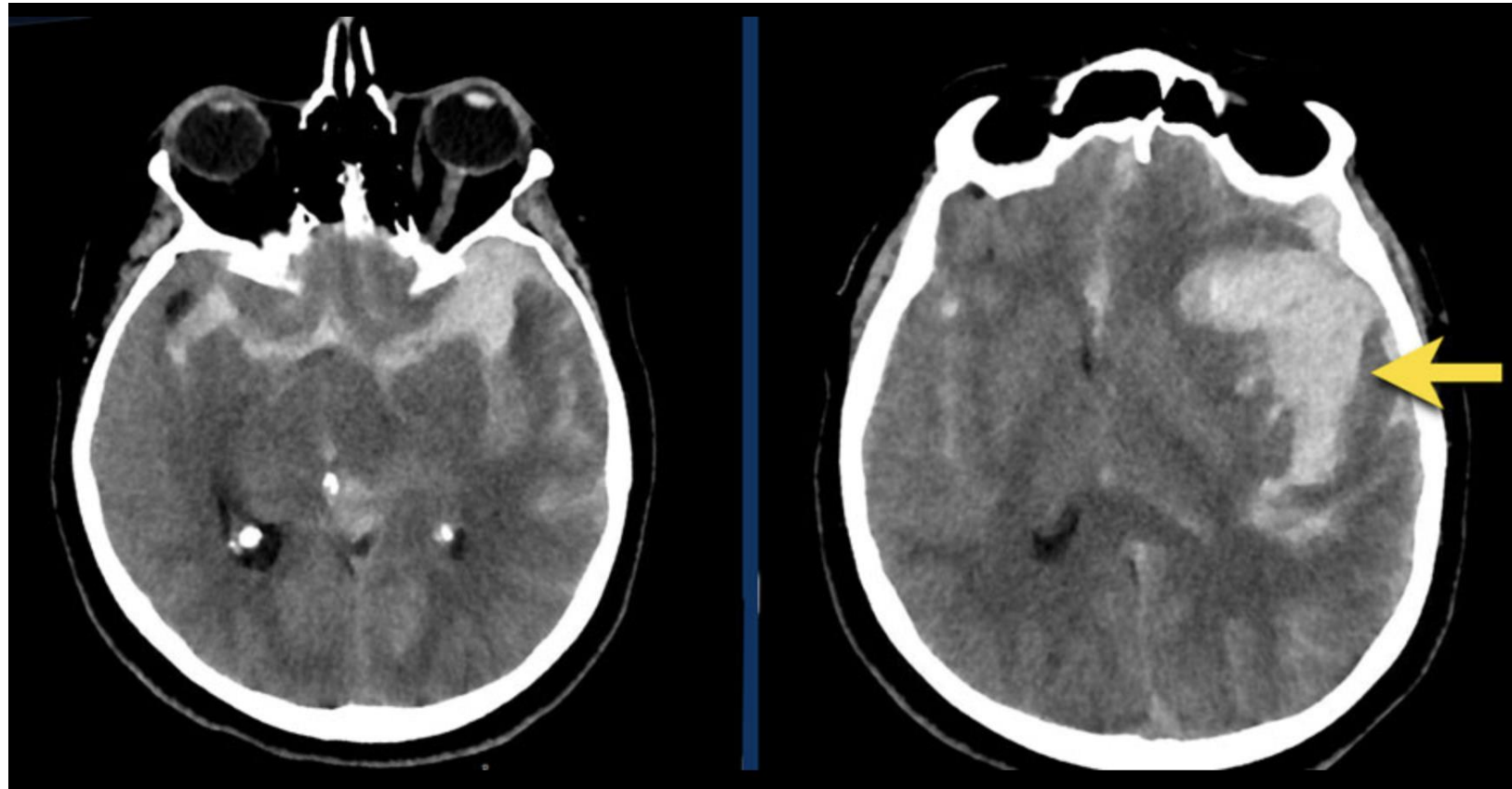


# Stroke **Perdarahan**

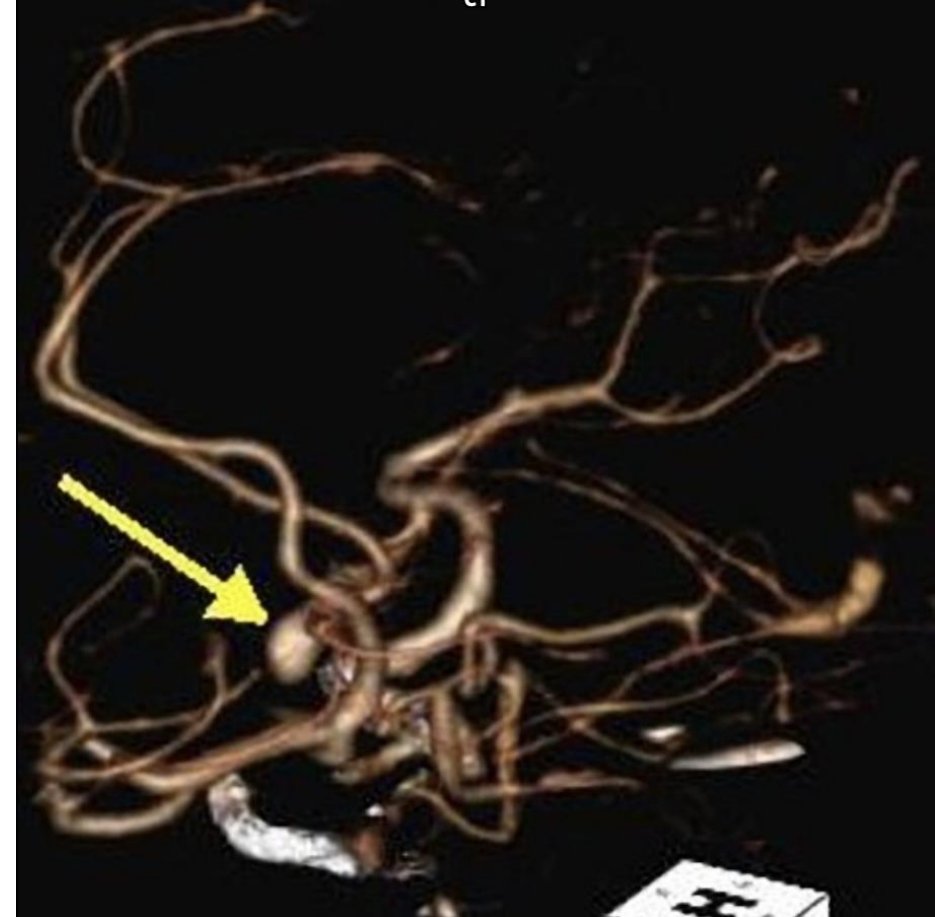
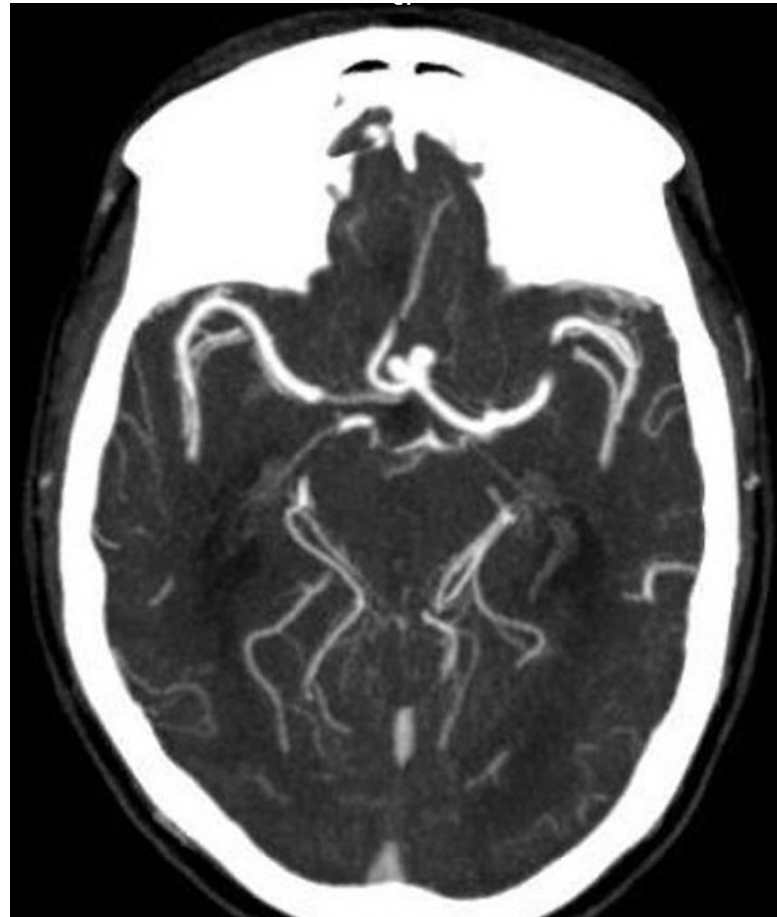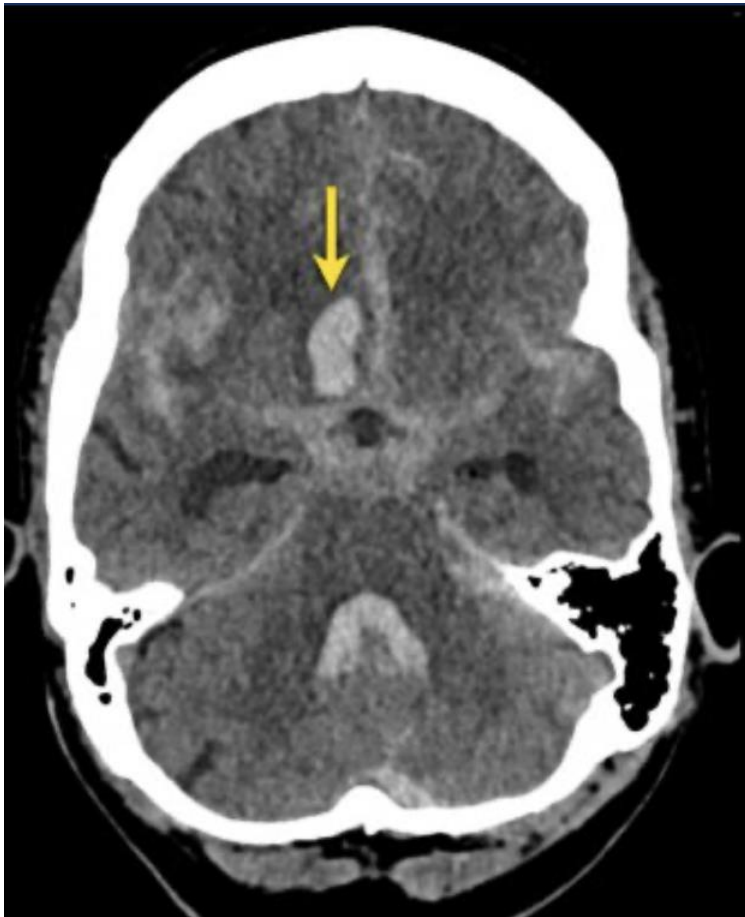
Tipikal ICH Hipertensive



Malformasi vascular susp aneurisma

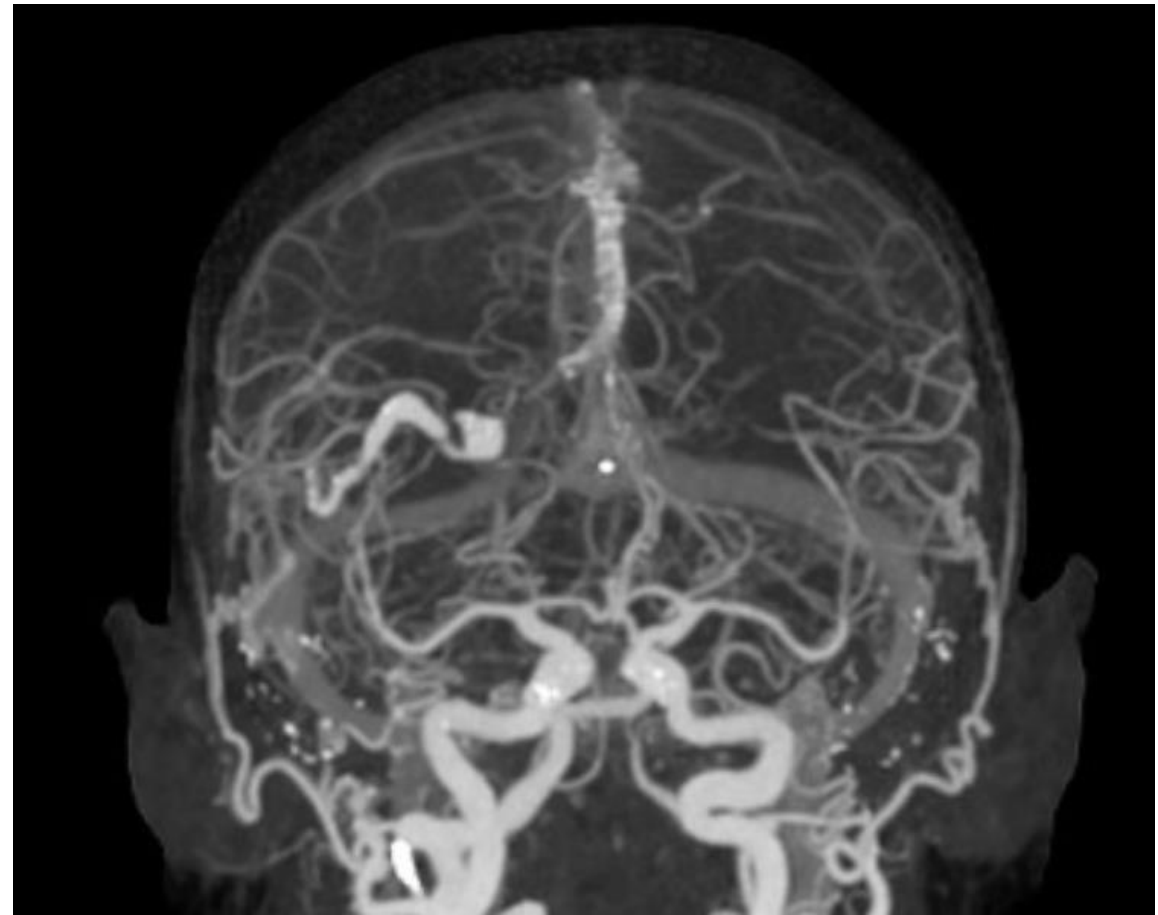
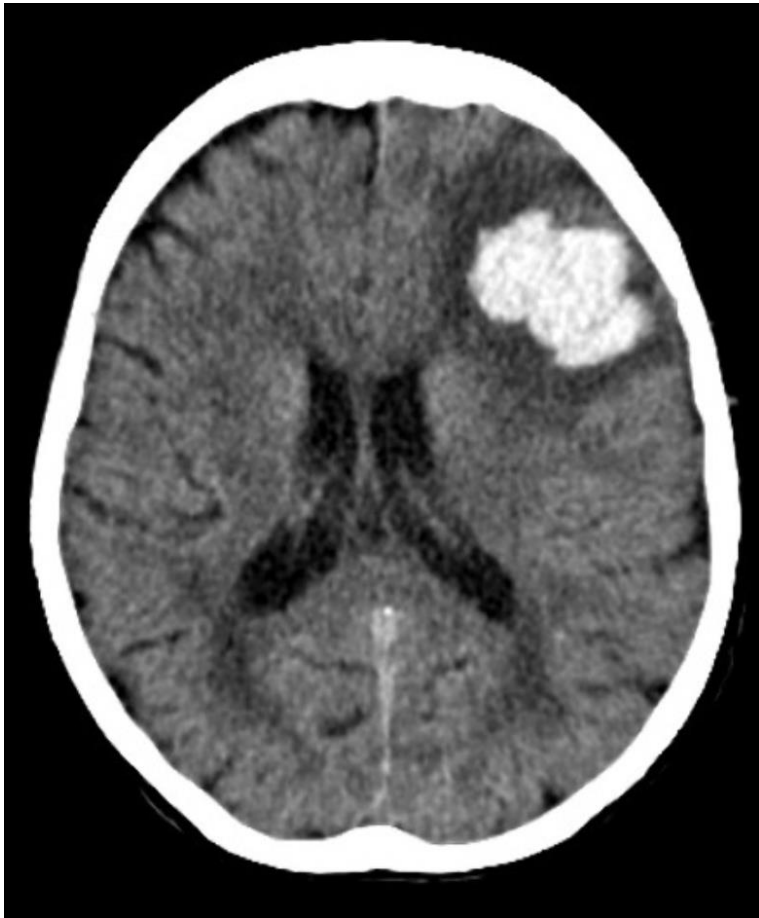
# Spontaneous SAH

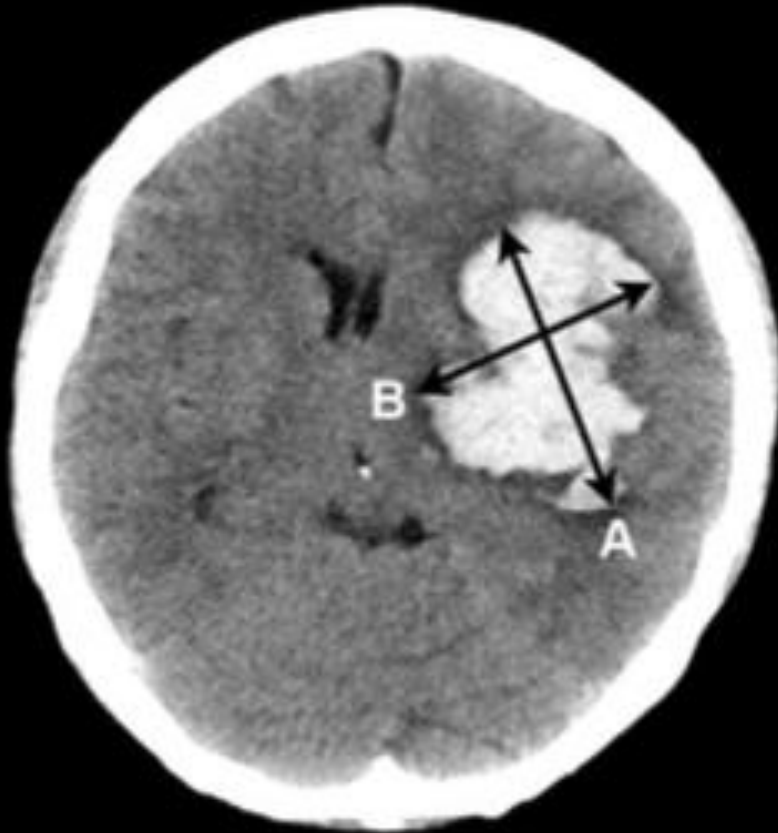


# ICH Kortikal

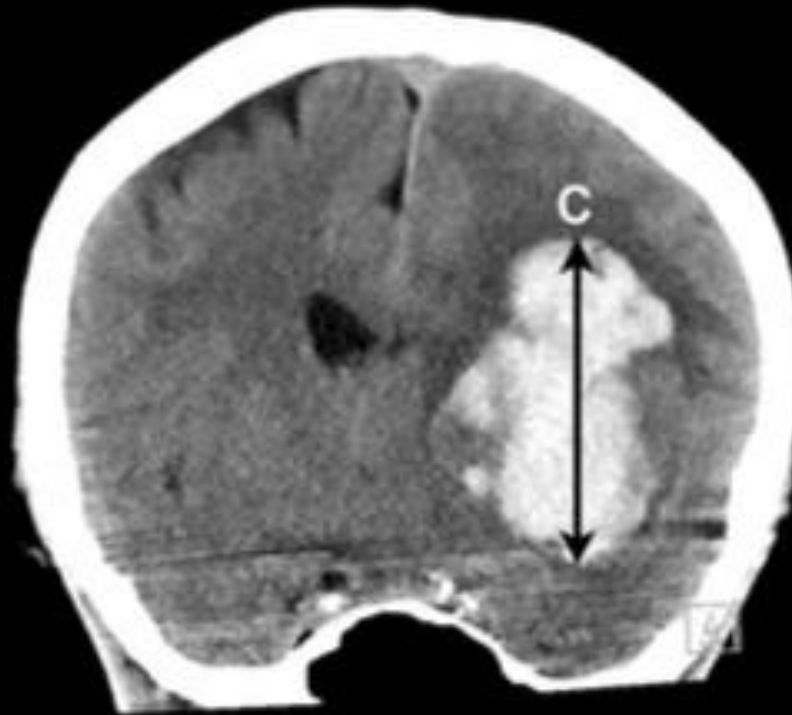Susp. AVM



# Volume



A = 5.9cm  
B = 5.0cm

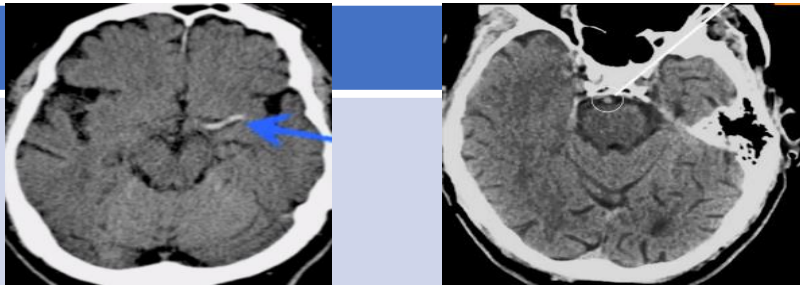



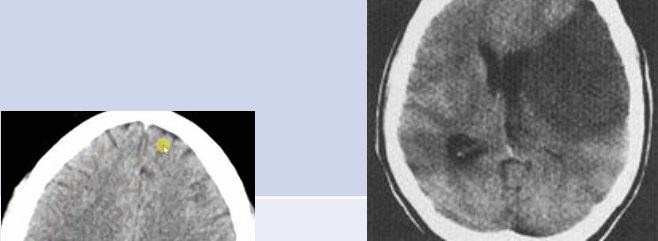
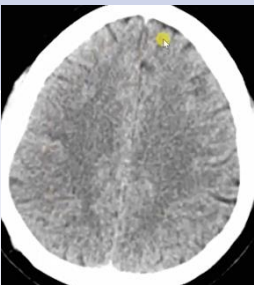


C = 6.1cm

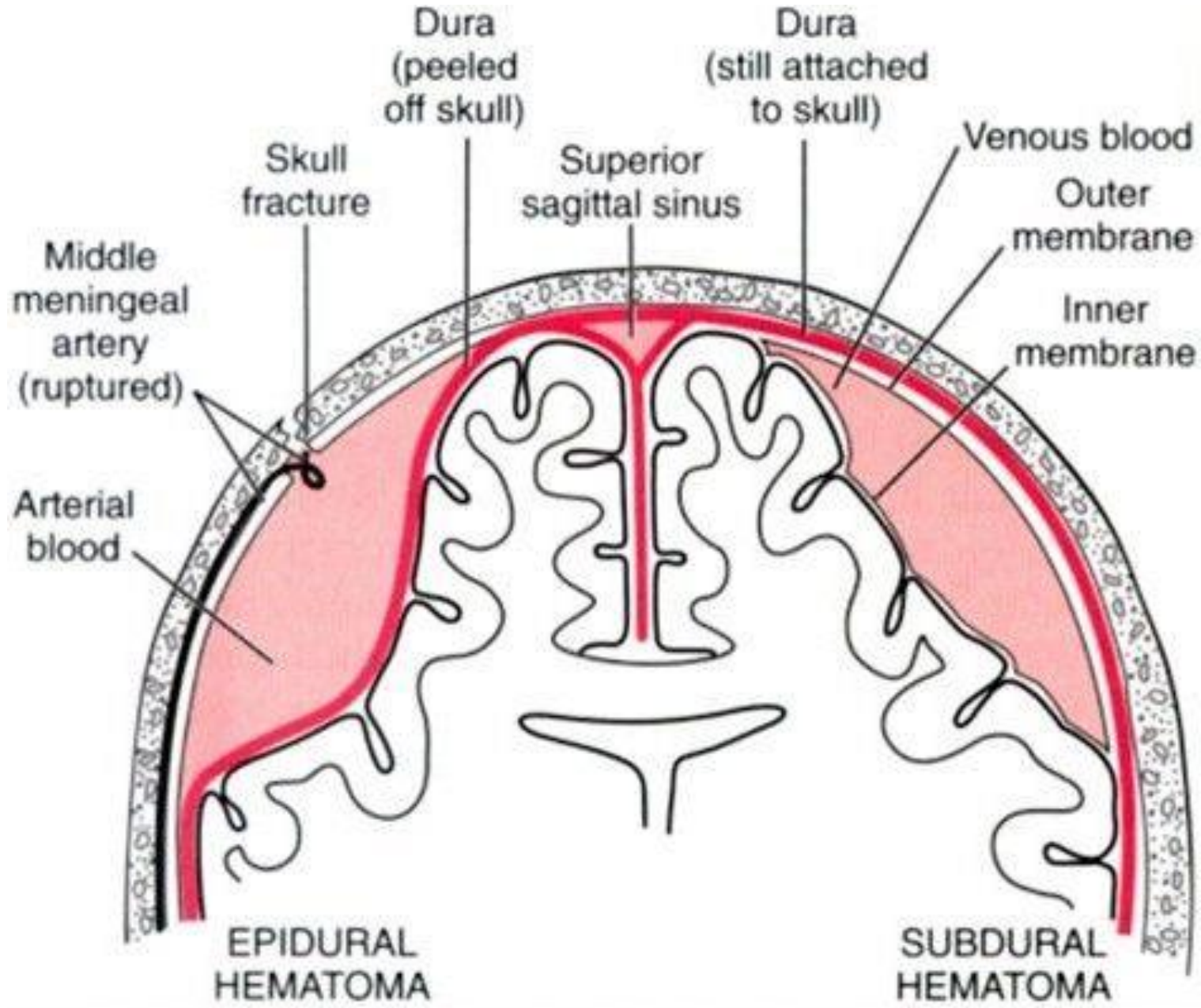
$$\text{Volume} = \frac{ABC}{2}$$

$$\text{Volume} = \frac{5.9 \times 5.0 \times 6.1}{2}$$

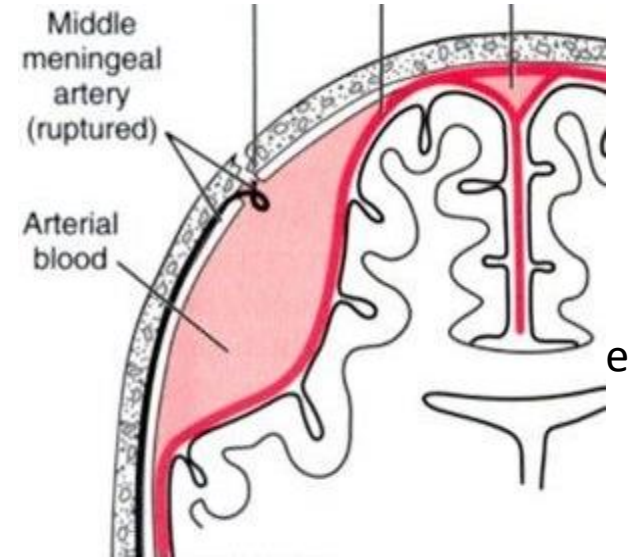
$$\text{Volume} = 90\text{mL}$$

CT Scan Hiperakut Stroke			
Hyperdense Vessel Sign	Intraluminal thrombus		
Loss of insular ribbon sign	Cytotoxic edema		
Obscuration lentiform nucleus	Cytotoxic edema		
Loss of Gray – White matter distinction	Cytotoxic edema		
Area hypoattenuation	Irreversible tissue damage		
Sulcal effacement	Mass effect		

# Gambaran Trauma Kepala



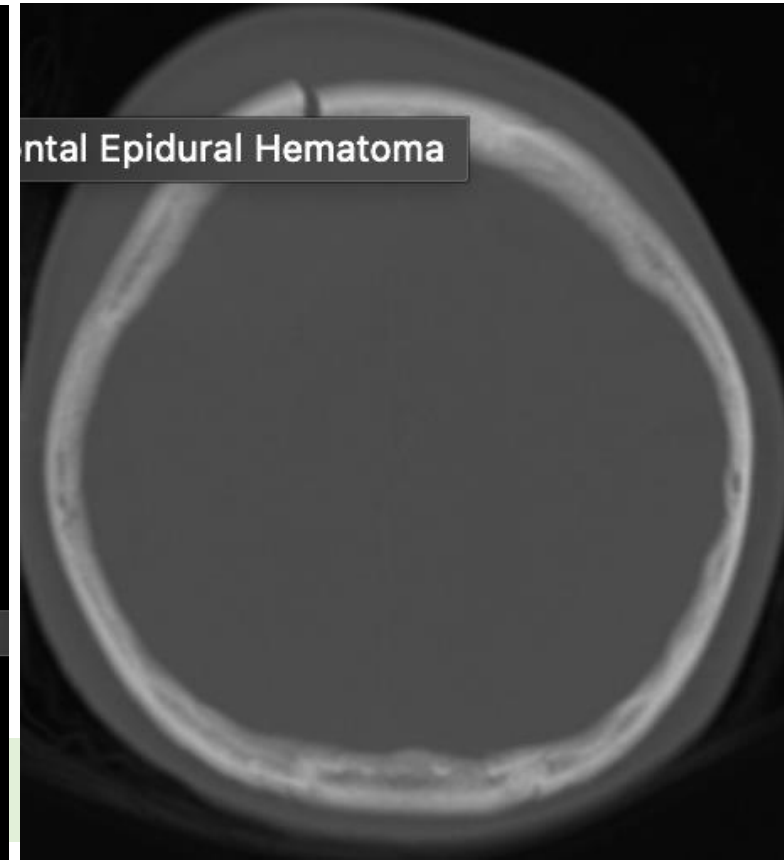
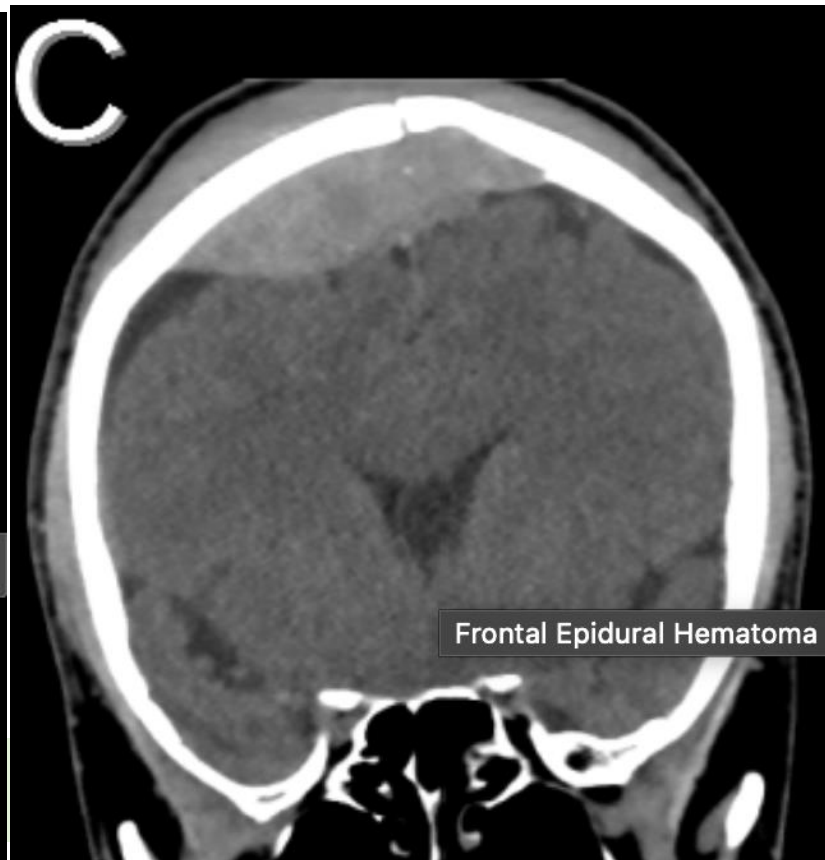
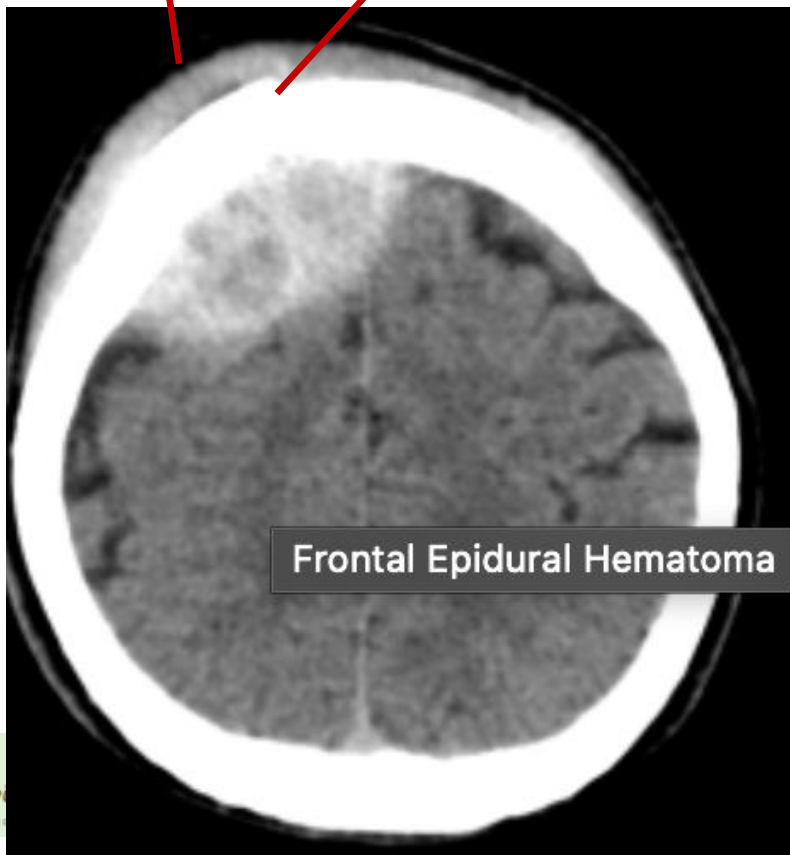
# Epidural Hematoma (EDH)



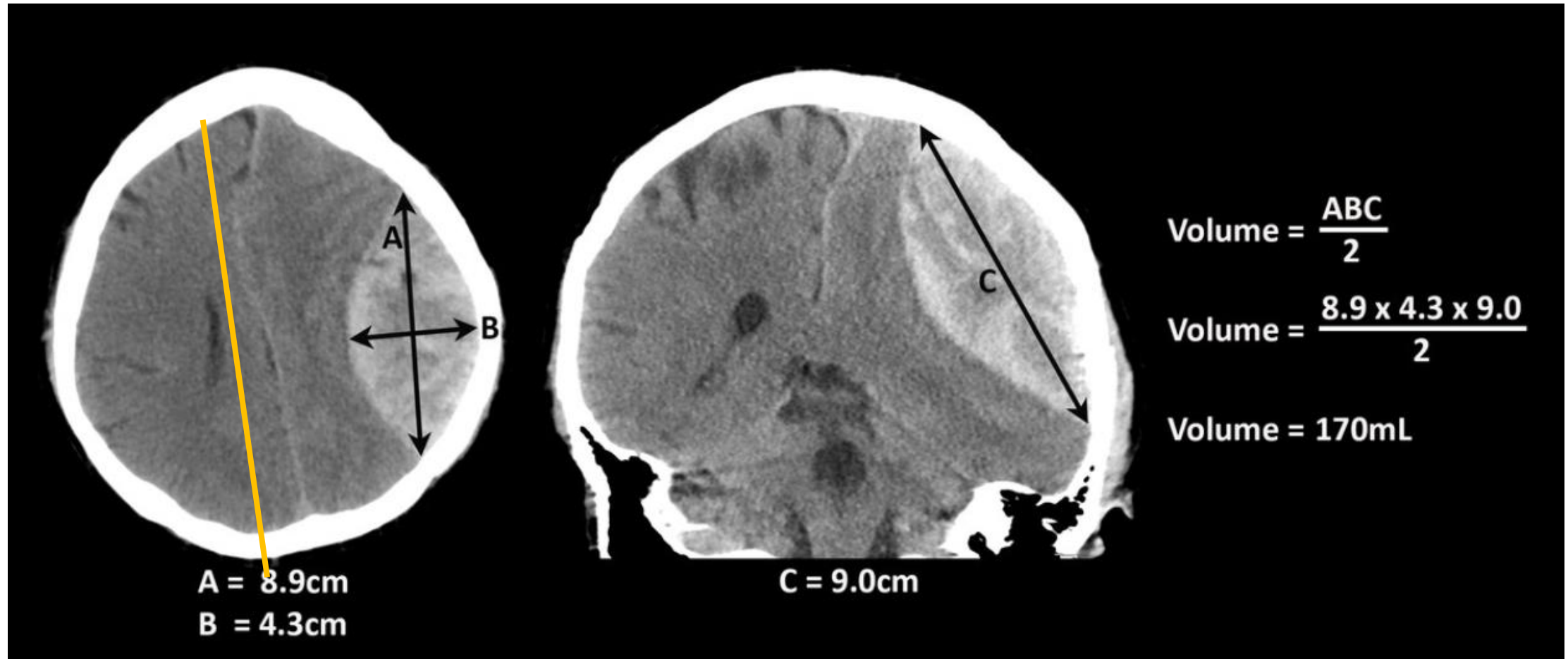
SCALP Hematom

Biconvex

Coupe

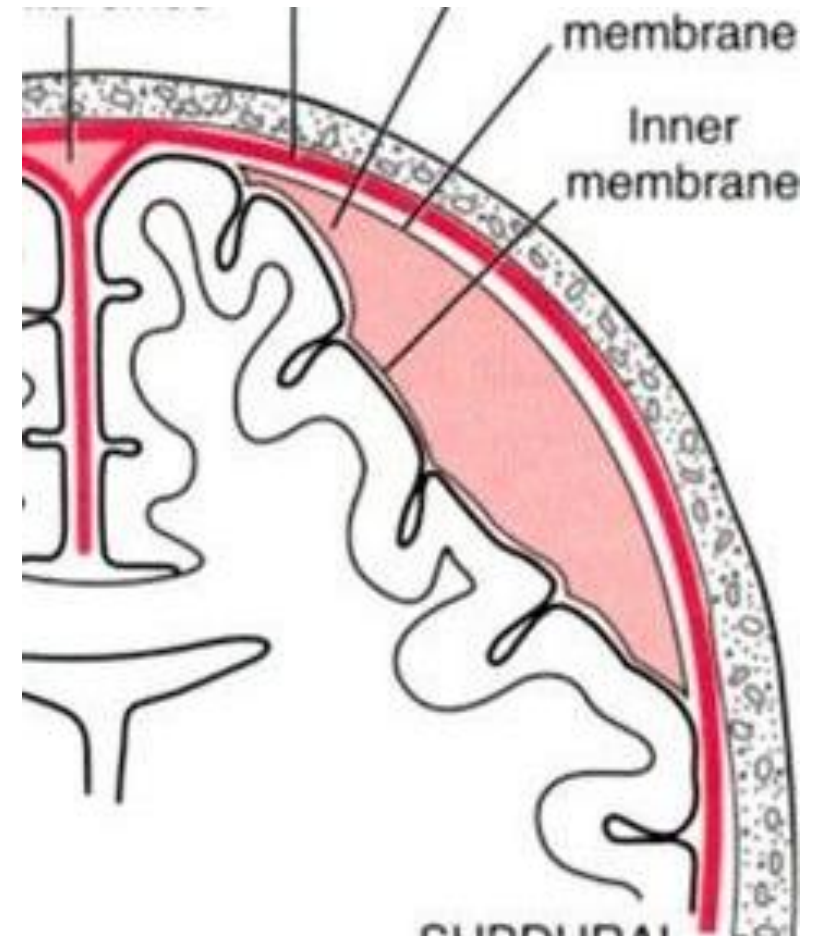
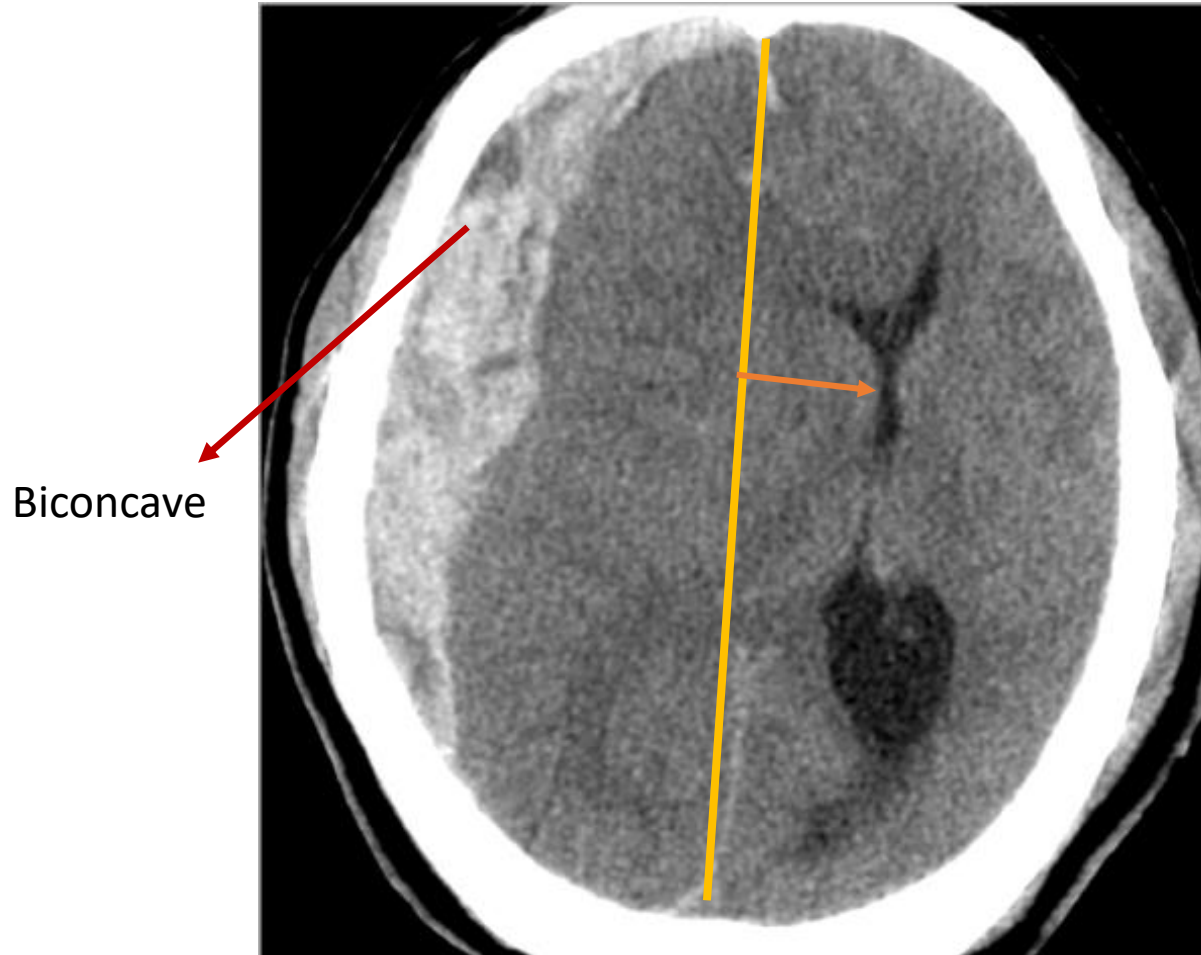


1. Volume
2. midline shift ( MLS )

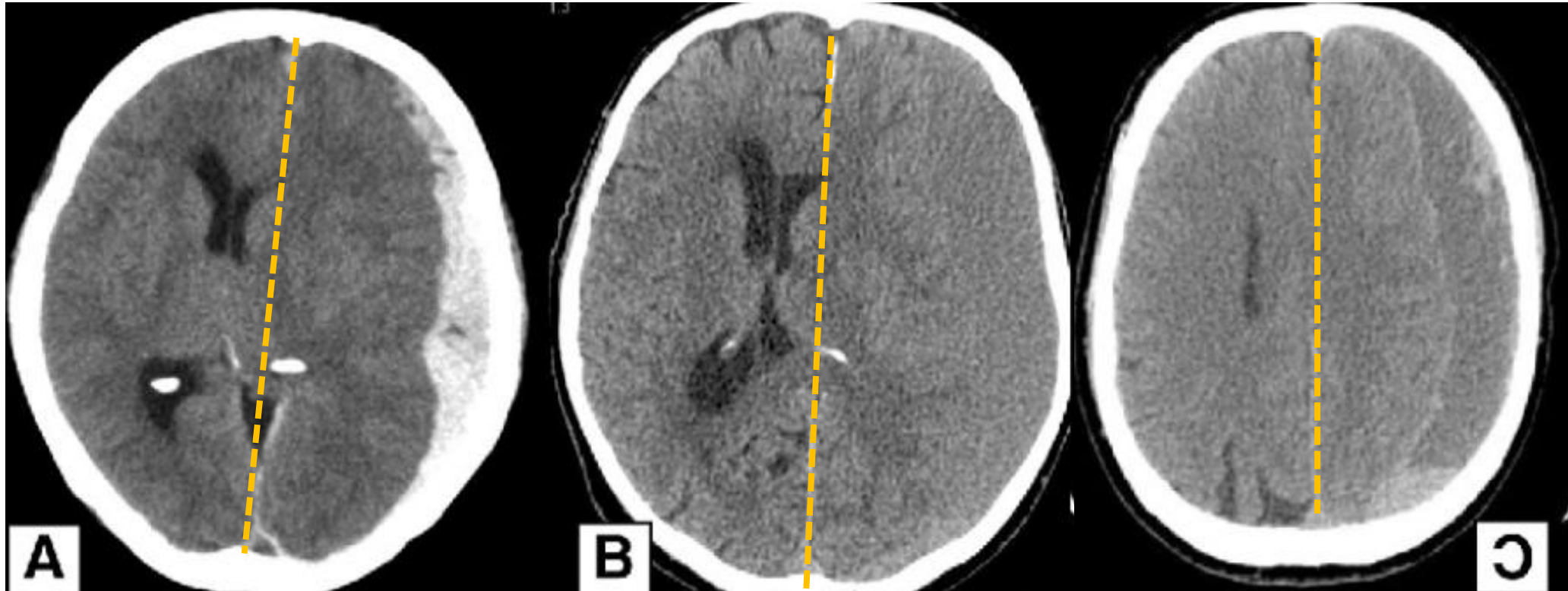


# Subdural Hematoma

- Pria 58 tahun datang ke IGD dengan penurunan kesadaran setelah terjatuh dari tangga dirumahnya



SDH Acute → Sub-acute → chronic



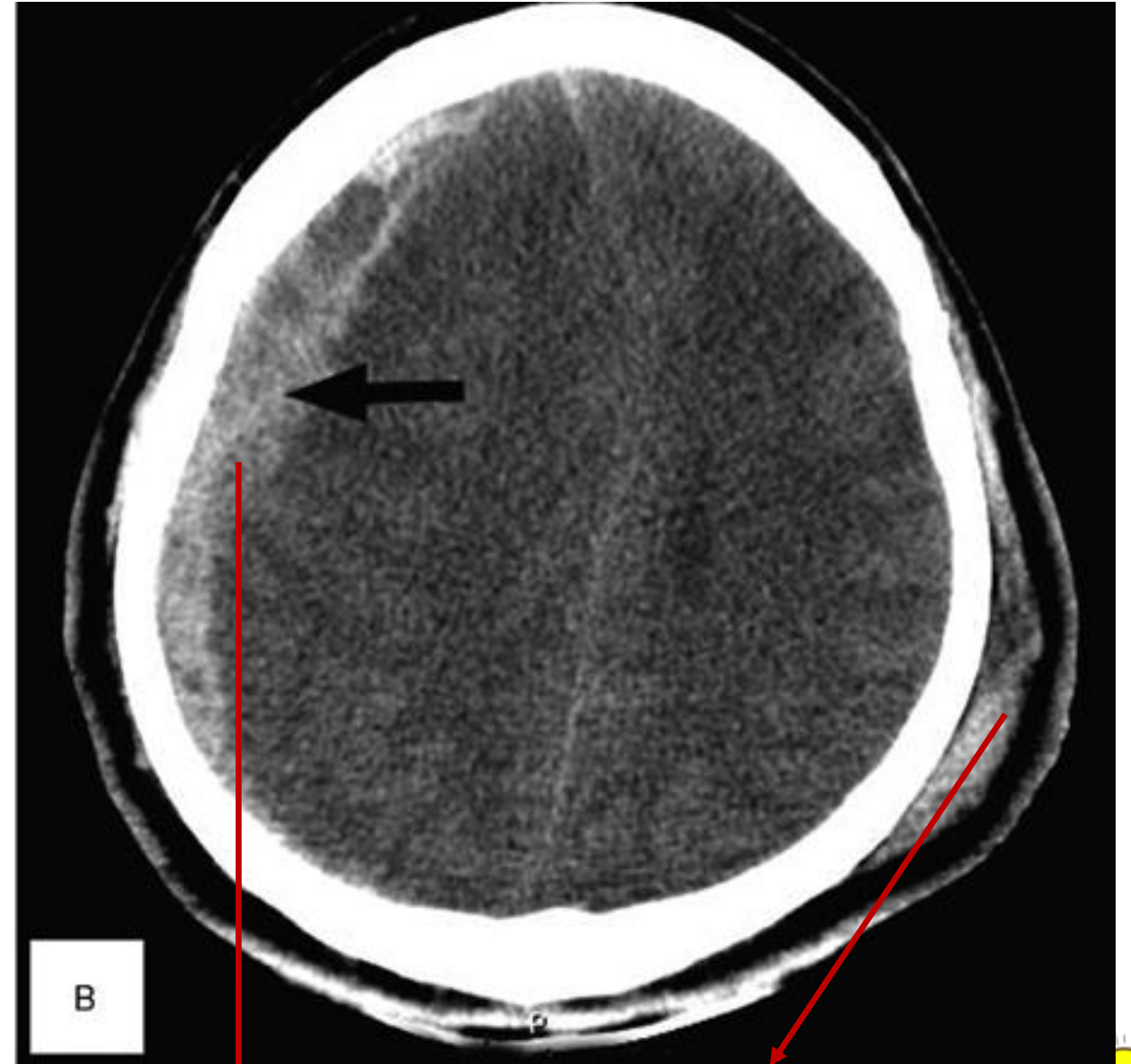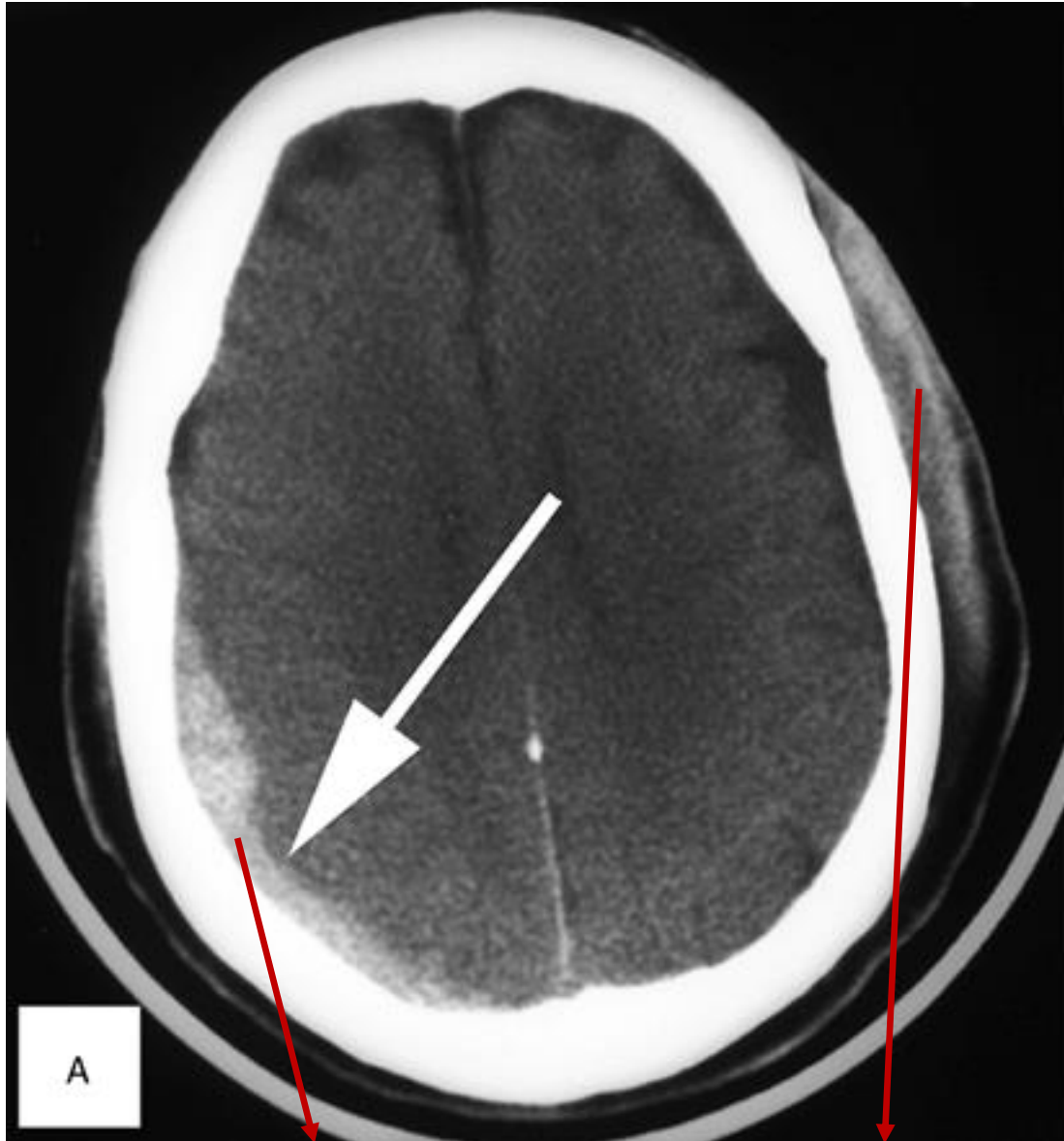
Acute

Sub-acute

Chronic

Perhatikan **MLS** (midline shift)

# COUP AND COUNTRA COUP SDH



A

B

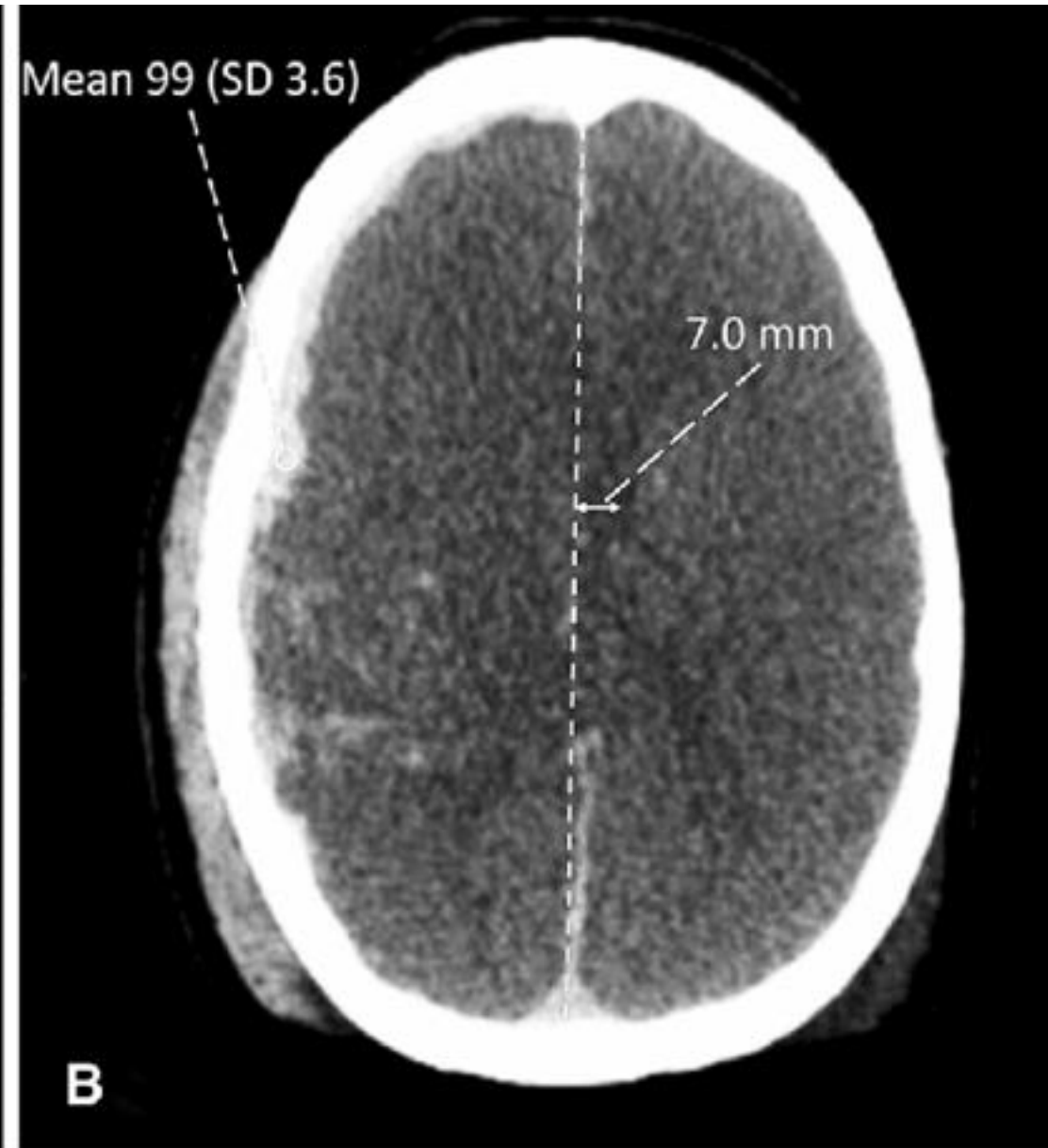
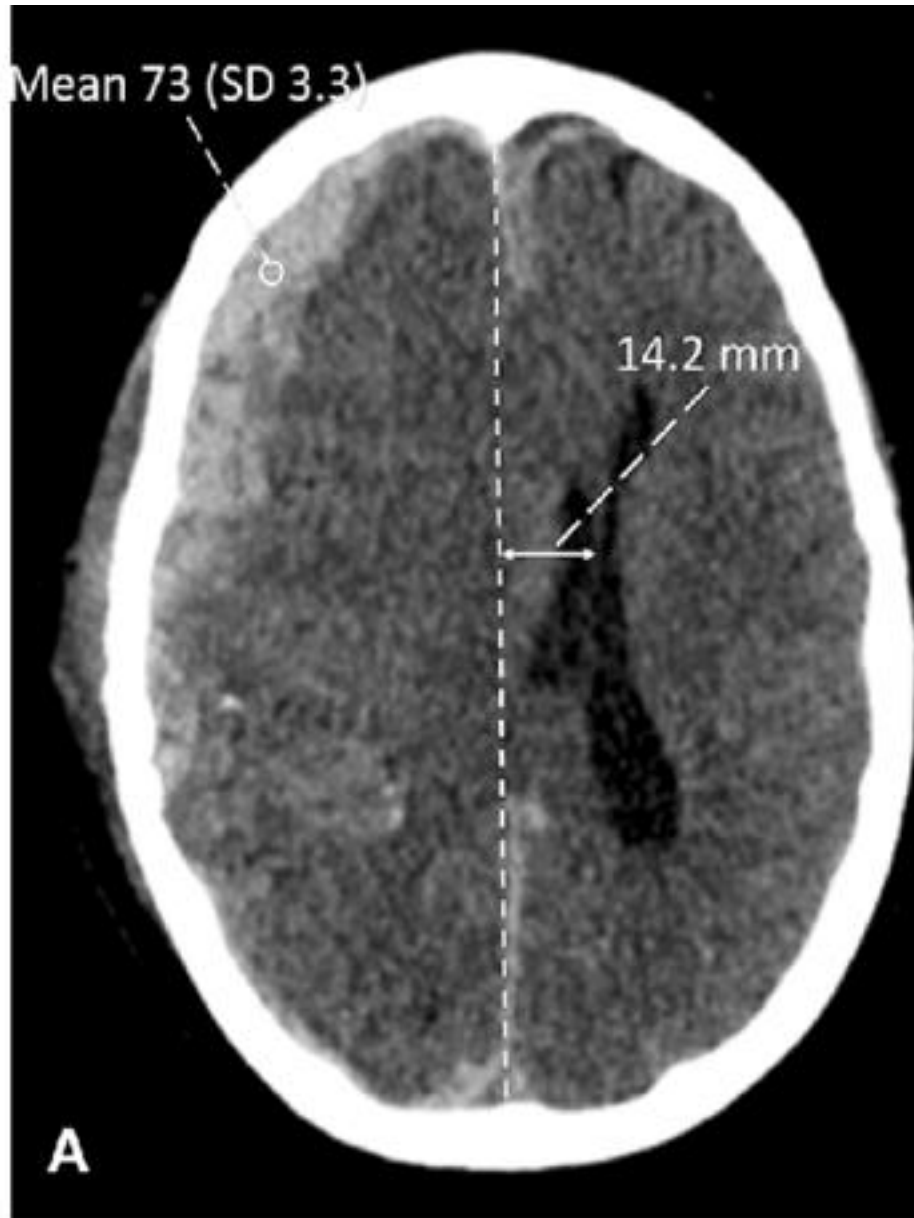
Lesi countra coupe

SCALP Hematome

Lesi countra coupe

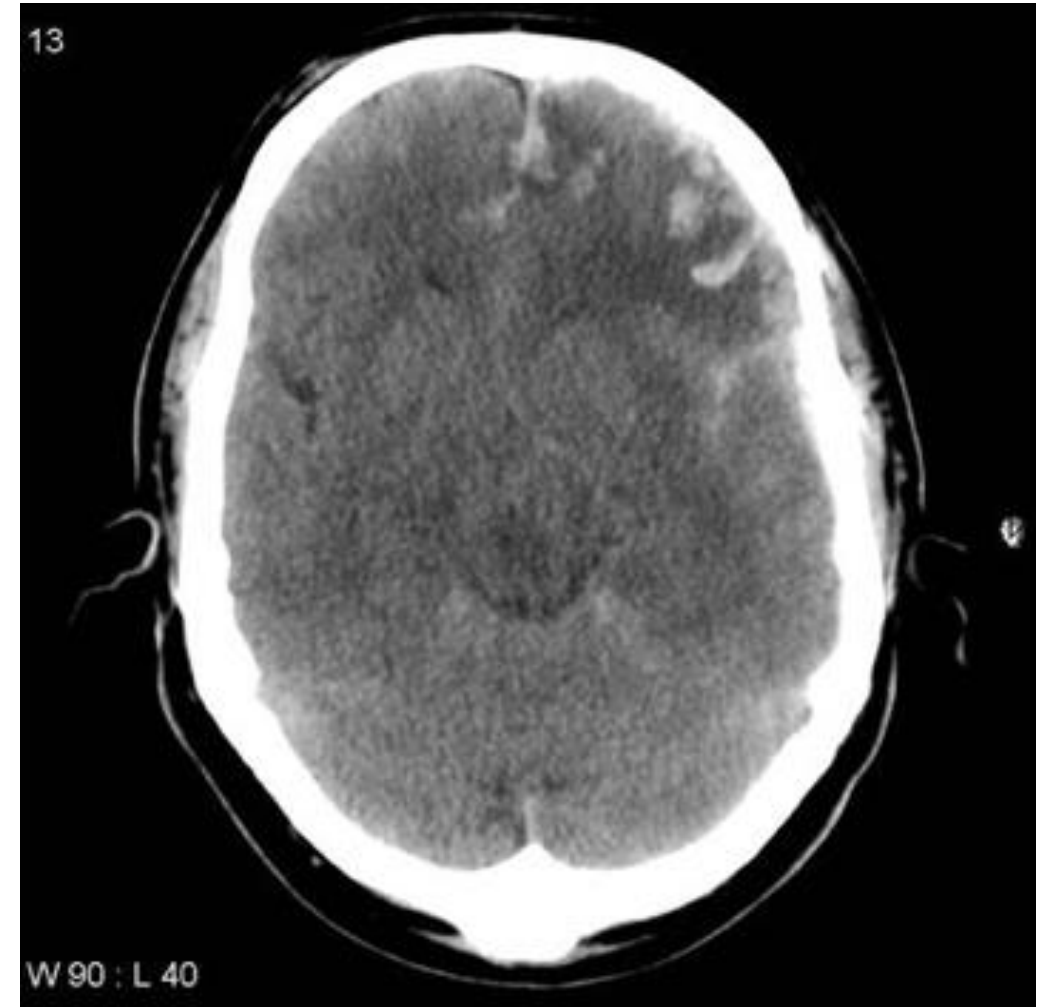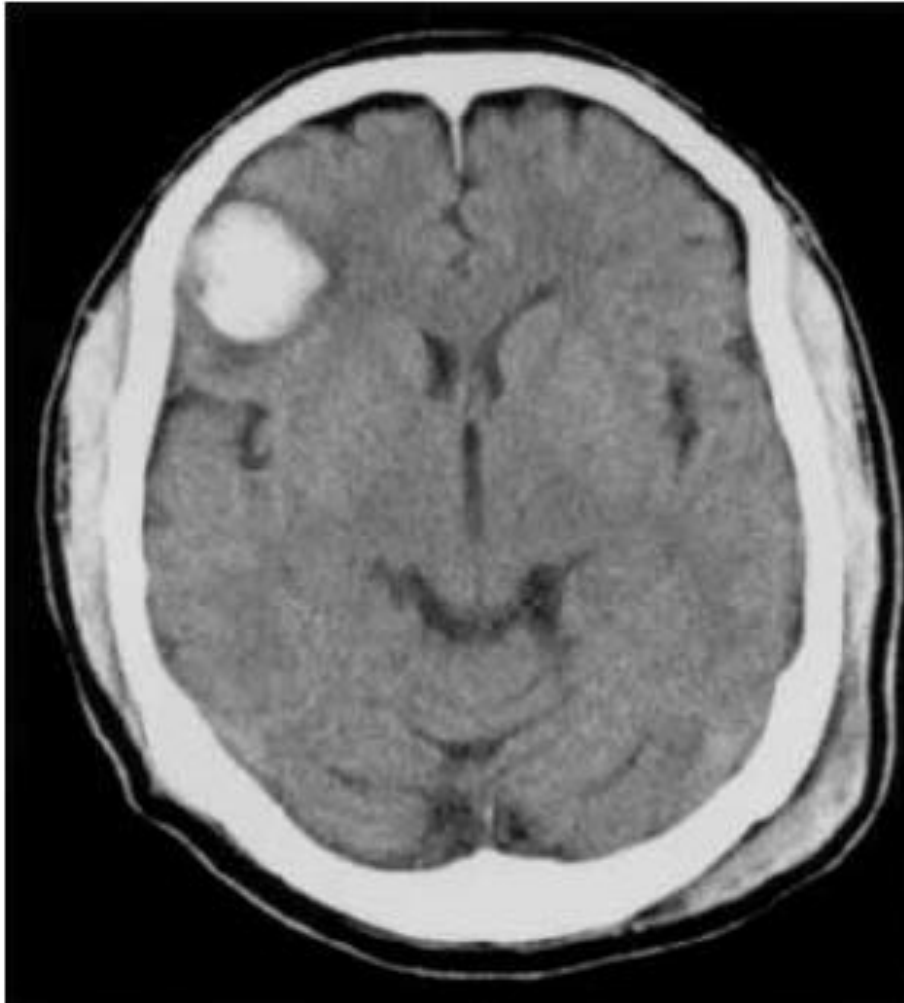
SCALP Hematome

Midline  
Shift  
(MLS)  
> 0,5 cm

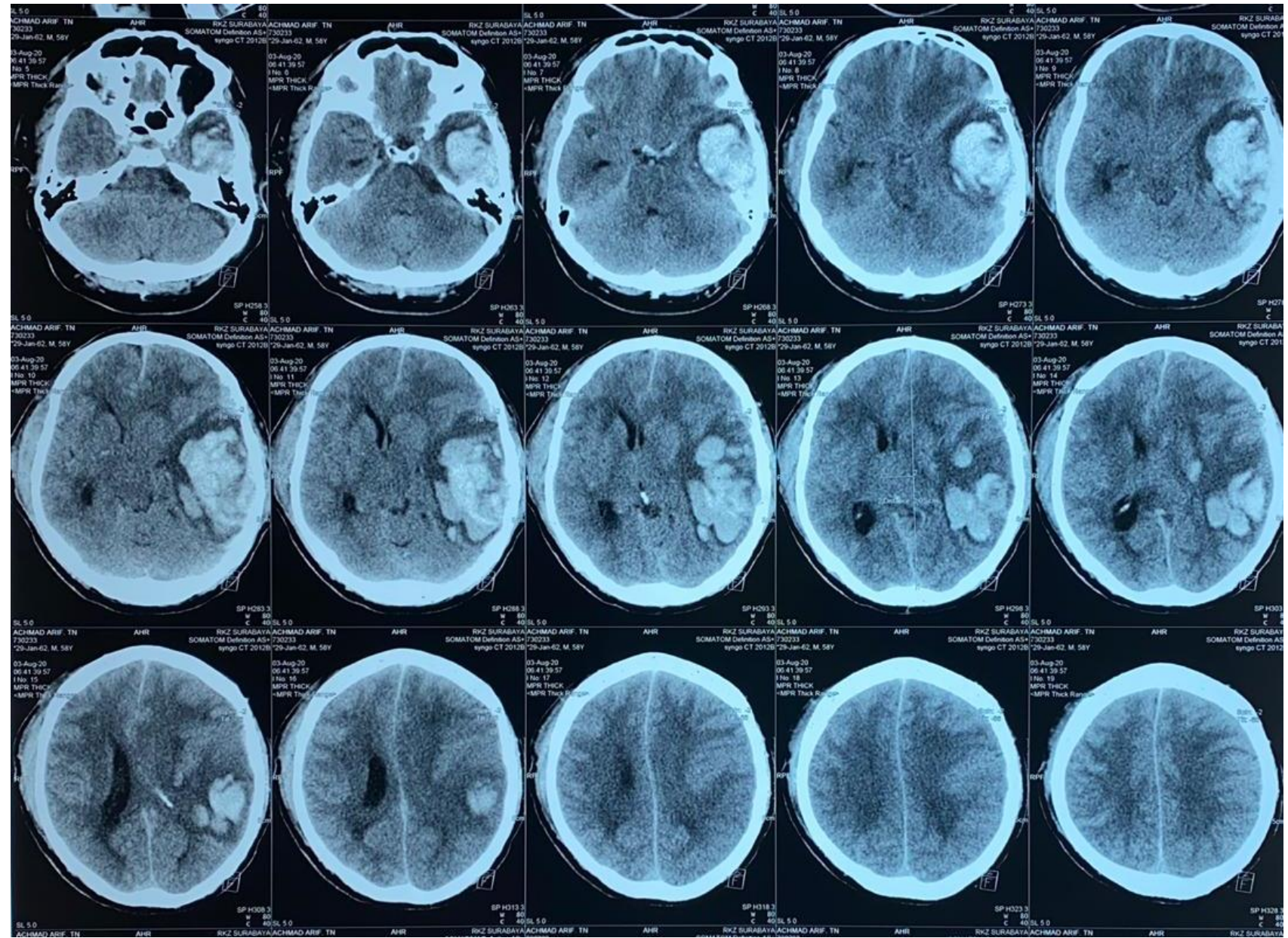


# ICH vs. Kontusional

Disebut ICH jika volume  $> 5$  cc atau diameter  $> 2$  cm,  
Kontusio jika volume  $< 5$  cc atau diameter  $< 2$  cm

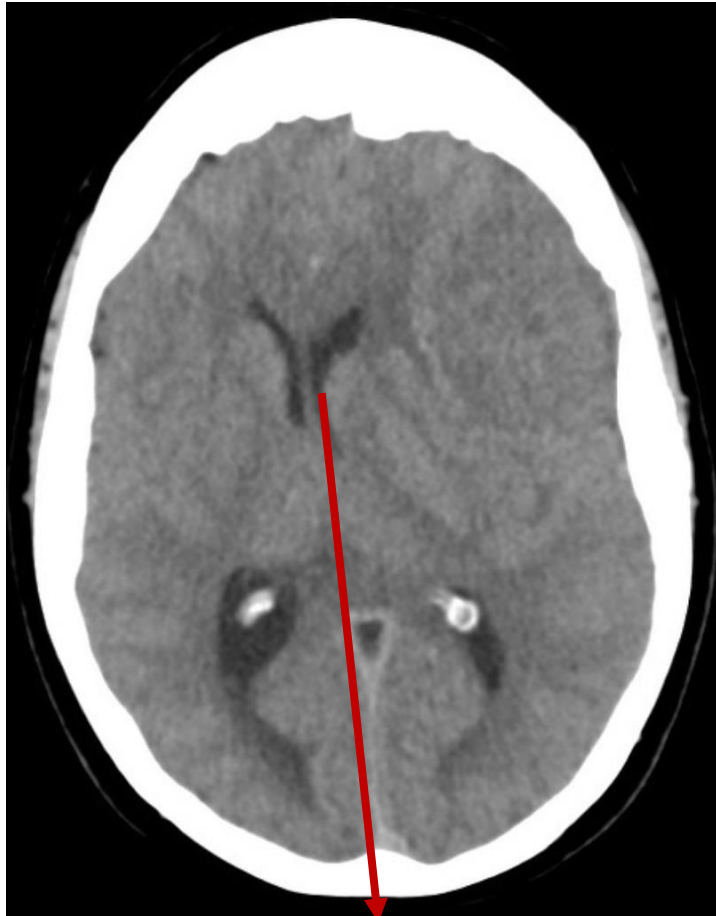


# Traumatic ICH

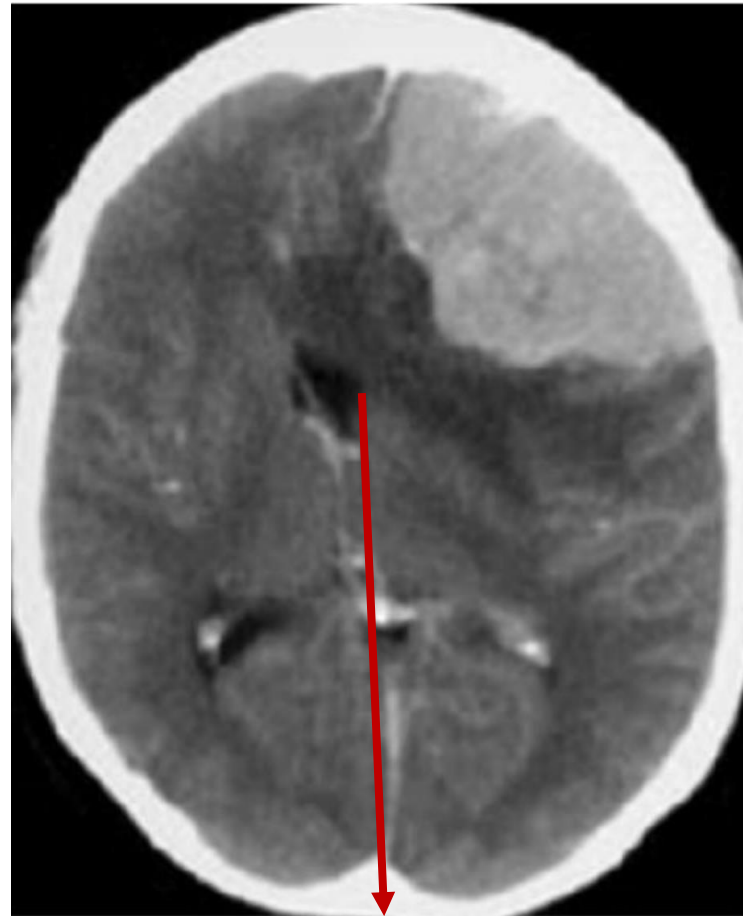


# Gambaran Tumor Otak

# Tumor Otak Ekstra-aksial

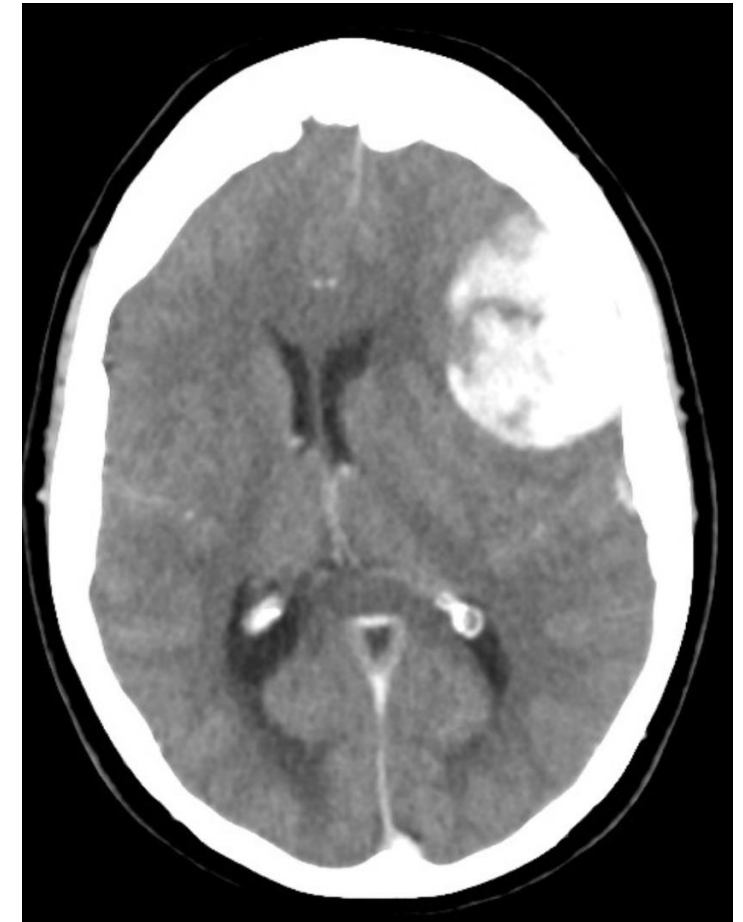

Efek massa

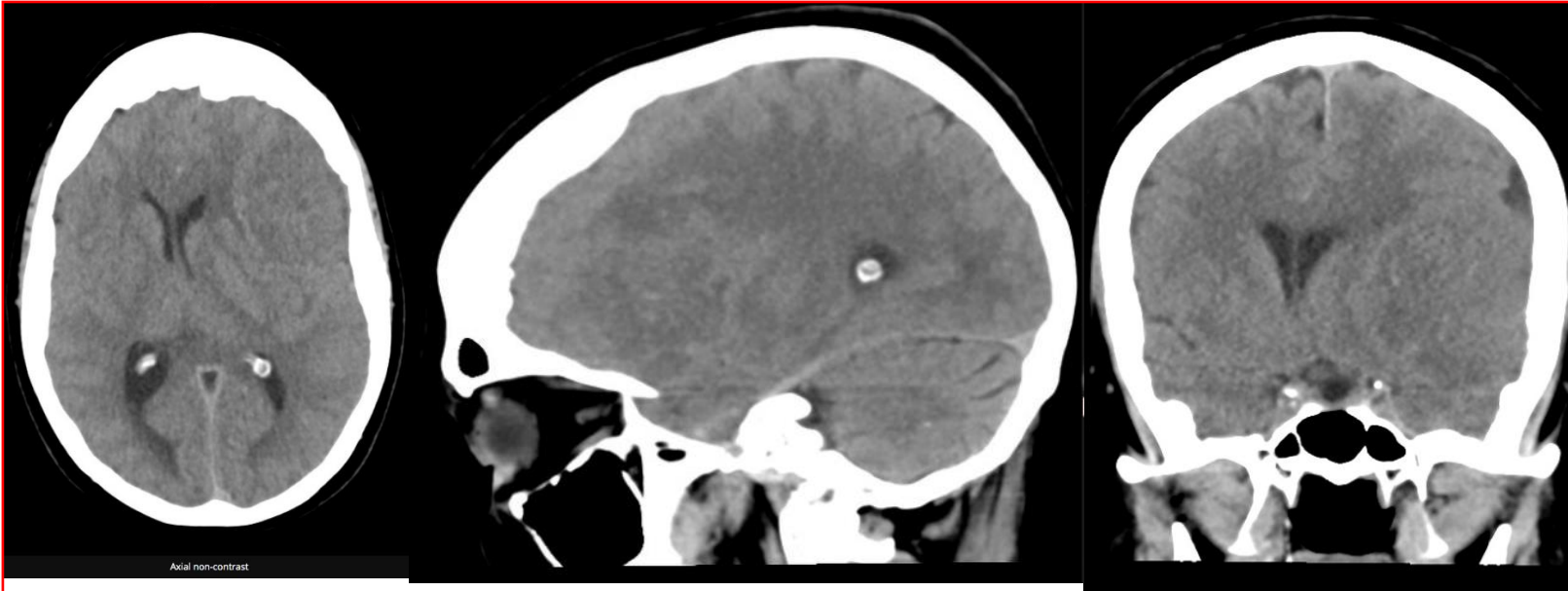

Efek massa

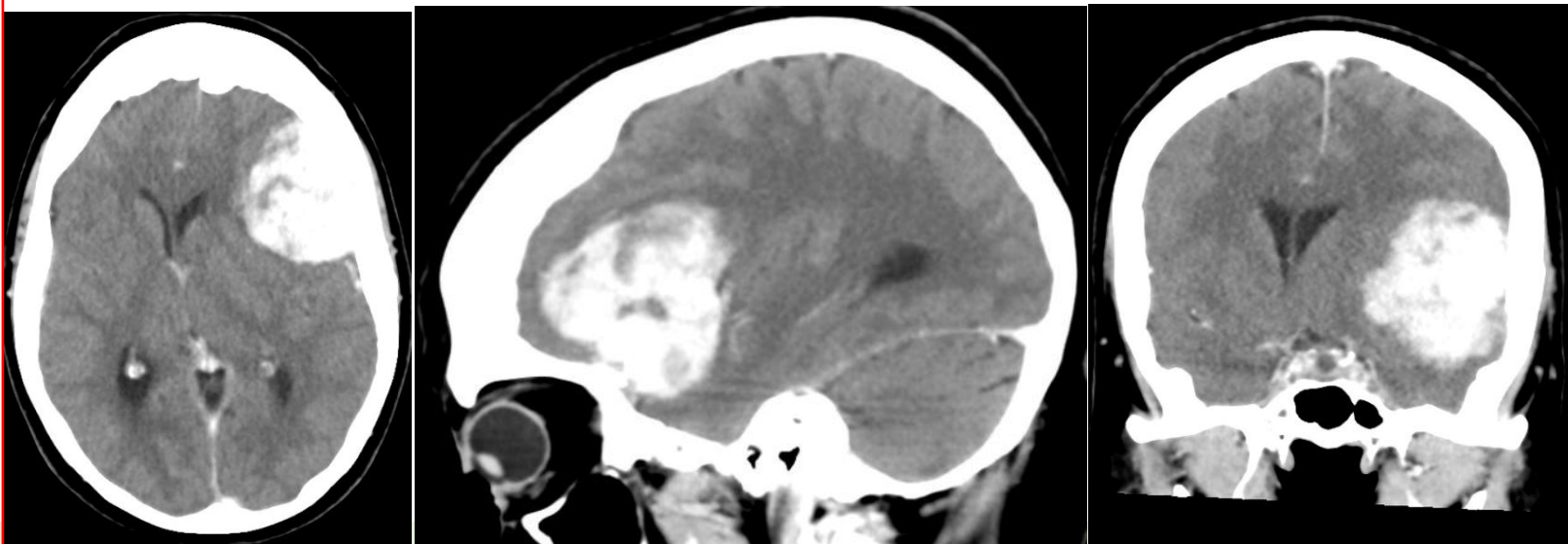
Perhatikan **MLS** (midline shift)



# Meningioma

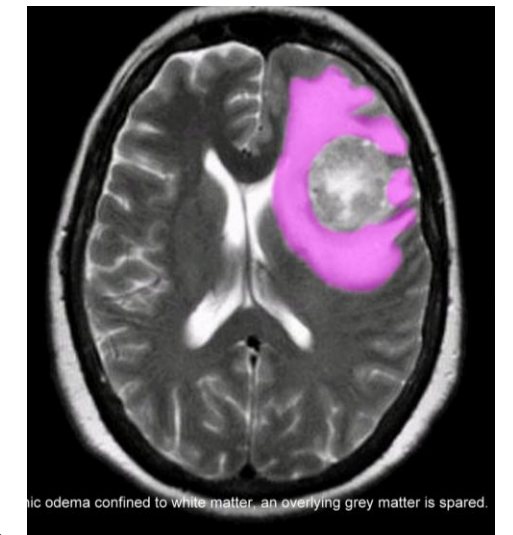
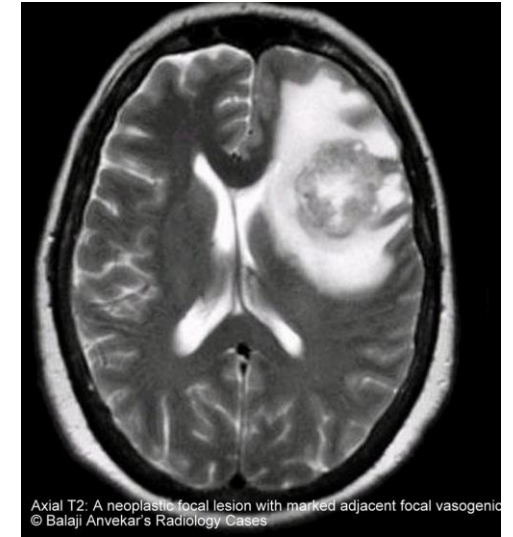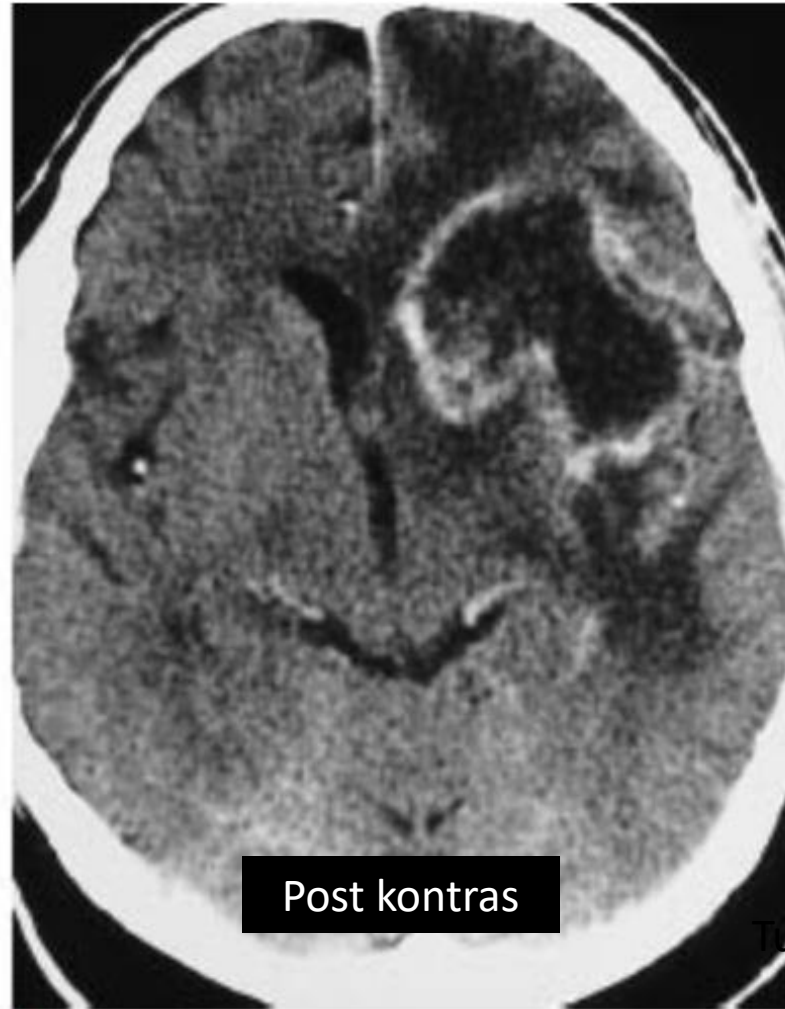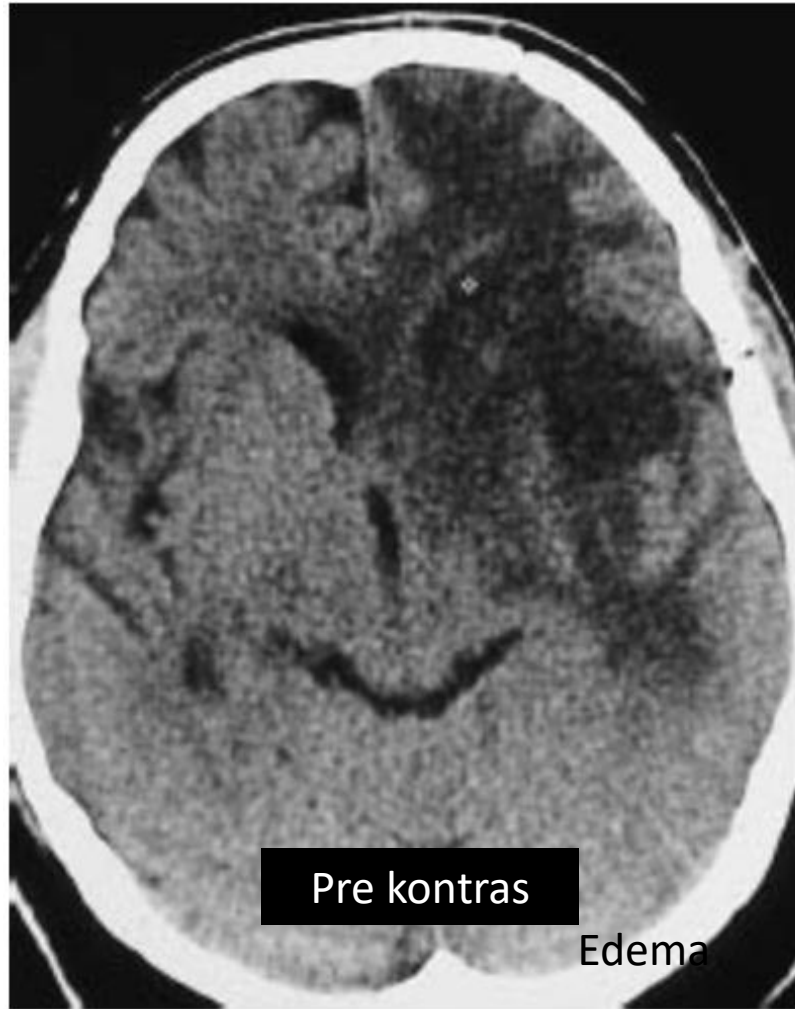


Pre Contrast

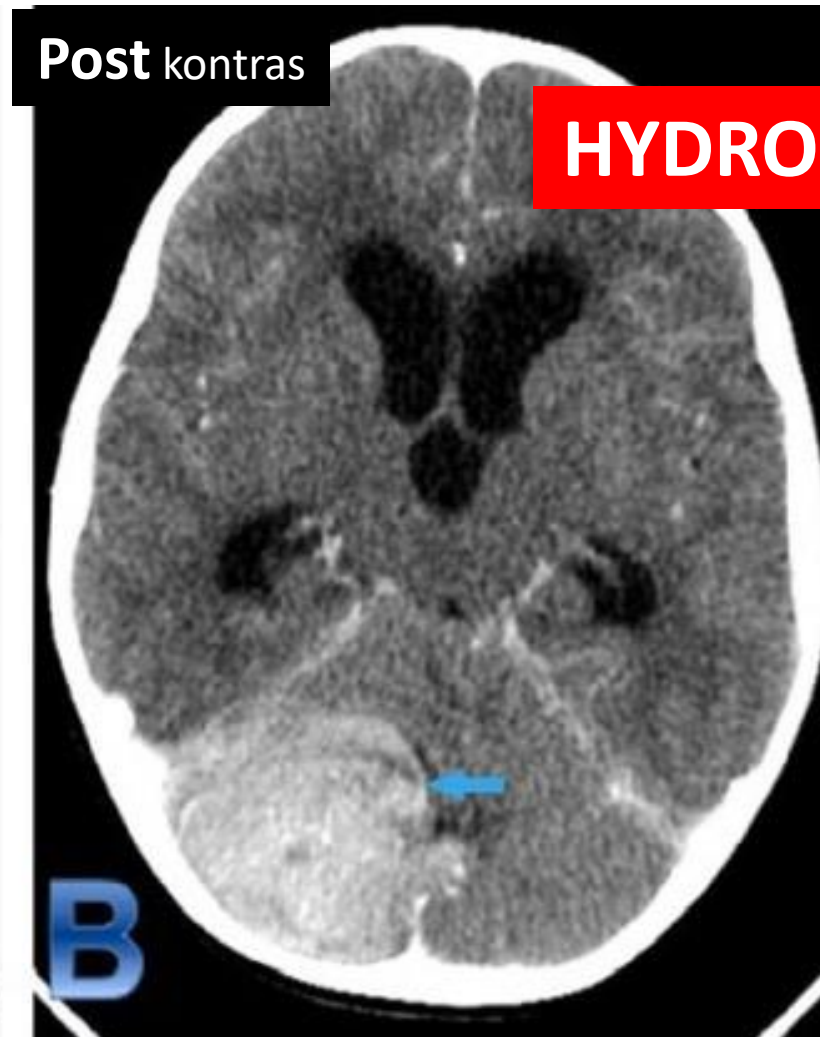
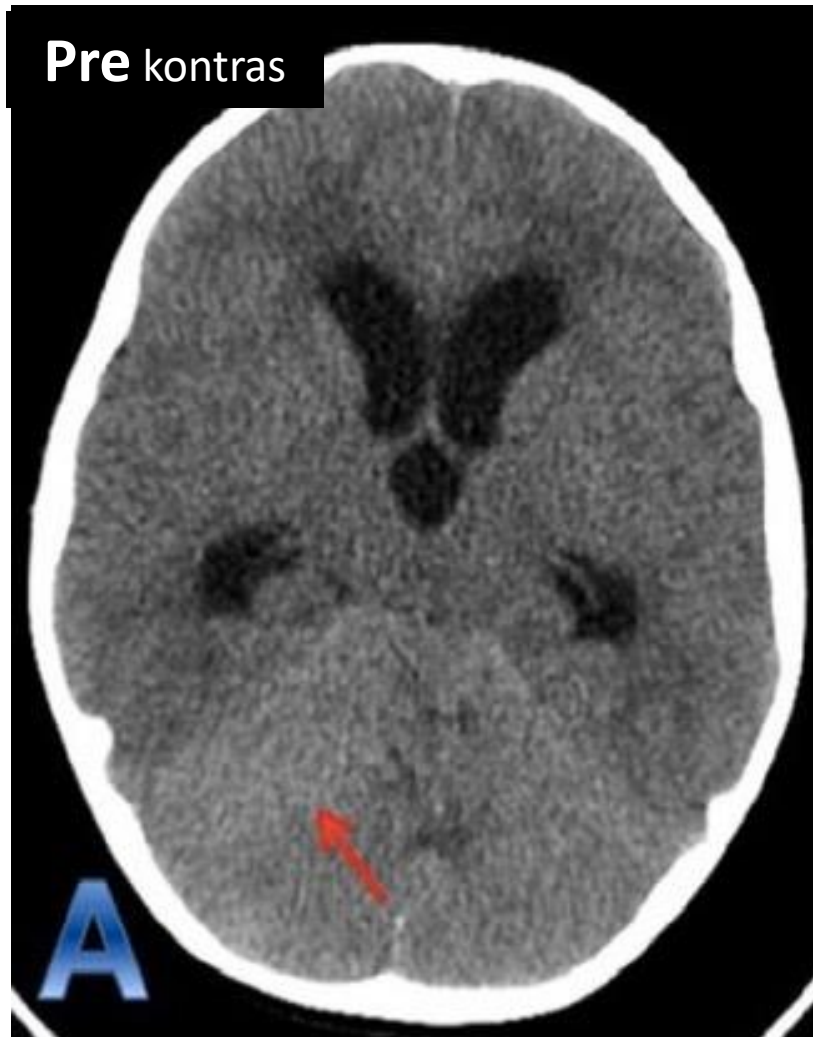

Post Contrast

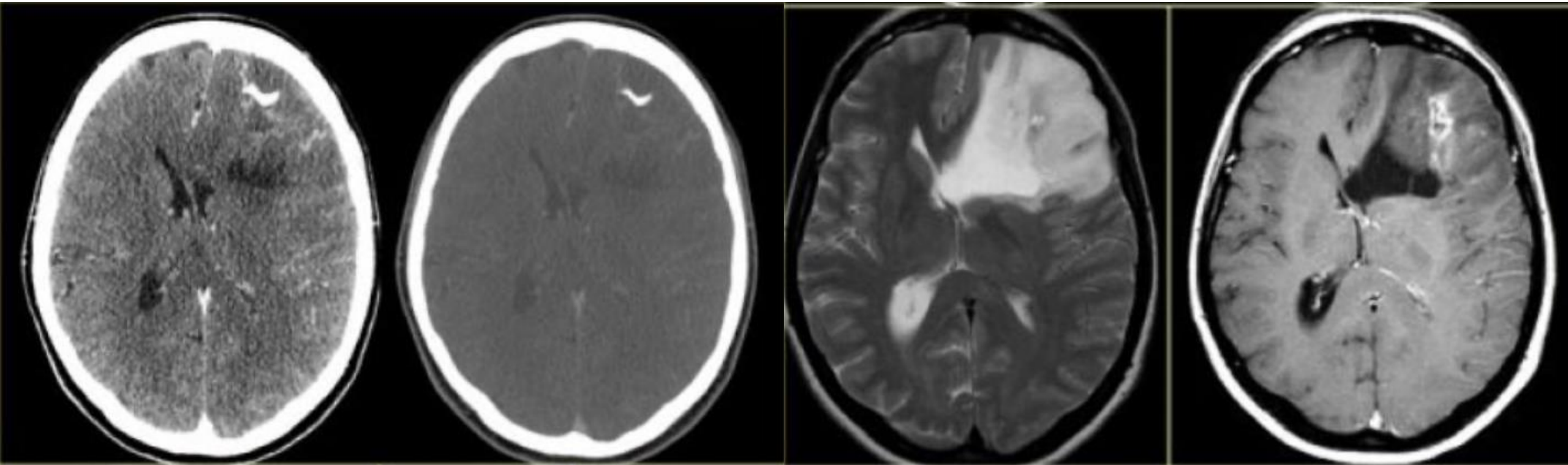
# Tumor Otak Intra-aksial → GLIOMA



# CT Scan TUMOR pada Fossa Posterior



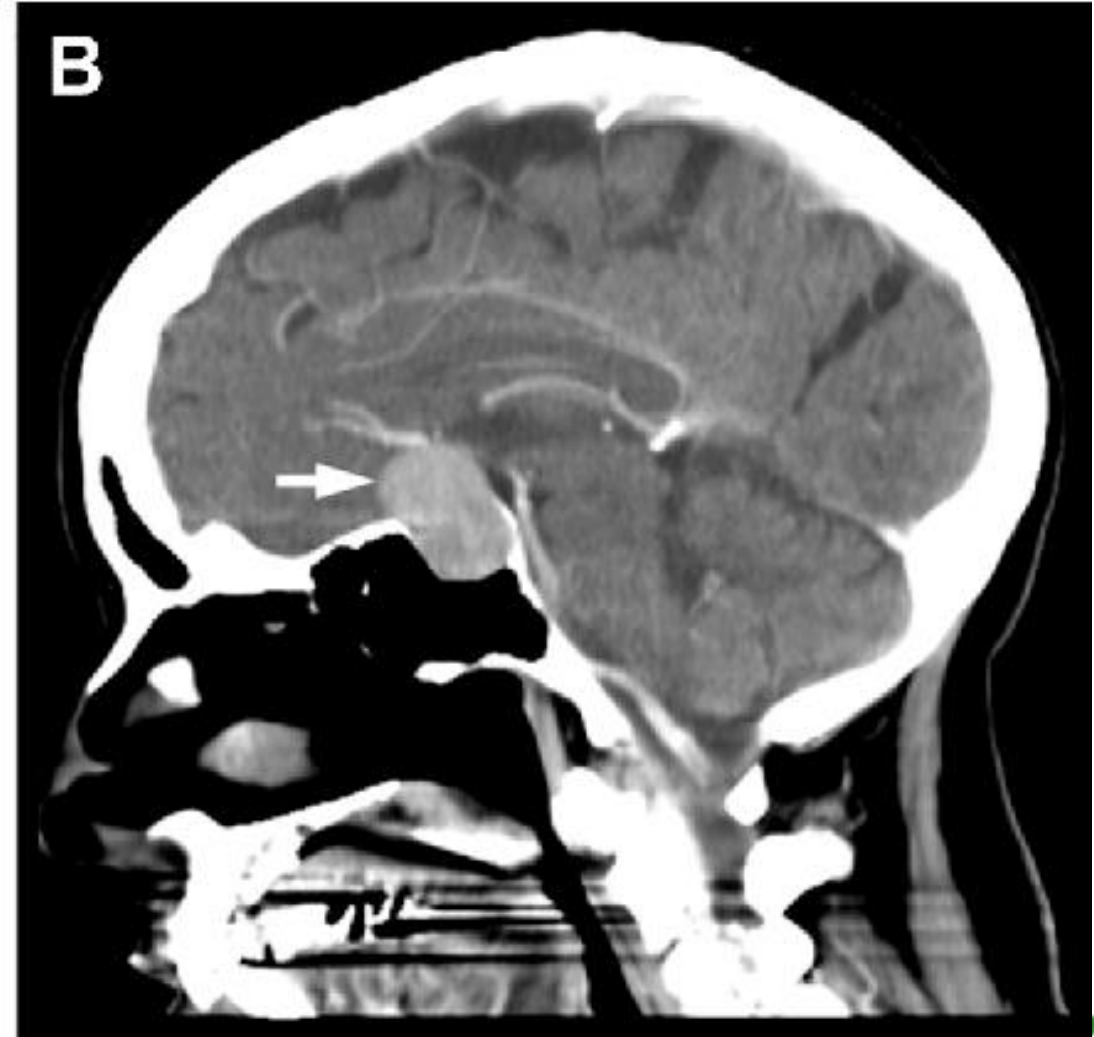
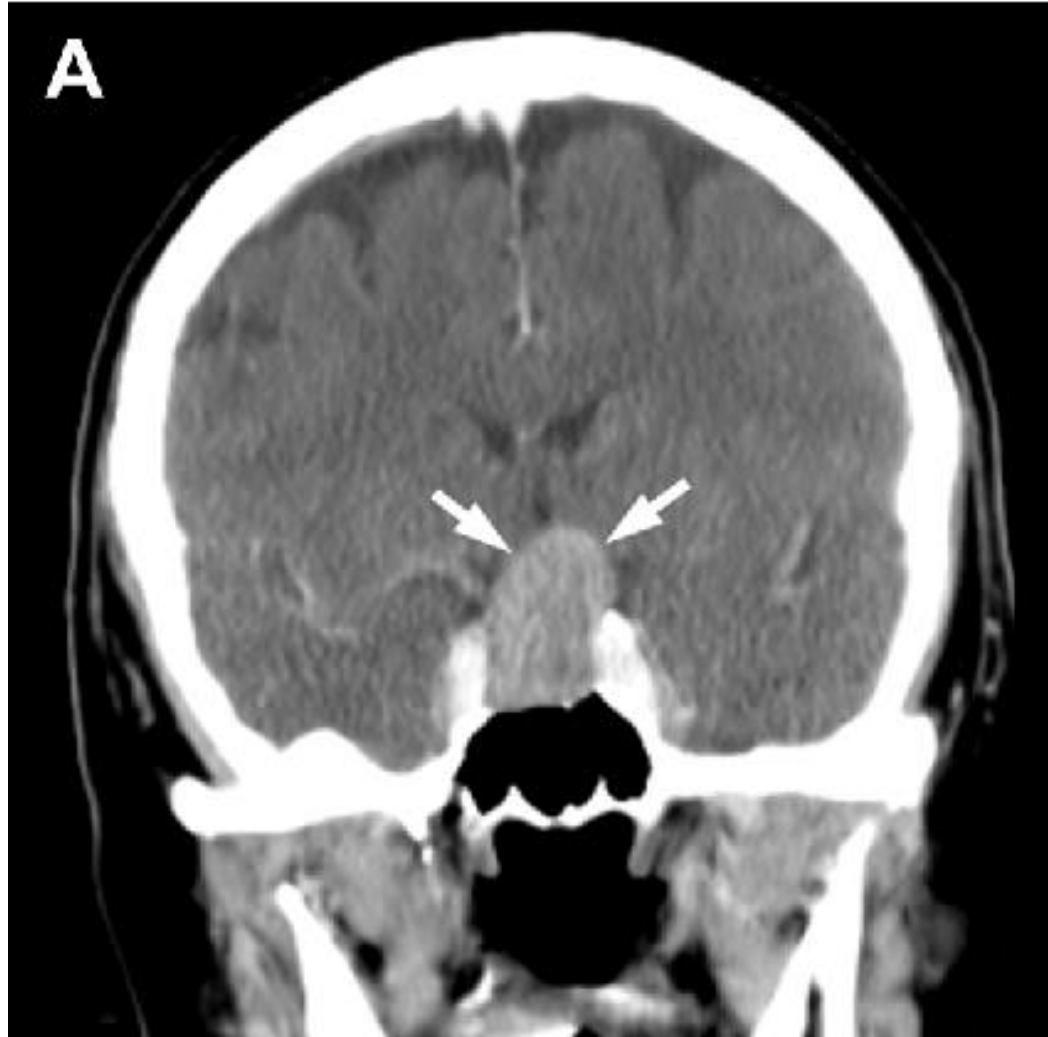
# CT Scan DAN MRI



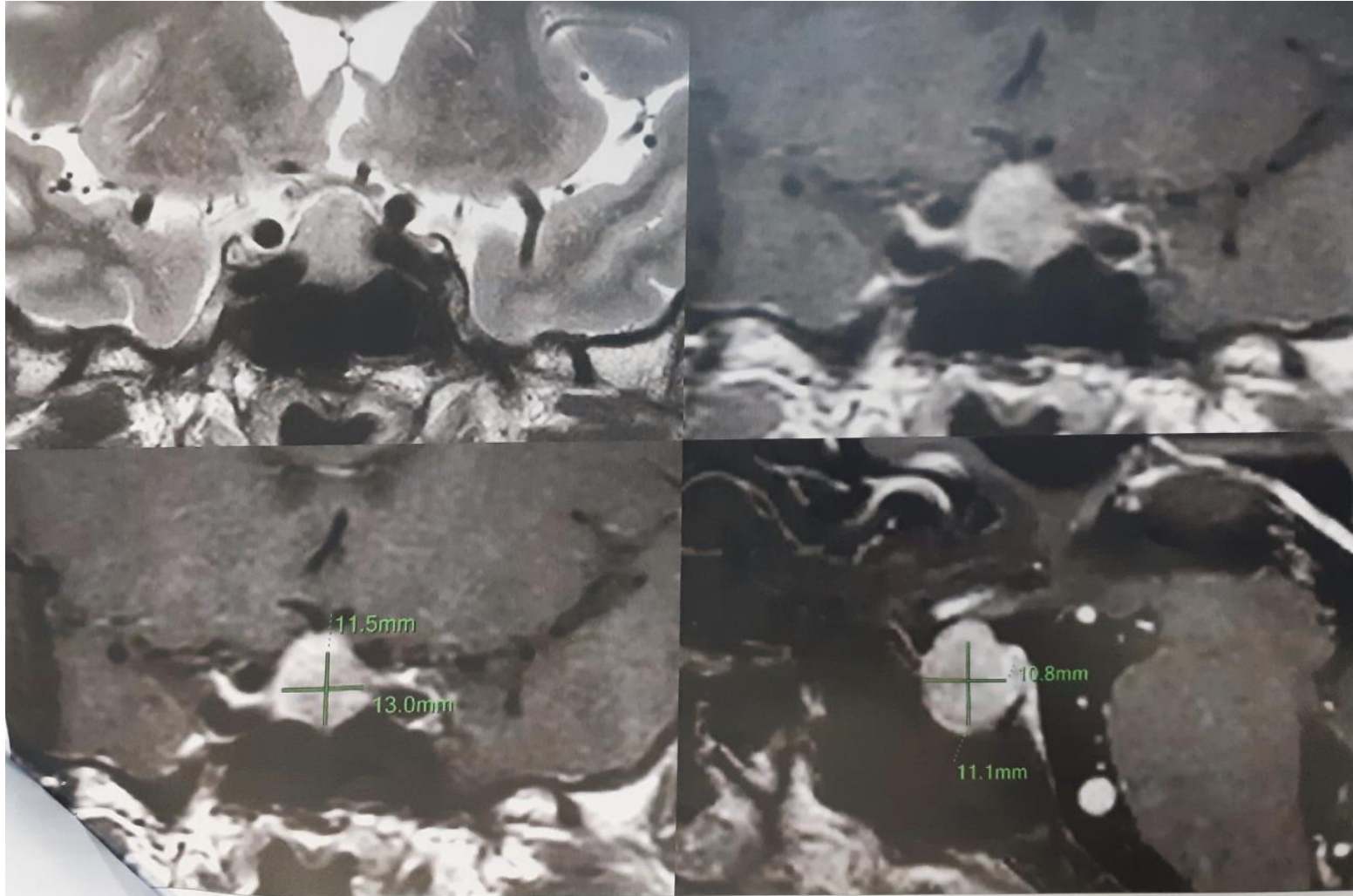
KALSIFIKASI

EDEMA  
PERITUMORAL

# Macroadenoma Hipofisis



# Macroadenoma Hipofisis



# Terima kasih